This is a digital copy of a book that was preserved for generations on library shelves before it was carefully scanned by Google as part of a project to make the world's books discoverable online.

It has survived long enough for the copyright to expire and the book to enter the public domain. A public domain book is one that was never subject to copyright or whose legal copyright term has expired. Whether a book is in the public domain may vary country to country. Public domain books are our gateways to the past, representing a wealth of history, culture and knowledge that's often difficult to discover.

Marks, notations and other marginalia present in the original volume will appear in this file - a reminder of this book's long journey from the publisher to a library and finally to you.

Usage guidelines

Google is proud to partner with libraries to digitize public domain materials and make them widely accessible. Public domain books belong to the public and we are merely their custodians. Nevertheless, this work is expensive, so in order to keep providing this resource, we have taken steps to prevent abuse by commercial parties, including placing technical restrictions on automated querying.

We also ask that you:

+ *Make non-commercial use of the files* We designed Google Book Search for use by individuals, and we request that you use these files for personal, non-commercial purposes.
+ *Refrain from automated querying* Do not send automated queries of any sort to Google's system: If you are conducting research on machine translation, optical character recognition or other areas where access to a large amount of text is helpful, please contact us. We encourage the use of public domain materials for these purposes and may be able to help.
+ *Maintain attribution* The Google "watermark" you see on each file is essential for informing people about this project and helping them find additional materials through Google Book Search. Please do not remove it.
+ *Keep it legal* Whatever your use, remember that you are responsible for ensuring that what you are doing is legal. Do not assume that just because we believe a book is in the public domain for users in the United States, that the work is also in the public domain for users in other countries. Whether a book is still in copyright varies from country to country, and we can't offer guidance on whether any specific use of any specific book is allowed. Please do not assume that a book's appearance in Google Book Search means it can be used in any manner anywhere in the world. Copyright infringement liability can be quite severe.

About Google Book Search

Google's mission is to organize the world's information and to make it universally accessible and useful. Google Book Search helps readers discover the world's books while helping authors and publishers reach new audiences. You can search through the full text of this book on the web at `http://books.google.com/`

LANE MEDICAL LIBRARY STANFORD
S51 .H43 1917 STOR
Modern dentistry / by Joseph Head with 3
24503363355

S51
H43
1917

LANE
MEDICAL LIBRARY
LEVI COOPER LANE FUND

S51
H43
1917

LANE
MEDICAL LIBRARY
LEVI COOPER LANE FUND

MODERN DENTISTRY

BY

JOSEPH HEAD, M. D., D. D. S.

Dentist to the Jefferson Hospital, Philadelphia

WITH 309 ILLUSTRATIONS

LANE LIBRARY

PHILADELPHIA AND LONDON

W. B. SAUNDERS COMPANY

1917

Copyright, 1917, by W. B. Saunders Company

LANE LIBRARY

PRINTED IN AMERICA

PRESS OF
W. B. SAUNDERS COMPANY
PHILADELPHIA

S51
H43
1917

PREFACE

DENTISTRY up to the last ten years made little or no advance along the lines of Health Conservation. For two thousand years dentistry has been devising collectors of filth and spreaders of general disease. The Roman, who strapped loose necrotic teeth to firm teeth with gold bands, defied the laws of health and cleanliness no more than many of our bridge workers of the present day. The dentist of the seventh century, in putting in gold fillings, to all intents and purposes used the same method as that of the soft-gold worker of the twentieth century.

Dentistry, owing to the teachings of Pasteur, has at last awakened to its great responsibility. Henceforth no appliance, however beautiful externally, will be tolerated unless it can be kept absolutely clean, and no repair of a tooth or root will be countenanced unless it conforms to the standards of scientific mouth hygiene. Fillings, crowns, and bridges are no longer to be considered mere objects of art for personal adornment or mechanical trituration of food, they must primarily be hygienic.

Through the elimination of mouth infection, and of much consequent systemic disease, dentistry must take a place in the foremost ranks of preventive medicine. Dentists henceforth must be trained along medical lines, and any contention that has existed in the past between the physician and dentist must disappear in a common endeavor to free the community at large from the deadly effects of mouth infection. For this disease is now recognized as an almost universal one that every year kills its victims directly or indirectly by the hundreds of thousands, and it is the author's hope that this book will be of some service in its cure and prevention.

46373

The author wishes to express his thanks to Dr. Wm. H. Hoedt for his valuable co-operation in illustrating this work, and he wishes further to acknowledge his obligation to Dr. A. P. Hitchens and Dr. Claude P. Brown for their bacteriological specimens and their friendly assistance.

JOSEPH HEAD.

PHILADELPHIA, PA.,
November, 1917.

CONTENTS

CHAPTER I

PAGE

Causes and Effects of Mouth Infection 17

CHAPTER II

Prevention of Mouth Infection 26
- Mouth Cleansing 26
- Method of Using Floss-silk 31
- Method of Brushing the Teeth 34

CHAPTER III

A Study of Tooth Enamel and Saliva 43
- Enamel Softening and Hardening 43
- Force Required in Mastication 54
- Dentifrices and Mouth-washes 56
- Destructive Action of Dentifrices 60

CHAPTER IV

Treatment of Mouth Infection 65
- General Diagnosis 65
- Violet-ray Treatment 74
- Local Treatment 75
- Tartar Solvent 80

CHAPTER V

Vaccines in Treatment of Mouth Infection 85
- Theory of Vaccination 85
- Anaphylaxis 88
- Preparation of Vaccines 90
- Autogenous and Stock Vaccines 91
- Obtaining Parent Germs for Vaccine 93
- Sensitized Vaccine 98
- Dosage 100
- Vaccines and Osteoarthritis 101

CHAPTER VI

PAGE

Treatment of Root Canals 104
Alveolar Abscess 104
Local Anesthesia 105
Gum Infiltration 109
Nerve-blocking 109
Pressure Anesthesia 112
Removal of Dental Pulp 115
Tooth Nutrition by Peridental Membrane 116
Root Canal Preparation 117
Sterilization and Root Canal Filling 119
Calahan Method 121
Emetin 123
Canal Variations 123
Bleaching 128
Root Amputation and *x*-Ray Diagnosis 132
Root Excision 135

CHAPTER VII

Fillings 142
Operative Efficiency 142
Old Hammered Filling 143
Porcelain Inlays 146
Porcelain Strength 147
Porcelain Inlay Matrix 153
Construction of Porcelain Inlay 154
Color Selection 162
Making and Baking the Filling 166
Inserting the Inlay 168
Gold Inlay 171
Plastic Fillings 176
Amalgam 177
Repair of Broken Roots 180
Gutta-percha Fillings 184

CHAPTER VIII

Children's Teeth 188
Gum Lancing 187
Care of Children's Teeth and Gums 189
Exposed Pulp in Temporary Teeth 195
Fractured Teeth 196
Orthodontia for the General Practitioner of Dentistry 199
Excision of the Frenum 231
Impaction of Teeth 234
Malnutrition 244

CHAPTER IX

PAGE

Crowns 250
Pin Crown 252
Amalgam Crown with Porcelain Facing 259
Inlay Crowns 260
Band Crown 264

CHAPTER X

Replacing of Lost Teeth 274
The Attached Bridge 274
Removable Appliances 282
Divergent Abutments 284
Double Clasp Bridge 290
All-Gold and Porcelain Fixture 295

CHAPTER XI

Experiments Concerning Strength, Solubility, and Adhesiveness of Various Cements 299
Silicious Cements 299
Phosphate of Zinc Cements 301
Tests on Cement Line 302
Adhesion of Cement 312
Cement as Inlay Bond 319
Solubility of Cement Line 319

CHAPTER XII

Study of Roots and Gums by Means of *x*-Ray 327
Interpretation of Plates 329

Index 369

MODERN DENTISTRY

CHAPTER I

CAUSES AND EFFECTS OF MOUTH INFECTION

THE term *mouth infection* means a condition where disease-bearing germs have established themselves within the tissues of the mouth, the vital resisting force of these tissues having been temporarily or permanently lowered by systemic disease or some depressing local condition.

Mouth infection is generally associated with red, swollen gums, with or without the presence of exuding pus, and teeth sensitive to heat, cold, or pressure. In ninety-nine cases out of a hundred the teeth and the gums are the primary seat of the disease, but occasionally it is confined to the cheeks, palate, or lips in the form of superficial self-healing ulcers, syphilitic sores, or slowly progressive areas of inflammation that sooner or later mean cancer. Any persistent fissure or inflammatory hardening of the cheek or lips has so long been known to threaten prolonged sickness and death that the incipient malignant forms of mouth infection generally receive prompt attention and treatment. All abnormal growths in the mouth may be malignant, and on their first appearance should be cut out for examination and diagnosis.

This book, however, will deal with infections of the gums and teeth, infections that have been complacently endured in chronic form ever since man came upon this globe. For just as the ticks and fleas of India can convey the death-dealing plague from one person to another, so these patiently borne gum and tooth infections are now known to originate a long list of fatal diseases,

among which are found valvular heart disease, anemia, arthritis deformans, rheumatism, and nervous derangements without end.

No doubt the first of the cave-dwellers who strove to free himself from vermin was called a finicky dandy. No doubt he was warned by the old men of the tribe that he was endangering his health and even life, and that if he made his body unaccustomed to vermin, when he did become infested, the tissues would have lost their defensive power against them. In the same way we have modern cave-men among us who sneer at excessive mouth cleansing as an absurd fad, some even claiming that there are germs in the mouth that have a benign influence for health. In answer to these cave-men, whose real reason is laziness, not science, it must be pointed out that a germ, like a man, cannot escape being judged by the company it keeps, and that when the machine-guns are leveled against a mob the innocent passer-by performs a patriotic duty in accepting death that the streets may be cleared and law and order restored.

Therefore, in spite of the fact that some of the numerous germs that lurk within the mouth may have beneficial possibilities, this vague chance must give way before the certain knowledge that the germs of pneumonia, influenza, diphtheria, and catarrh, with a host of other disease-forming germs, are practically always present in every mouth. These germs in a healthy mouth may be harmless, but the moment they succeed in obtaining entrance to an area of weakened or inflamed tissue they shortly become forerunners of their respective diseases, both local and systemic. Healthy blood, in conjunction with healthy tissue-cells, is fully capable of restraining the growth of a limited number of disease germs. Even the dreaded tubercle bacillus can be controlled and destroyed by healthy tissues if the germs appear only in very limited numbers. Therefore, it is of the utmost importance that the blood and the tissues shall be kept at their normal power to control these germs that are ever-present in the mouth; and if these germs do gain an entrance to the tissues, to destroy them before they can multiply sufficiently to cause disease.

General Causes of Mouth Infection.—With such a picture of bacterial invasion before our eyes, we are confronted with a problem that for centuries interested the philosophers as to which comes first, the egg or the fowl. That there are two causes of bacterial invasion—the systemic and the local—is unquestionable, but in any particular case it is usually difficult to say whether the original multiplication of an infecting bacterium first arose from deficient bactericidal power of the blood, or whether a local bruising or infiltration of the tissues reduced their defensive power against the germs to a degree where even healthy blood might not be able to resist the bacterial growth and consequent onset. However this may be, there is no doubt that progressive weakness in either systemic or local resistance will infallibly result in a final depression that is characteristic of both.

For instance, the constant drinking of water or beer containing lead will cause a systemic depression that, in addition to a palsy of the wrists and intestinal derangement, also causes the blue line of gum infection around the teeth that is diagnostic of chronic lead-poisoning. In the same way the constant use of calomel as an internal medicine will cause such a destructive inflammation of the gums around the teeth that the latter will loosen and even drop out. In each instance the primary cause of the bacterial invasion of the gums is systemic, and the ever-present micro-organisms first obtain their lodgment in a mass sufficient to defy the contending tissue-cells solely because of a general depression of the body at large. If, however, after the abscesses around the teeth are fully established in an area of dead and dying tissue, the lead or calomel is stopped and that which has been taken is eliminated by the intestines and kidneys, the abscesses around the teeth may nevertheless continue because the tissue-cells around them lack their original germicidal power. And even if the blood generally should regain its normal germicidal power, it would be unable to effectively reach and combat the invading masses of infection that are now securely fortified behind the dead or weakened tissue-cells; and the invading germs will continue to feed, and just as surely advance their

devastations wherever the tissue-cells show further weakened resistance.

As an illustration of a purely local source of mouth infection, let us take, for example, a tooth that starts to decay through the impaction of food in an improperly developed fissure of the enamel. The food ferments and acid is formed that dissolves and softens the tooth substance so that bacteria can penetrate along the dentin filaments to the nerve, or pulp, as it is called. The blood in the pulp throws out a protecting layer of tooth bone between it and the infection. Finally, the pulp loses the power of producing immunizing substances with which it can combat the disease, and accepts the infecting germs, which it deposits in the gum around the tip of the root. An infected living pulp may cause abscesses that are self-perpetuating and that will infect the system at large. This will finally lower the body resistance, and so the infection that started in a purely local manner may end in general disease.

As above stated, the systemic cause of mouth infection may not only be tuberculosis, malaria, rheumatism, typhoid fever, or any of the major diseases common to man, but it may be merely a bad cold or a passing attack of grip, which by lowering the vital resistance will allow the self-perpetuating abscesses of mouth infection to be formed. And it is equally true that a mouth infection caused by a badly fitting crown or a filth-collecting bridge may be the primary cause of systemic depression that will allow the body to become a prey to any of the systemic diseases or infections just mentioned, when without such local infections the body might have had sufficient vital resistance to repulse the onset of systemic disease and maintain a normal condition of health.

The obvious cure for mouth infection of a purely systemic origin is the removal of the cause of the systemic depression, but as this deals with practically the whole realm of general medicine this phase will not be discussed here. The obvious cure for mouth infections of local origin is also the complete removal of the cause, and with that thought in our minds the various local causes of mouth infection will now be considered.

Local Causes of Mouth Infection.—The most fruitful local causes of mouth infection are improper mastication of food and inefficient daily cleansing of the mouth. Nine-tenths, if not ninety-nine-hundredths of the local mouth infections can be traced fundamentally to these two great causes. All the other causes follow after these almost as a matter of course, such as decay of the teeth, and infection and death of the dental pulps or "nerves." Next follows impaction of food between the teeth, with the consequent destruction of the gum that protects the roots. The bone between the teeth, being exposed, becomes infected and absorbed, leaving a hole or pocket that cannot be properly cleansed; and this pocket, therefore, becomes a permanent and ever-spreading focus of disease, so that the membrane supporting what may be a perfectly healthy tooth gradually breaks down more and more, until the nerve trunk and blood-vessels at the root tips become infected and finally destroyed. This causes the death of the pulp in a tooth that may not show external signs of decay. Thus another depot of infection is formed that can only be eliminated by boring into the tooth, removing the pulp, and sterilizing and filling the root canals.

The fact that a tooth without decay, containing a live pulp, or nerve, may be a source of infection makes the diagnosis of whether there is mouth infection a matter of great nicety. This matter of diagnosis will be minutely discussed later on, but its difficulty makes the discovery of masked mouth infection by the general practitioner a matter of great uncertainty or even impossibility unless the physician has had the necessary diagnostic instruction in this most important subject. Only too often do physicians make careful general systemic examinations, but take merely a casual look at the teeth and gravely pronounce, "no mouth infection." Tuberculosis of the lungs is easily recognized in its advanced stages, but it is cured in exact ratio to its early diagnosis, and the spread of systemic disease by mouth infection is in the same manner prevented by its early recognition. As a matter of fact, the general practitioner only recognizes mouth infection in its advanced stage, when many of its systemic sequelæ are already firmly intrenched.

The packing of food between the teeth, whether there is decay or not, should always be considered a forerunner of mouth infection with the probable consequent loss of the teeth. The packing of food between the teeth, as above stated, is not always associated with decay, but may be due to a gum infection alone which weakens the supporting membrane about the teeth. These teeth spring apart under the force of mastication with resultant bruising of the gum and ultimate pockets of infection. We also have pockets of infection between the teeth that owe their origin to the projecting edges of fillings and ill-fitting crowns that during mastication constantly drive the infection into the helpless gum. Furthermore, infection is caused by uncleansable bridges, frequently inserted over gums already infected, and by plates that are made primarily to aid mastication, while in only too many instances they hasten the destruction of the teeth that they are designed to supplement.

These facts are so obvious that a glance in the average mouth will show instances of such infection again and again. And it is not as though such crowns and bridges were considered antiquated. They are approved and recommended in the every-day curriculum of many of our leading dental colleges by faculties that complacently look on their work as largely a question of mechanics, while their mechanical teachings and methods continue to spread infection and disease.

Dentistry is rapidly coming to be one of the foremost branches of preventive medicine, and in a short while no dentist will be allowed to practice unless he also has general medical training. Those who do not recognize this vital fact and continue to practice methods that create and perpetuate mouth infection will soon be relegated to oblivion, while a new and more scientific class of men will take their places.

Many interesting experiments have been made with the Streptococcus viridans, a germ which is frequently found in the pockets of mouth infection. Injected into the ear of a rabbit whose heart had been artificially strained, the Streptococcus viridans, upon autopsy, has been recovered from the inflamed valves of the heart. A macroscopic study of such animal postmortem

heart specimens has sometimes shown a calcareous deposit that is not dissimilar to the inflammatory calcareous deposits found on the roots of teeth. This is particularly interesting as there is unquestionably a relation between tooth tartar and general systemic depression due to mouth infection, the mouth tartar decreasing perceptibly as the immunizing bodies of the blood become more and more in control of the situation.

Effects of Mouth Infection.—The following case is an interesting example of secondary infection from a pyorrhea pocket: A young physician declared that he believed the condition of his teeth was causing a swelling of his tonsil. A casual look in the mouth gave the impression of gums that were perfectly healthy, but an exploration between the upper second and third molars revealed a pocket that almost exposed the tips of the adjacent roots of both teeth. An application was made of ammonium bifluorid. The patient returned in a week and the tonsil that had been greatly swollen had practically returned to its normal size. And from then on during the treatment it was clearly demonstrated that as the pocket showed signs of reinfection the tonsil would swell, and that when the pocket finally yielded to medication the tonsil returned to its normal state. This case shows an intimate relation between the tonsils and gum infection, apparently indicating that where they exist in common all the disease previously attributed to the tonsils alone may equally as well be attributed to gum infection.

Another case was that of chronic infection of the internal ear. The physician was unable to find any local cause, and suggested that the trouble arose from reflex dental infection. The removal of an infected living pulp in the upper second molar caused the ear to clear up immediately.

A patient had a chronic abscess in an upper molar that was associated with pronounced swelling of the submaxillary salivary gland on the same side. When the infection in the upper jaw was treated the gland in the lower jaw returned to its normal size; but when the infection returned, as it did several times because the patient would not take his treatments with proper regularity, the submaxillary gland would invariably become

swollen again. When the tooth became cured of its infection, the gland regained its normal condition permanently.

These cases are presented to show the intimate connection between the gums and tonsils, the gums and the ear, and the gums and the salivary glands. A more extraordinary case was one where the infection of a lower second molar caused a partial loss of sight in the eye on the same side of the face. In the course of examining the teeth of a young woman the author noticed a submaxillary swelling. This was traced to the second molar, which, on being opened, revealed an infected pulp. This pulp was removed and the tooth treated antiseptically for a series of treatments, during which the submaxillary gland decreased in size as the antiseptics were applied. After the first treatment the patient said that her sight was much improved. Later on, with each treatment, she spoke of the continued improvement of her eye, and finally, when the tooth was cured, she said as she left, "I had to give up my art studies on account of that eye, but I am now going to return to them." Later she went to her oculist, who six months before had found her sight in that eye more than half gone, and he corroborated her statements by an examination, and found that the chronic inflammation had entirely disappeared.

There are other cases where the connection between mouth infection and general arthritic conditions is clearly established by the fact that when the mouth infection was remedied the general diseases either cleared up or were greatly improved.

This chapter will close with a most interesting case of spinal irritation connected with mouth infection. A young married woman, thirty years of age, came to the author for treatment. About five years previously she had had an automobile accident by which the base of her spine had been so injured that it was impossible for her to remain in a sitting posture for more than half an hour at a time. Two or three of her teeth showed so marked a sensibility to heat and cold that the pulps, or nerves, had to be removed. The teeth also showed irritation at the root tips characteristic of spinal irritation, which made it practically impossible to fill the nerve canals. Any such attempt

was accompanied by such pain and signs of suppuration that no progress of any sort was made for over a month. Finally, a sterilized piano-wire drill was passed down a sterilized root canal and plunged into the sensitive area at the root tip; a material was obtained which yielded only a single type of streptococcus. From this an autogenous vaccine was made and the patient was treated with the vaccine about eight times, once each week. After the fourth treatment it was quite possible to fill the canals of all the teeth where the nerves had been removed. After the eighth treatment she was able to sit up, and since that time has had no further trouble with her spine. Evidently the infection of the teeth and the infection of the spine came from the same germ, and the systemic cure of the gums at the same time cured the spine.

Medical literature is full of startling cases where the intimate interdependence of mouth infection and grave general systemic disease is clearly indicated, but these just mentioned are of interest as they have come under the author's personal experience.

However, this chapter cannot be brought to a close without emphasizing the fact that leukoplakia (a white semi-malignant growth), tuberculous abscesses, Vincent's angina, a rapidly progressive infection, and cancer of the mouth are all so closely associated with a history of tooth and gum infection as to make it a matter for serious consideration whether any of these dreaded diseases may not be a direct result of the ordinarily neglected every-day diseases of the teeth and gums.

The normal age of man is now the biblical threescore and ten, but when the simple rules for preventing mouth infection are generally known and enforced as a matter of public policy, one cannot foretell how much human life will be extended, but that it will be greatly extended there is every reason to believe.

CHAPTER II

PREVENTION OF MOUTH INFECTION

Mouth Cleansing.—The most important treatment in the prevention of mouth infection is the mechanical removal of the masses of disease germs from the teeth and gums. After this has been done a mild antiseptic wash, such as a 1 per cent. solution of peroxid of hydrogen, held in the mouth for a minute or two, will be able to inhibit the growth of the remaining bacterial film until it is time to cleanse the mouth mechanically again. For germs of disease are dangerous not only as germs, but they are dangerous in direct proportion to their number and the length of time they are permitted to make their attack on the tissues. The immunizing bodies of normal blood can readily resist a few germs of disease for an indefinite time, but when the undisturbed germs are allowed to grow indefinitely the resistance of the tissue-cells is overthrown through a continued, ever-increasing efficiency of attack. Therefore it is evident that the fundamental remedy is to keep the ever-present disease germs reduced to a film so thin that the resistance of the blood in the gums will always be able to cope with any depressing influence that such a small bacterial mass can develop. It is also essential to keep the bacterial masses on the teeth so thin that they cannot secrete enough acid to effect a softening of the enamel through which the germs may find an entrance into the interior of the tooth substance.

The three acknowledged means of removing and inhibiting the growth of the bacterial masses are: (1) the floss-silk; (2) the tooth-brush; (3) the mild antiseptic wash. The scientific use of the floss-silk is absolutely essential in the daily cleansing of the mouth, and yet the reasons underlying its scientific use are not generally understood. It is, of course, useful in removing

particles of food that may act as culture-media for the growth of disease germs, but the greatest function of floss-silk is to remove the mass of germs themselves that would otherwise day by day, week by week, and month by month steadily collect between the teeth. There is no other means than the floss-silk for effectively removing these masses from between the teeth.

Dentistry has recommended pitifully inadequate movements of the tooth-brush for cleansing between the teeth, when a single glance in the mouth immediately after the teeth have received such a brushing will show that the tooth-brush does not and cannot cleanse between the teeth. In teaching such misleading methods of tooth cleansing dentistry has been perpetuating the very conditions it professes to obviate. As before stated, the only instrument capable of cleansing the spaces between teeth is floss-silk, and this should be swept over each approximating surface of the teeth at least once a day. This will break up and remove the bacterial masses thatwould otherwise collect and remain year in and year out. It is because the tooth-brush erroneously is supposed to remove such bacterial deposits that tooth decay nine times out of ten starts between the teeth; and almost invariably pyorrhea alveolaris (Riggs' disease) or gum infection starts between the teeth as soon as the gum has receded sufficiently to make an interdental space. Because floss-silk is not properly used, and the masses of bacteria remain undisturbed, mouth infection starts between the ages of five and ten, and eventually reveals at the age of forty or fifty its insidious toll of general disease. Almost all, if not entirely all, of these dreadful sequelæ can be avoided if at the age of five the child is taught the use of floss-silk, and is taught to cleanse between the teeth not for the sake of being clean, but for the sake of growing up strong and healthy. No child wishes to take the trouble to be clean, but every child wishes to grow up strong and well. Every normal child will labor and strive to improve his body for the sake of athletics, and if he knows that the use of floss-silk is just as necessary as arduous exercise, there is no question but that floss-silk will be used, and used effectively.

Let us now consider the use of the tooth-brush as a means of removing the bacterial masses from the exposed surfaces of the teeth and the gums. Just as those who never use floss-silk never cleanse between the teeth, so do the majority of those who brush the teeth never really cleanse them. The cleansing action of a tooth-brush can only lie in bristle friction, and most well-meaning people either use strokes of the brush that never get beyond a pivoting of the long bristles, or they use brushes so large that there is neither room to move them nor to effectively place them against the back teeth. With all the talk that there has been about tooth-brushing since Adam delved and Eve span, the wisdom-tooth has been as badly treated as the nearsighted child of fifty years ago who was relegated to the dunce cap because he could not see the letters of the book that he was blamed for not understanding. The wisdom-tooth enamel is in structure just as sound as that of any other tooth, and it has its bad name simply because it is never cleansed. Because the back molars are badly cleansed they are usually the first to become infected and loosen. The back molars are nearest to the tonsils and, being uncleansed, they are therefore particularly dangerous as spreaders of disease.

The great test of a tooth-brushing method is, does it cleanse where it is designed to cleanse? In plain words, the way to brush the teeth and gums is to *brush* them. Obviously, too large a brush is useless. To use a 2-inch brush with bristles ½-inch long, where there is only 2½ inches for free action, means that there will be practically no bristle friction, which is what occurs in most mouths during the process of brushing the teeth. In the mouth the free space in any given line where a tooth-brush can operate is seldom over 2½ inches. The usual brush, being about 2 inches long, generally reduces the possible movement of the brush to about ½ inch, and this ½ inch is entirely taken up by the spring and pivoting of the bristles, so that with any such attempt at brushing there is very little bristle friction at all. Therefore we should avoid the use of the ordinary large tooth-brush and use a narrow bristle brush not over 1½ inches long, with bristles not over ¼ inch in length. This will allow sufficient room for genuine

motion of the brush in the mouth; and if the bristles are too stiff at first, the brush should be placed in hot water for a minute before using, until the gums become accustomed to their action. Healthy gums can bear the same scrubbing as the flesh around the finger-nails, and with the same benefit. In fact, the exposed surfaces of unhealthy inflamed gums, when given a vigorous scrubbing with a stiff brush twice a day, in the course of a week or ten days will become firm and healthy; and no other single treatment, to the author's knowledge, will accomplish the same result. This generally unknown fact was utilized some years ago by a certain charlatan who was trying to sell his tooth-paste. He forced his way into the office and immediately began, "Doctor, this tooth-paste is most useful for the cure of the small canker sores that so often come on the cheek and gums. All you have to do is to put a little of this paste on the tooth-brush and brush it thoroughly into them." "But," I interposed, "won't the sores get well if they are brushed with the tooth-brush and water?" "Why, yes," he replied, with a sickly smile, "but that is not usually known."

The brushing of the gums, as before stated, is of prime importance, but the intense pain occasioned by the first week's work is as severe as the pains in the back of an athlete when he first starts to get himself into condition. The trainer tells the athlete to go on with his work and that it will be all right, and in the same way the poor patient, though he fears that he is injuring his gums when he uses the brush vigorously, must be encouraged by his dentist to continue, with the assurance that the pain in his gums will soon disappear. The author once showed a young lawyer how to brush his teeth and gums. He went away and the next day the author received a letter from him threatening suit for having ruined his face. Amusing as this incident is, it has a very serious bearing. The gums to be healthy must be scrubbed so as to remove the bacterial masses and also the dead epithelial scale, which will act as a bacterial food. Scrubbing infected gums cannot result at first in anything but further infection that may, and frequently does, cause a slight fever, however, the bacteria cannot be removed and the gums will not heal unless

this severe ordeal is endured. The systemic reactions caused at times by brushing infected gums must be explained as a process of auto-inoculation, for under no other supposition is it possible to explain why, under the newly inaugurated thorough brushing day by day, the gums should continue to be sore and inflamed, and then suddenly, between the seventh and tenth days, become healthy, hard, and firm, thereafter standing with complacency any amount of brushing.

In a minor degree the same phase is noted when the floss-silk is first used on infected gums. The gums at first naturally bleed

Fig. 1.—Proper method of holding dental floss.

and become further infected from the use of a string that drives in the infecting organism. This soreness has been used as an argument against the use of floss-silk, but it is not a just argument, as a few days' perseverance will invariably show. The persevering scientific use of floss-silk will always be followed by improvement, and, if the infection has not proceeded too far, by a complete disappearance of the infection between the teeth. If the patient was told that he must go through a week or ten days of discomfort to avoid gout, rheumatism, valvular heart

disease, or ulcer of the stomach, how readily and gladly would he do it, how cheap would he consider the price! But since he considers it a question of mere cleanliness, this ordeal is very naturally avoided and these diseases all become possibilities.

Method of Using Floss-silk.—Careful floss-silking is not the simple procedure it is supposed to be. Like tooth-brushing, there is only one way to do it properly and a hundred ways to do it improperly. The floss-silk must scrape the sticky bacterial masses from the sides of the teeth and the intervening gum. Many instruments have been devised to hold the silk, but none can equal the fingers themselves for doing this most important act. The proper method of using floss-silk is as follows: A generous piece of floss-silk should be taken and wrapped around both hands so that there will not be more than ½ inch of free silk

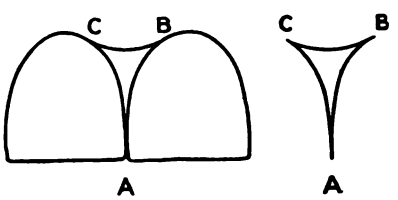

Fig. 2.—Triangle *A–B–C* shows correct lines dental floss should travel in cleansing each interdental space.

between the two hands (Fig. 1). The thumb and forefinger are used for cleansing the upper teeth, the two forefingers for cleansing the lower teeth. There should not be a greater length of free silk, for instead of cleaning the bacteria off the teeth too great a length of free silk will bend and pivot like the bristles of the brush that are too long. The tense span of silk should go with a sliding motion up one side of the interdental space, care being taken to include the curve of the tooth on that side, up well under the frenum of the gum, then roughly across the gum and up into the opposite frenum, and then down the rounded surface of the adjacent tooth. For instance, let *A* (Fig. 2) represent the junction of the two upper central incisors, *B* represent the frenum of the gum on one side, and *C* represent the frenum on the other side. The floss-silk must pass through the junction *A*, and

slipping and sliding across the rounded side of the tooth, with a drawing motion from *A* to *B*, must then scrape across the gum to the frenum *C*, into which it must be driven, and finally scrape down the rounded surface of the tooth from *C* to *A*. It travels the outline of a triangle (Fig. 2).

The mere passing of the thread through *A* in a straight line, as is the custom of most people who use floss-silk, is obviously ineffective, since the bacteria stick to the sides of the teeth and

Fig. 3.—Correct position of hands in flossing right half of upper dental arch. Note that the thumb of right hand is on the outside.

gums like films of glue and can only be removed by actual, vigorous scraping. The mere passage of the silk up and down through *A* is as useless and silly a performance as that of attempting to cleanse the bacterial masses from the teeth by merely rinsing them with a wash. A mouth-wash can no more remove the bacterial masses from the sides of the teeth than it could remove a coating of fresh varnish if such had been flowed on the dried teeth previous to the cleansing. This adhesive nature of the

bacteria must be recognized, or otherwise successful flossing of the teeth will be impossible.

In cleansing the teeth on the upper right side the thread should be stretched between the index-finger of the left hand and the thumb of the right hand. The thumb should be on the outside and the index-finger on the inside of the mouth (Fig. 3). The triangular motion should then be carried out between all the teeth all the way back to the farthest molar, care being taken to see that the thumb slips under the lip when the molars

Fig. 4.—Correct position of hands in flossing left half of upper dental arch. Note that the thumb of left hand is on the outside.

are reached. When this has been accurately done there will be no difficulty in reaching behind the wisdom tooth. There is no instrument yet devised that can hold the floss-silk as well as the fingers.

When we come to cleansing the interdental spaces on the upper left side the left thumb should be on the outside and the right index-finger should be on the inside (Fig. 4). The procedure for cleansing the spaces of the upper left side is the same as for the upper right side.

In cleansing the spaces of the lower right side the free silk must extend between the index-fingers, the right index-finger being on the outside for the lower right side (Fig. 5), and the left index-finger being on the outside of the teeth for the left lower side (Fig. 6). In other respects the same principle for cleansing the spaces is to be observed.

The Method of Brushing the Teeth.—As before stated, the tooth-brush should not be over 1½ inches long, the bristles not over ¼ inch long, and the handle long and large enough to afford

Fig. 5.—Position of hands in flossing right lower side of dental arch. Note that the index-finger of the right hand is on the outside.

a firm grip to the hand (Fig. 7, small brush; Fig. 8, large brush, which is obviously too large). The principal thing to be avoided is too great bristle length, since long bristles by increasing the pivoting arc of each bristle just so much reduce the bristle friction produced by the general movement of the brush. It is bristle friction alone that cleanses the teeth and gums during the process of brushing. Bristles ½ inch long can pivot ⅜ inch each way without bristle friction. If, therefore, there is a 1-inch stroke, the bristle friction stroke is only ¼ inch, and if, as fre-

quently happens, the tooth-brush stroke is only $\frac{3}{4}$ inch, there is no bristle friction stroke at all. The $\frac{1}{4}$-inch bristle, under the same conditions, would have a play each way of $\frac{3}{16}$ inch, which theoretically would cause only $\frac{3}{8}$ inch loss of bristle friction, but in reality it would be less, since the further the bristle extends from the back of the brush, the more readily it bends under pressure. But granting that there was $\frac{3}{8}$ inch loss in bristle friction to each stroke, this would still leave a real cleansing

Fig. 6.—Position of hands in flossing the left lower side of dental arch. Note that the index-finger of left hand is on the outside.

friction stroke of $\frac{5}{8}$ inch when the $1\frac{1}{2}$-inch brush was moved through a $2\frac{1}{2}$-inch space, the amount of space for tooth-brush motion usually found in the average adult mouth.

So much for the mechanics of tooth-brushing; now as to the actual motions as applied to the human mouth. There are three motions: First, the rotary motion, whereby all the gums and teeth anterior to the second molars are cleansed with a vigorous whirling action; second, the drawing motion, wherein the middle of the brush is placed behind the last molar and drawn vigorously

across the outside gum margins of the teeth; third, the drawing motion, wherein the brush is placed back of the last molar inside of the mouth and drawn sharply forward along the gum

Fig. 7.—Actual size of brush that can properly cleanse the teeth and gums.

margins and the teeth. In each stroke care should be used to follow the curve of the arch with the entire face of the brush.

Let us now discuss motion No. 1 in its minute details. The upper and lower front teeth should be placed edge on edge to

Fig. 8.—Actual size of brush ordinarily used.

avoid the lapping of the upper teeth over the lower. The brush should then be placed against the teeth and rubbed upward to the junction of the upper gum and lip, forward for a

distance of a full inch or more, downward to the lower gum and lip margin, and then back to the original position, as shown in Fig. 9. This should be done at least five or six times. The brush should then be placed between the cheek and teeth on the

Fig. 9.—Motion of brush for cleansing front teeth and gums.

left side. Here the same general motions should be carried out. The brush should be rubbed upward to the juncture of the cheek and gum, back to where the end of the brushing is stopped by the

Fig. 10.—Motion of brush for cleansing side teeth and gums.

overhanging curve of the lower jaw, down to the juncture of the cheek and lower gum, then back to the start, as in Fig. 10. This same motion should be repeated on the right side, and the three movements of motion No. 1 are finished. If after this motion has

been thoroughly performed the second and third molars, upper and lower, are examined, they will still be found covered with bacterial masses, and the reason for these undisturbed deposits is easily discovered. The curving side of the lower jaw lies so close to the upper teeth that no tooth-brush can effectively get at them while the jaws are closed, and in the same way the last two lower teeth are excluded from the action of the brush by the fact that they lie behind and within the curving angle of the lower jaw. When the jaws are closed there is not ⅛ inch room remaining for tooth-brush cleansing, but when the jaws are partly opened, the lower jaw swings back, leaving a space of a full ½

Fig. 11.—Position of brush preparatory to cleansing upper wisdom teeth. Dotted line shows direction in which the brush should be drawn.

inch in which the brush can thoroughly do its work behind the third molars. Therefore, as just intimated, in performing motion No. 2 for the upper teeth the mouth should be about half open and the lips and cheek held relaxed. The middle of the bristles of the 1½-inch brush should be placed at the back of the third molar and drawn briskly forward along the gum margins, care being taken to follow the curve of the gum with the entire face of the brush (Fig. 11). To place the brush behind the third molar the relaxed corner of the mouth should be stretched back by the back of the brush until the middle of the brush is directly back of the wisdom tooth. When this is done correctly the brush will be pointing directly at the wisdom tooth on the

other side of the arch. The middle of the brush should be placed behind the third molar, not thrust in place by the point, as by thrusting, the bristles will be so bent that the resulting pivoting of the bristles will cause the back of the upper third molar to get no bristle friction at all, and so the back of the third molars will not be cleansed. Motion No. 2 in its action on the lower molar teeth is exactly the same as with the upper, except that instead of placing the bristles on the back of the lower third molar, the bristles are directed downward on the gum back of the third molar, and then with a curving, downward sweep are brought sharply along the gum and cheek margins and the necks of the

Fig. 12.—Position of brush preparatory to cleansing back of lower wisdom teeth. Dotted line shows the proper downward sweep.

lower teeth (Fig. 12). This motion should be done on the upper and lower jaws, right and left, and not less than five or six times each.

Motion No. 3 is comparatively simple. The brush is placed on the gum and tooth line behind the third molars and drawn sharply forward and out of the mouth over the insides of the central incisors, care being taken to follow the curve of the arch with the entire face of the brush. The brush should be placed back of the last molars, not thrust back of them, as thrusting will cause a counterbending of the brush bristles and result in a pivoting that again will leave the back molars without bristle friction, and consequently dirty, (Fig. 13). Motion No. 3 should

be done five times on the upper and lower jaws, right and left, and when this has been properly done the surfaces of the teeth and gums will be free from bacterial masses.

After so much minute explanation it may not be inadvisable to review once more just what the daily cleansing of the mouth should be. The surfaces between the teeth should be thoroughly swept by floss-silk to remove all food and bacterial deposits. The teeth and gums should then be thoroughly brushed, as described, with dentifrice or antiseptic mouth-wash (see Chapter III), and the saliva and mouth-wash vigorously swashed in

Fig. 13.—Position of brush preparatory to cleansing inside of dental arches. The brush must extend well back of the back tooth and be drawn briskly forward along the edge of the gum and teeth, and finally out across the median line, as is shown by the dotted line.

between the teeth for a period of not less than two minutes, so that the thin coating of bacterial film left by the floss-silk on the sides of the teeth may be discouraged from growth until the next cleansing. Where there is marked gum infection a saturated solution of sodium silicofluorid or 1 per cent. peroxid solution should be held in the mouth for at least two minutes after the procedure just described. This cleansing should be carried out morning and evening. It must not be forgotten, however, that each mouth is a separate problem and must be treated as such. If teeth are missing, the brush must be inserted vigorously in the vacant spaces, and if certain abnormal rotations

Fig. 14.—Inflamed gums prior to using dental floss and tooth-brush properly.

Fig. 15.—Four days later. Note the improved color produced by cleansing alone. No mouth-wash or dentifrice was used.

Fig. 16.—Two weeks later. The gums have healed perfectly under the cleansing treatment.

are necessary the dentist must train the patient to see that these abnormalities are met and the parts are thoroughly cleansed by especially devised strokes of the brush.

Figure 14 represents a pronounced case of mouth infection. An examination revealed the fact that the infection was superficial in the gum and had not penetrated along the teeth so as to cause abscesses that were beyond the reach of the floss-silk and tooth-brush. A systemic examination proved the patient to be in good general health. The patient was accordingly told that if he would scrub his teeth and gums according to the author's directions, and also use floss-silk as described, he could cure himself without any other treatment or even antiseptics. The patient came back in four days and another photograph was taken (Fig. 15). Note the wonderful change in color,showing that the gums had become almost normal. He was told to keep up the floss-silking and gum-brushing, and not to use any dentifrice or mouth-wash. He came back in a week, and while his mouth showed considerable improvement, there was a large ulcer still present. The author told him that by this time he expected the mouth to be entirely well. He said, "I don't know what more I can do, doctor, for I brush my gums thoroughly three times a day." "Brush them once a day," was the reply, "and give the poor ulcer a chance to get well." In this instance the patient had been overstrenuous in carrying out instructions. He went away and in four days more returned, and the third picture (Fig. 16) is an illustration of how his mouth looked. When the author first saw the patient, two weeks before, his gums had the color of Fig. 14, and would bleed at the touch of floss-silk or a brush. Two weeks later, through proper cleansing alone, he could brush them as vigorously and as painlessly as he could brush his finger-nails. There was no bleeding, his mouth was healthy, and it not only looked clean, but it felt clean. Mouth antiseptics and dentifrices have unquestionable value at times, but for ordinary service their value is inconsiderable when compared to efficient cleansing.

In closing this chapter it might be wise to emphasize the fact that a brush softened in hot water is a valuable instrument with

which to commence to cleanse and harden infected gums. As the gums become hard and firm the patient will naturally be less careful about the use of hot water on the brush, and very soon the stiff bristles can be fearlessly used. This precaution is especially valuable in the preliminary training of children in their daily mouth hygiene.

CHAPTER III

A STUDY OF TOOTH ENAMEL AND SALIVA

DENTIFRICES AND MOUTH-WASHES IN THEIR RELATION TO MOUTH HYGIENE

Enamel Softening and Hardening.—Enamel softening has been considered to be necessarily associated with roughening of the surface, loss of luster, and dissolution of the substance that binds the enamel rods together; and whenever enamel decalcification is associated with decay of dentin this conception of enamel softening is accurate. But this conception takes into consideration only the final phase rather than the complete process of enamel degeneration.

Miller and many others in producing artificial decalcification by solvents, in employing aqueous solutions of acids varying in strength from ½ to 2 per cent., have exposed their tests to two serious objections: First, that the solutions found in the mouth are saliva solutions, not aqueous solutions; second, that any strength greater than 1 : 1000 of lactic acid or any similar acid would practically never be found in the mouth. Unquestionably, the acid set free from the bottom of a bacterial plaque adherent to the enamel may be acid of any strength, possibly chemically pure, or concentrated acid may be developed in a cavity where the opening into the mouth is small enough to prevent dilution with saliva. But in the enamel degeneration which is associated with general erosion, where the bacterial plaque is not an important factor, decalcification tests to be of value must be made with saliva solutions and with acid solutions as weak as those found in the human mouth; for saliva itself restrains the action of many acids on the teeth and modifies and changes the appearance of enamel decalcification.

For instance, 1 : 1000 solution of lactic acid and water, at mouth temperature, will cut tooth enamel in thirty minutes,

producing a rough, white surface. A 1 : 20,000 lactic acid aqueous solution will at the end of three or four days leave the tooth enamel unharmed to all appearances, and yet the outer surface of the enamel will be found with the edge of the lancet to have distinctly softened, a condition which is only found with a lactic acid and saliva solution as strong as 1 : 500, and such a solution has a decidedly acid taste and turns litmus brilliantly red. This shows that ordinary saliva has a decided protective power against acids. In fact, in a number of experiments with lactic acid and saliva, a 1 : 500 solution left the tooth enamel absolutely unharmed.

The action of aqueous solutions of acid calcium phosphate and acid sodium phosphate on the teeth has been mentioned by various observers, extraordinary stress being laid on the fact that these acid salts cause smooth white decalcification. As a matter of fact, many acids in aqueous solutions cause smooth softening if the solution is sufficiently weak. As said before, saliva restrains the action of most acids up to a certain point, depending upon the concentration of the acid. Beyond this point we find the same smooth decalcification that we have with the weak aqueous solutions, and finally the same rough, white decalcification that we find in strong aqueous solutions of acid. The saliva solution is ordinarily from ten to twenty times weaker in its action on enamel than an aqueous solution of the same acid strength. Acid sodium phosphate and acid calcium phosphate are, however, intensely interesting in their action not only in aqueous solutions but in saliva solutions. Acid calcium phosphate (1 : 5000 aqueous solution) and acid sodium phosphate (1 : 20,000 aqueous solution) at the end of two days will turn tooth enamel a cloudy, pearly white, with a smooth surface. This surface is perceptibly softened to the cut of a lancet. If, however, the tooth enamel is removed from the solution before the process advances too far, the cloudy appearance will in time disappear, and the tooth enamel will resume its normal appearance and hardness. This phenomenon occurred so consistently not only with the acid salts mentioned, but also with other acid solutions, that the possibility was made

apparent that partially softened smooth enamel could reharden of itself if the decalcification had not progressed too far.

The following test was therefore made: Two sound teeth with enamel impervious to the lancet were each placed in a lobe of an orange. These lobes were each placed in a bottle with a few drops of ether to prevent fermentation, and kept at body temperature for two days in an incubator. At the end of that time the teeth were removed and examined. One tooth showed a smooth, white translucent area of decalcification, running from the cutting edge to about one-third of the distance to the neck. The rest of the enamel was normal to all appearances, and yet the surface, both of the white and of the apparently normal enamel, was readily pared with a lancet. The other tooth seemed normal, but here again the outer surface of the tooth enamel was distinctly softened. This difference in appearance was undoubtedly due to inherent differences in the enamel. These teeth were then washed in water and kept in a specimen of saliva at body temperature for two weeks. At the end of five days there was a decided rehardening of the enamel surface and the white area of decalcification had half disappeared. At the end of ten days the enamel could no longer be scratched with a lancet at the end of two weeks the white spot of decalcification had almost, if not entirely, disappeared, and both teeth appeared perfectly normal.

The question then arose as to whether the carbon dioxid in the saliva was or was not a cause of enamel deterioration. That saliva does possess the power of restraining enamel from carbon dioxid decalcification was proved as follows: A sound extracted tooth was placed in an automatic soda water former (Fig. 17) with 30 c.c. of saliva which had been obtained by chewing rubber. The saliva was then charged with the carbon dioxid and the sparklet placed in a culture oven at a temperature of 98° F. for thirty days. At the end of that time the tooth was taken out and appeared unharmed. The tooth was then washed and replaced in a clean siphon with distilled water. This water was then charged with carbon dioxid, as before, and replaced in the culture oven for twenty-four hours. At the end of that

time the enamel showed a chalky decalcification that could be scaled off with the finger-nail. This experiment proved that carbon dioxid does not attack tooth enamel in the presence of saliva.

Fig. 17.—Type of soda water former used in testing the power of saliva to restrain carbon dioxid from attacking tooth enamel.

The author has also proved that this protective power of saliva is also exerted against lemon, orange, grape, grape-fruit, strawberry, rhubarb and cherry.[1]

These experiments on extracted teeth with weak acid solutions and tests with a sharp lancet, while suggestive, did not seem sufficient to establish the doctrine that softened enamel could reharden; so, while morally convinced of the truth of this assertion, I immediately started to perfect a machine that would show in the minutest degree just how far a given force would drive a standard punch into sound enamel, partly decalcified enamel, and rehardened enamel, if such a rehardening did take place. A microdynamometer (Figs. 18, 19) was finally devised that could deliver 475 pounds pressure on a punch, the penetration of which could be measured up to 1/600,000 inch. Something approaching this accuracy was necessary, as it was found experimentally that the scope of the average test lay usually within 1/100,000 inch. It was, however, decided to set the register so that it would measure in units of 1/300,000 inch, which, as can readily be seen, could be reduced by a table to microns or tenths of microns, 1 micron being equal to 1/25,000 inch; twelve of the machine units, therefore, being equal to 1 micron. The pres-

[1] Journal of the Allied Societies, June, 1908.

sure was given by a mercury gage (9) to which the punch (2) was attached. A micrometer screw and ratchet wheel (8), supporting the anvil, was strongly connected by castings and



Fig. 18.—Microdynamometer.

heavy drawn steel rods beneath to the mercury gage and punch. On this anvil rests a slab (4) with parallel sides on which the specimen (1) to be tested was placed. The pressure was applied to

the specimen by placing it on the anvil and raising the anvil by the micrometer screw and ratchet wheel up against the punch until the mercury marked the pressure desired. The penetration



Fig. 19.—Detail of microdynamometer.

of the punch into the specimen was made known by a microscope (6) equipped with a specially constructed filar micrometer (7), the microscope being screwed firmly to the anvil. This microm-

eter was then adjusted and set so that it could accurately divide into the desired number of parts a glass scale (3) attached to the punch. By this device all error in the use of the machine was largely thrown out, since only the relation between the punch and the anvil was within the scope of measurement. In Figs. 18 and 19 the numbers 11, 12, and 13 represent the counterweight for the mercury gage, the ratchet screw for raising or lowering the glass scale, and specimens prepared for use.

In making the various tests three punches were used: a heavy steel punch with a flat hardened circular point, 0.02 inch in diameter; an iridium-pointed punch for testing acid erosion, 0.02 inch in diameter and standing 25 pounds pressure without showing compression; a diamond-pointed punch with a circular, flat point, 0.02 inch in diameter that could be used in acid solutions and would readily stand 100 pounds pressure—25 pounds pressure with the diamond point gives a penetration equal to 75 pounds with the steel point. This is no doubt due to the greater sharpness of the diamond edge over the steel.

If, therefore, the specimen is so adjusted and set under pressure that there will be no give between it and the anvil, it is possible to determine accurately within one-tenth of a micron just how far the punch will penetrate under a given pressure. For instance, the specimen is carefully ground with a specially adapted section grinder (Fig. 20), so that there is a flat, large base. A small spot on the top of the enamel is ground parallel to the base. This forms the area to be tested. Any pressure exerted on the enamel spot by the punch is directly expended on the enamel without any side give between the base of the specimen and the anvil. The specimen with parallel sides is placed on an agate slab with parallel sides (4) and the slab placed on the anvil. The steel punch, let us suppose, is adjusted near the edge of the ground enamel and given a pressure of 5 pounds. A reading by the microscope attached to the anvil is then taken on the scale attached to the punch. The pressure is then raised to the desired amount, say 75 pounds, for a given time, and then the pressure is reduced again to 5 pounds and another reading taken, the difference on the scale representing the penetration of the

punch. To shift the specimen under the point for the different measurements the agate slab is moved, not the specimen on the slab. This eliminates variations in the spring of the specimen, since the compression of the parallel slab on the anvil under a given pressure will always be the same.

Fig. 20.—*A*, Motor; *B*, stone for grinding specimen cemented to the platen *C*; *D*, micrometer screw for raising and lowering the specimen; *E*, water tank with tube for conveying water to the stone in motion; *F*, handle that swings specimen backward and forward across stone in motion.

Five or more measurements were usually made for each specimen and the average taken. By this means the hardness and strength of normal enamel can be shown, as can also the variations from the normal enamel caused by strong acids, watery solutions of acids, saliva, fresh and stale, and acid saliva solu-

tions; and the recovery of enamel when removed from such solutions.

All analytic analyses of saliva heretofore have been hampered by the fact that the investigator started by first chemically breaking it up, thus largely destroying it as saliva. All analytic investigation of saliva from a dental point of view up to the present time has been inconclusive, owing to the fact that normal saliva may be alkaline to lacmoid or congo red, neutral to litmus, and acid to turmeric paper, all at the same time. How saliva reacts to lacmoid, litmus, or turmeric may be purely of academic interest, but how it may act on enamel and dentin is a vital question, and this machine has opened the way for enamel to be its own indicator of how a saliva may affect it. Since the first days of physiologic study, saliva has been a most tempting field for investigation because it is the body secretion most easily obtained in a living state. To the diagnostician it no doubt eventually will be at least of equal value to urine, but up to the present time it has not been. This may be due to the fact that saliva is a living substance, and urine an effete product that lends itself to a chemical analysis that would absolutely destroy saliva as saliva. Chemical analysis that breaks up the individuality of living saliva is of little more value in showing the vital action of saliva than fried chicken would be in showing the beauties of a cock-fight. I am far from discouraging saliva analysis of any kind. Salivary extracts or chemical products are interesting, but inconclusively related to the living action of the secretion; and therefore, while enzymes of a curious and even therapeutic nature may be extracted from saliva, no one can prove that they justly represent the action of the living secretion unless some means are devised to make control tests with the living saliva that show a corresponding action. The machine just described makes it possible to test the acid-restraining power of various living salivas on tooth enamel in relation to a standard water solution of acid. Salivas vary in this power. The same saliva may vary at different times, apparently according to the condition of the patient.

The conditions, then, are as follows: During sickness the teeth,

from clinical experience, are known to decay. This may be due partly to acid medicine or lack of care, but with every allowance for these sources of error it seems to be well established that severe or chronic illness in some way may render the teeth susceptible to deterioration. If a relation between approaching sickness and a loss of acid-protecting power in the saliva could be established, a beginning in the diagnostic testing of the living saliva would have been fairly inaugurated.

Take, for example, the following test that was made on a specimen of tooth enamel: One side was ground to a flat, broad base; on the other side the enamel was ground in a small corresponding parallel plane. This was placed on the anvil of the machine and raised up against an iridium point, 0.02 inch in diameter, until a pressure of 5 pounds was reached. A reading was then taken on the micrometer scale and noted. The anvil was raised up and down repeatedly until all give between the specimen and the anvil disappeared, and the 5 pounds pressure always gave the same reading. Then fresh lemon juice and water, 1 : 100, was placed on the specimen around the point and the point relaxed so that the fluid could readily get underneath. At certain intervals of time the pressure of 5 pounds was tried and a reading taken, which showed a loss of tooth structure as follows:

2 minutes	0.8	microns
5 minutes	1.2	"
10 minutes	1.4	"
35 minutes	2.3	"
60 minutes	2.8	"

Thus, in one hour there was a loss of 2.8 microns of tooth enamel. This same test was then made on the same tooth enamel with a fresh saliva solution of lemon juice, 1 : 100. This solution turned litmus red and was distinctly sour, and yet after an hour's application the enamel showed a loss of only 0.3 micron. We might, therefore, express the restraining factor of the saliva as 28 : 3. Numerous other tests have been made of a similar nature and all seem to give consistent figures. They almost invariably show the power of saliva to restrain the action

of acid on enamel. They also show that some enamels are much more resistant to decalcifying action than others.

As an illustration another test might prove interesting: The specimen was ground longitudinally for a base along its axis and a small parallel plane ground on the enamel of the opposite side. A solution of 1 : 100 lemon juice and water applied for an hour dissolved the enamel 1 micron; 1 : 100 solution of lemon juice and saliva applied for sixteen hours showed no loss of tooth tissue at all. It was then tested with the steel punch for hardness and was found so softened that more than 60 pounds pressure could not be withstood. The softened enamel simply refused to support the punch under such a pressure. The specimen was then placed in fresh saliva, and set in the culture oven at blood heat for seven hours, the saliva being changed every half-hour. At the end of that time the tooth was again tested with the steel punch and was found to have so hardened that 75 pounds pressure was readily withstood and a various penetration noted of 3.5, 2.8, 3.2, and 4.5 microns.

Further tests made on sound enamel without the use of acids show conclusively that the substance of normal enamel is much harder on the outside surface than within, where it is not exposed to the air or saliva. Surfaces tested immediately after grinding have been known to harden from 15 to 30 per cent. when immersed in saliva or exposed to the air for a period of a few hours or a day. These tests have been repeated and have given results so consistent that the author feels that they are conclusive.

This softening and hardening of enamel has a very practical bearing in relation to mouth cleansing and the use of brush and dentifrices. Enamel that in its hardest state would only show insignificant wear to dentifrice may, in a softened state, lose a very material amount of tooth structure. This softening and hardening may readily account for the fact that some patients, especially those fond of fruit, wear their teeth down at a comparatively early age. The mere friction of mastication is sufficient to take off a layer of enamel softened by fruit or vinegar. This seems to me a sufficient argument against mouth-washes based on fruit acids or vinegar. I am convinced that enamel

will harden and soften within certain limits and that this hardening and softening is influenced by the saliva and food-stuffs. I also believe the same is true of dentin, but so far the tests concerning this are not sufficiently numerous to serve as a basis for a positive assertion.

Fig. 21.—Machine for measuring the force required for mastication.

Force Required in Mastication.—The following experiments were undertaken to determine the amount of triturating force required to chew food, especially meat. For the mastication tests a natural skull with practically perfect molars of average size was cast in bronze. The skull was so arranged that all of the mastication was done with two lower molars and their occluding teeth.

The bronze skull was clamped to a platform (Fig. 21, *A*). *B* represents a cross-bar under the jaws so arranged that the force applied by the spring balance, *C*, will be applied directly to the first and second molars on the left side of the jaw. The force of mastication is then applied through the lever, *D*, and registered by the needle, *E*. The skull is placed at such an angle to the force that a triturating motion is given as the jaws come together. *F* represents the handle by which the lower jaw can be guided by the hand of the operator up to the time the actual force of mastication is applied. The first experiments were with bread. Dry, crisp crusts broke at 15 pounds pressure; but a mixture of

soft inside and crust, such as we ordinarily find, could not be bitten through with a force of 100 pounds. The crust and inside formed a dense immovable mass, but when a little saliva was placed on this same mass, it was readily masticated with a force of 3 pounds. Asparagus, roast onion, peas, and roast potato were chewed with 1 to 2 pounds pressure. Raw cabbage required a pressure of 16 pounds; raw onion, 4 pounds; head lettuce, 8 pounds; whole radishes broke at from 20 to 25 pounds, while pieces broke at from 10 to 15 pounds.

This gives a fair idea what triturating force is required for the mastication of vegetables.

Following is a table of the triturating forces necessary to masticate meat:

	Pounds
Corned beef	18 to 22
Boiled beef	3
Tongue	1 to 2
Lamb chop	16 to 20
Roast lamb	4
Roast lamb kidney	3
Tenderloin of beefsteak, very tender	8 to 9
Sirloin steak	10, 20, 43
Beef, bottom of round, tough	38 to 42
Roast beef	20 to 35
Boiled ham	10 to 14
Broiled ham	10 to 13
Pork chops	25 to 30
Roast veal	16
Veal chops	12
Roast mutton	18 to 22

Dr. Black's tests have shown that the human jaws can exert a pressure of from 150 to 300 pounds. I show here a man biting 340 pounds on a gnathodynamometer (Fig. 22). The force required to crack a hazel or pecan nut, such as the ordinary urchin breaks with ease, is 100 to 230 pounds. These tests, of course, are not recommended unless the teeth are exceptionally strong and the sockets absolutely healthy, for if the teeth are sensitive to pressure the jaws will instinctively avoid their full force. It is, therefore, clear that thorough mastication and hence proper digestion of the food is only possible when the teeth are

sound and the gums free from infection; and such a condition of the teeth and gums can only be maintained through scientific mouth hygiene.

Dentifrices and Mouth-washes.—As stated in Chapter II, mechanical cleansing of the bacterial masses will reduce the germs to an insignificant number and it will also cause an auto-inoculation by rubbing the infection into the tissues, thus stimulating them to form protective bacterial ferments. The ferments thus formed are so effective in restoring inflamed tissues to health

Fig. 22.—Gnathodynamometer for measuring the force exerted by the closing of the jaws. This represents a man biting 340 pounds—over twice his weigh .

that all other means for combating the invading infection sink into secondary importance. Thus the blood-serum thoroughly charged with protective antibodies might justly be termed the most effective mouth-wash at our disposal; for this mouth-wash by its very nature is most readily applied to the invading hosts even when they have penetrated deeply below the surface of the mucous membrane.

And yet there are certain mouth-washes and antiseptic dentifrices that can be used to effectively supplement the pro-

tective elements of the blood, but they must be considered purely supplementary in their action. Any chemical mouth-wash sufficiently strong to kill bacterial masses in the time permitted for its application in the mouth must be strong enough to be poisonous to the tissues, and such a result is apt to weaken the resistance of the tissue cells against further bacterial attacks. Effective mouth-washes and antiseptic dentifrices should co-operate with the curative action of the tissue cells without weakening them.

Heretofore this important principle underlying the use of antiseptics has not been sufficiently understood. Strong antiseptics, as washes, have been used without the preliminary mechanical removal of the bacterial masses in the vain expectation that the strong germicidal wash would be able to destroy and wash the adhesive colonies away. Under these conditions the exterior portions of the sticky masses of germs alone are killed, leaving the infection unharmed beneath the surface of the bacterial plaque to continue its attacks on the tissues with which it is in contact. And the rest of the mucous membrane of the mouth, which was not covered by the bacterial plaques, continues to have its bacterial resistance lowered by the use of the strong antiseptic, and is rendered more likely to accept infection after the protective action of the strong antiseptic has been dissipated by the oral fluids.

In addition to the bactericidal action of the blood there are at least three health-restoring processes in the mouth. First, a substance that is present for the specific purpose of special protection, which is illustrated by the saliva's power of retarding enamel decalcification; the second consists of an automatic power of resistance and self-repair, which is illustrated by the power possessed by tooth enamel to reharden after partial decalcification by acids; third, its power to reharden the surface when its soft under substance is exposed by attrition to the saliva or air.

Salivas have different protective properties, and the saliva in the same mouth will show a great variation in its preservative power under various conditions of the system. It is possible that

gout, diabetes, tuberculosis, arteriosclerosis, or even a bad attack of grip, may reduce the vitality of the agencies resisting enamel deterioration.

It will be noted by the careful observer that many mouth-washes, such as solutions of chlorate of potash, peroxid of hydrogen, and sodium silicofluorid, have wonderfully healing properties in the mouth, and yet in the dilutions used in the mouth they have not apparently any marked germicidal action. Thus we have had up to the present time a supposedly irreconcilable difference between clinical experience and laboratory research. But fortunately the wonderful researches of Ehrlich[1] concerning the germicidal action of salvarsan have thrown light on this most important subject. Ehrlich found that the syphilis germs exposed to the action of salvarsan were neither destroyed nor rendered in any way different as regards appearance or activity, but that they were nevertheless sensitized, so that the white corpuscles of the blood could eat them in a way impossible to syphilis germs that had not been subjected to the action of salvarsan. He then formulated the principle that germs might be sensitized by a comparatively inert drug, so that the bacterial action of the tissues or blood might digest them. The effective non-germicidal agents, such as chlorate of potash, peroxid of hydrogen, and sodium silicofluorid, probably act on this principle.

Recent experiments under the supervision of Dr. A. P. Hitchens indicate that a 1 per cent. peroxid solution has the same strength in inhibiting the growth of typhoid bacilli as a 1 per cent. carbolic acid solution. This action, while non-germicidal, is a valuable scientific fact, and is particularly interesting in reference to the antiseptic action of certain oxygen-liberating dentifrices which claim to cleanse the mouth by the development of hydrogen peroxid. The idea is so excellent that it should be given encouragement by both pharmacists and the public at large, but as yet none of the widely exploited peroxid-forming dentifrices, according to the analyses that have come to my notice, have ever been able to develop more than 0.5 per cent. free oxygen. This, as can be shown mathematically, cannot

[1] The Lancet, August 16, 1913.

form more than 35 minims of the standard 3 per cent. peroxid solution for each 100 grains of dentifrice. The amount of tooth-powder capable of being put on an average tooth-brush is seldom as much as 10 grains, which 10 grains or less of powder would have to be depended upon to deliver the antiseptic action to the mouth. These 10 grains of tooth-powder, under the most favorable conditions, would then deliver 3⅓ drops of the official peroxid solution, no more; 3⅓ drops or even 5 drops would be palpably inadequate to have any effect in the mouth. Some of these preparations that have been claimed to have the power of sterilization by free oxygen, under analysis did not show the presence of free oxygen at all. This was due to some error in the manufacture, no doubt, but for practical antisepsis in the mouth it really made little difference, as 3 drops of peroxid of hydrogen would be so rapidly diluted and broken up by the oral fluids that its antiseptic value in the course of half a minute could be hardly much more effective than so much distilled water.

Peroxid of calcium and peroxid of strontium, as recommended by many writers, are entirely too caustic to be used pure in the mouth. When placed in any quantity on the tongue they make a bad burn that lasts for days. However, the commercial preparation of peroxid of magnesium is especially bland and effective. It comes diluted with magnesium hydroxid and carbonate, so that it variously yields from 4 to 7 per cent. free oxygen, and is only soluble in about 15,000 parts of water—practically insoluble. This powder can be freely taken into the mouth in any quantity, liberating for every 100 grains enough oxygen to make 280 to 500 drops of a 3 per cent. alkaline peroxid solution. The commercial powder has just about the cutting grit of precipitated chalk, and when finely powdered, practically none at all. When it is evacuated from the mouth large quantities adhere to the interstices and necks of the teeth. This tendency may be turned to great advantage by the patient, for while this powder is practically insoluble in water, it is readily converted into a soluble magnesium salt by any acid that may chance to be present. Perborate of soda, as will be shown shortly, has no grit at all.

But now let us discuss the question of abrasives in dentifrices. All thoughtful dentists must have noticed that there is a terrible loss of enamel in the mouths of those who are particularly careful of their teeth, and this appears generally between the ages of forty and fifty and is made manifest by the complete disappearance of the enamel in ever-spreading foci on the labial surfaces of the front teeth. This has been explained by many as arising from gout, rheumatism, the absence of the sulphocyanates in the saliva or an excess of acid calcium phosphate. A systemic cause may be partly responsible for this condition, but the author does not know of a single case of such erosion in the mouth of a patient who did not use tooth-powder excessively and who was not abnormally fond of acid fruits. As the loss of the enamel is confined almost entirely to incisors, canines, bicuspids, and first molars, it would seem strange that a disease wholly systemic should not attack all of the teeth of the mouth with equal impartiality.

Destructive Action of Dentifrices.—In 1908 I published in the Dental Brief experiments showing the effect of grits on the teeth, proving that tooth-powders, even of chalk, were largely instrumental in cutting the well-known smooth grooves in the necks of teeth, that so frequently appear from second molar to second molar. These characteristic grooves were readily reproduced on extracted teeth outof the mouth. At that time, from experiments made with a brush-wheel and pumice, I erroneously thought that grits had no effect on the enamel of the grinding surfaces. Although these tests were judged only from their macroscopic effect, and no measuring instrument of precision was used, and although they were faulty, inasmuch as they did not reveal the full extent and significance of the destructive action of pumice, chalk, etc., they were the beginning of my investigations in this field. Later on a series of experiments was undertaken to determine just what would happen to the enamel and cementum of a tooth when brushed with an ordinary tooth-brush and saliva; when brushed with certain mouth-washes; when brushed with certain proprietary dentifrices; and finally, what happened when brushed with plain precipitated chalk.

In each instance the loss of tooth substance was carefully determined by an especially constructed Brown & Sharpe micrometer. The first test was made to determine the effect of brushing the enamel and cementum for ten minutes with a new brush and saliva alone. Many such tests showed that the brush and saliva seemed to have no harmful effect on cementum or enamel. Six of the most prominent and best advertised dentifrices were then tested, a new brush being used with saliva and dentifrice for each test, the brushing being continued for ten minutes:

Dentifrice No. 1 cut off 0.0001 inch of enamel and from 0.0023 to 0.0083 inch of cementum.

Dentifrice No. 2 gave a loss of 0.0001 inch of enamel and 0.0026 inch of cementum.

Dentifrice No. 3 gave no loss of enamel and a loss of 0.0066 inch of cementum.

Dentifrice No. 4 gave a barely measurable loss of enamel and 0.0121 inch of cementum.

Dentifrice No. 5 caused no loss of enamel and 0.0073 inch of cementum.

Dentifrice No. 6 caused no loss of enamel and 0.0007 inch of cementum.

The only reason the powders with grit are so popular, in my opinion, is because they make the front teeth presentable with a minimum amount of labor. The unsatisfactory results are partly due to laziness and partly due to the inefficient, unscientific teaching of the profession, who have recommended methods of tooth-brushing that a simple inspection of the mouth will show do not cleanse the teeth.

Having investigated some of the prominent proprietary dentifrices, I next applied the same tests to the standard chemical substances that might prove of value in mouth prophylaxis. I found, as would be expected, that ordinary chalk would cut the cementum and enamel. Thinking there might be an excess of silica in it, precipitated chalk, guaranteed to be free from silica, was procured from a standard chemical company. It seemed to cut more than the others. The abrasive action of peroxid of magnesium was next tried and it was found that in its coarse

state it had a friction grit on the enamel and cementum somewhat less active than precipitated chalk, but nevertheless a decided grit. When, however, the peroxid of magnesium was ground in an agate mortar to impalpability no such erosion was attained, thus showing that in peroxid of magnesium we can have a grit slightly less than chalk down to almost no grit at all, and also a tooth-powder that will give abundant oxygen. I next tried the frictional action of perborate of sodium mixed with saliva on a tooth, and found that there was no erosive action that could be detected by the Brown & Sharpe micrometer. This was particularly gratifying, as perborate of sodium is a bland salt that can be freely placed in the mouth without caustic action; it liberates 9 to 10 per cent. of oxygen, and in the presence of any acid that may be present forms a strong alkaline peroxid solution.

Therefore, when there are any grooves on the front teeth the author forbids the use of grit dentifrices and recommends the use of perborate of soda alone; and when patients have been carefully instructed in the proper way of brushing their teeth, perborate of soda seems quite able to keep the teeth clean. For patients that have healthy gums, with no tendency to gum recession or thinning of the enamel, the following formula may be used:

Peroxid of magnesium (sieve 200 fine)	60 parts.
Perborate of sodium	30 "
Pulv. saponis	10 "
Flavoring to suit.	

When an extracted tooth was brushed for ten minutes with this powder no loss of enamel occurred and a barely measurable loss of cementum.

Three specimens of chalk were also tested: The first sample was made by precipitation in 50 liters of water with slow precipitation. The second was made by quick precipitation in a strongly concentrated solution. The slow precipitate, as would be expected, gave a larger crystal than the quick precipitate. The larger crystals of the first specimen varied from 17 to 5.6 microns

in diameter; the smaller crystals of the second specimen measured from 4 to 2 microns in diameter. The third specimen was composed of precipitated chalk very finely ground, and yet these three specimens seemed about equally destructive of enamel and cementum. This would indicate that it is the chalk itself, not the preparation, that is responsible for its destructive action.

Specimens of silicious earth, precipitated phosphate of calcium, precipitated carbonate of calcium, and calcined magnesium (light) were tested for their erosive action, as the table of tests will show. In these erosion tests a tooth-brush charged with saliva and various grits was swept by hand over a natural tooth for ten minutes. Saliva from the same mouth was used throughout all the tests:

	Number of minutes.	Loss of enamel 0.0001 inch.	Loss of cementum 0.0001 inch.
Dentifrice 1	10	1	26
Dentifrice 2	10	1	83
Dentifrice 3	10	0	66
Dentifrice 4	10	a trace	121
Dentifrice 5	10	0	73
Dentifrice 6	10	0	7
Dentifrice, Dr. X	10	1	33
Dentifrice, Dr. Head (old formula)	10	1	20
Various kinds of precipitated chalk	10	1–3	8–18–28
Magnesium carbonate (precipitated)	10	0	19
Precipitated calcium phosphate	10	1	36
Tooth brushed with saliva alone	10	0	0
Magnesia, calcined	10	1–3	27
Perborate of soda	10	0	0
Dr. Head's new formula	10	0	3–9
Very fine peroxid of magnesia	10	0	0
Saturated solution of sodium silicofluorid	10	0	0
Hexamethylenamin	10	1	1

Summary.—In closing this chapter let us briefly go over some of the points that might properly be emphasized. Tooth-powders containing grits are harmful to both enamel and cementum, and the patients should be taught to brush and cleanse the teeth without their aid. All stains that cannot be removed without the aid of tooth-cutting grit should be removed only by the dentist. Moreover, the patient should be trained so

thoroughly in the use of the brush and floss-silk that dentifrices and mouth-washes will be of minor importance. Very finely powdered peroxid of magnesium, with 10 per cent. of soap and a suitable flavoring agent, makes a valuable antiseptic peroxid powder, and when left around the teeth at night it will prove an invaluable antacid. For those who do not wish a semblance of grit in their powder, flavored perborate of soda can be used both on the brush and also, in 10-grain tablet form, as valuable mouth-wash tablets.

A 1 per cent. peroxid of hydrogen wash held in the mouth for two or more minutes will reduce inflammation rapidly and quickly. A saturated solution in water of sodium silicofluorid is also ordinarily useful. It forms a 0.61 per cent solution. This may be held in the mouth from two to five minutes, three times a day, by patients under treatment for pyorrhea. While in some few cases it causes a brown precipitate on the teeth which, however, is easily removable, in every case its healing effect on the inflamed gums is so satisfactory as to be little less than marvelous. It is non-poisonous and cheap, being readily purchased c. p. at 75 cents a pound, which is enough to make almost a barrel of mouth-wash. And, above all, being a fluorid, it has the fluorid antiseptic qualities without the usual resultant erosive action on the procelain crowns or fillings.

CHAPTER IV

TREATMENT OF MOUTH INFECTION

General Diagnosis.—In determining the causes of mouth infection it is of utmost importance that a comprehensive study should be made of the entire body to determine the presence of associated disease. And here is where the sympathetic, scientific co-operation between the general practitioner and the dentist is of the utmost importance. Purely local infections can be treated and cured by local treatment, but where the mouth infection has spread to other organs of the body, such as the stomach, intestines, genito-urinary tract, etc., secondary infection occurs which weakens the bacterial resistance of the blood and causes the original infection to reappear in the mouth, even though it had temporarily yielded to local treatment. Normal blood has a certain germicidal power that will ordinarily resist bacterial invasion. But if the bacterial invasion becomes intrenched both in position and number, and lowers the resistance of the blood, it is evident that the first step in the restoration of the blood to its normal germicidal power is to first remove the depot of infection that is the primary cause of blood poverty.

The mouth has long been considered a sort of health barometer of the general body. It is now recognized not only as a gage of the general systemic health, but also as one of the principal sources of primary infection that may spread general disease. This, by reacting on the body vigor, may increase the mouth infection, which will, by its increased reaction, cause a still greater lowering of the general vitality. In fact, mouth infection in its relation to the whole body might be likened to a vicious political gang in its relation to the state. The gang captures the city organization through weakness or sluggishness on the part of the voters, just as the infection makes its first in-

road into the tissues. Being intrenched in the city government, the gang poisons the minds and lowers the moral resistance of influential citizens by concessions and special privileges that make them dependent on the gang for their subsistence. Similarly, the once healthy tissues finally endure bacterial invasion in the form of chronic infection, which from that time on pours its toxins into the blood stream, causing degeneration of the vital organs, any one of which may then become a new depot of infection, sending out poisons that strengthen the power and position of the original bacterial gangsters. And just as at the start the elimination of the original infection or gang would have prevented the general infection, so when the infection becomes general and is composed of a number of individual gangs or depots of infection, every one of these infecting depots must be removed before the body or state can be considered sound, for each one of the depots can spread and become general just as the first depot of infection spread.

Thus, mouth infection cannot be considered from a purely local point of view, but must be treated both as a symptom and a cause. Where it is pronounced, and the teeth and gums show general advanced deterioration, the general practitioner should go over the heart, lungs, liver, spleen, kidneys, etc., with special care, and the general body weight should be carefully noted. In fact, no means of investigating the body for depots of infection should be neglected. Any tuberculous, syphilitic, or gonorrheal taint should be treated as a matter of vital importance. The eye, ear, nose, throat, and especially the tonsils should be examined, and if found infected, should all be treated, thus eliminating them as possible depots of infection. This does not mean that ten or twenty doctors will have to be working on one poor patient at the same time. Ordinarily the co-operation of a general practitioner will be all that is necessary.

Many physicians are laboring under the mistaken idea that the mere extraction of infected teeth will be sufficient to remove the full effects of the infection. Such extraction will effect a cure only while the infection is purely local, but as the infection may have spread to other parts of the body through bacterial

migration, the extraction of an infected tooth may be as beneficial as locking the stable door after the horse has been stolen. Such extraction without a judicious bacterial examination may actually do harm, since it will take away the opportunity of following the infection in its migration through the body and eliminating it by an autogenous vaccine made from the original source of infection.

The urine should be carefully examined, with special reference to the presence of albumin, sugar, casts, and indican. Indican is frequently present as a systemic association of mouth infection, and its disappearance is noted as the treatment progresses to a successful termination. A careful and complete blood-count should always be made. The intensity of the hemoglobin and the number of the red corpuscles should be noted. The white blood-corpuscles should be especially observed to see if any leukocytosis is present. The differential white blood-corpuscle count should be also made with a view to seeing whether there is any marked lymphocytosis, as this would caution us to look for inflammatory lymphatic enlargement during the treatment. The joints should be examined for gouty deposits and crepitation. This especially applies to the knee-joints. The glands of the axillæ and neck should be examined for enlargement. In a woman the breasts should be examined for hard lumps or indurations, as these will have a special lowering effect upon the system and should receive surgical attention, if necessary. In fact, a dentist in treating mouth infection is like a countryman at a fair who buys a pair of gloves with the privilege of taking a grab in the grab-bag. The dentist knows he is going to treat and probably cure the mouth infection, but he does not know what other disease he is going to unearth and cure with the aid of the general practitioner. It therefore is wise to have a general diagnosis made on as broad lines as possible, so as to note the general systemic improvement as the mouth infection disappears, and to make it possible to give a more accurate promise in regard to the permanence of the cure.

Local Diagnosis.—Having laid down in a general way the lines of investigation that should be followed in the physical

examination and the laboratory, let us discuss what measures should be taken in the local diagnosis of the disease in the mouth. All inflamed spots should be noted and each tooth should be tested between the fingers for looseness. Then a fine probe should be passed around the necks of all the teeth, searching for pockets of infection, for these are not by any means always associated with redness or inflammation. Where there is an old chronic infection around a root there may be no redness or soreness. In an adult, where the instrument goes under the gum for a distance of $\frac{1}{8}$ inch, peridental deterioration is indicated; and where the probe will penetrate between the root and the bony socket for $\frac{1}{4}$ inch or more a pyorrhea pocket of infection is surely present and should be so considered and treated. When the pocket of infection extends so far along the root as to approach the tip, it must not be forgotten that the pulp within the tooth has undoubtedly become infected and that the pocket cannot be healed until the pulp within the tooth has been removed, and the nerve canal or canals sterilized and filled antiseptically. Special care should be given to the spaces between the teeth, as the pockets of infection usually start in such places.

Having carefully examined the gums for pockets and open fistulæ, the condition of the pulps of the teeth should next be investigated, because a living pulp infected either by a cavity of decay, filled or unfilled, or by gum infection along the root, may be a serious depot of general infection. As before stated, an infected living pulp will hinder if not prevent the healing of the inflamed gum around it, so long as it is in a position to pour out its insidious stream of infection through the tip of the root. Infected pulps are either oversensitive or undersensitive to the application of heat. If the infection has, as one might say, exasperated an inflamed tissue, the tooth will be excessively sensitive to heat to such an extent as to cause a flash of pain that will extend over the entire side of the face. If, however, the infection has progressed so far that the pulp is dying or nearly dead, heat will cause little or no reaction. The instrument for such diagnosis consists of an electric cautery heated to the point of just turning paper black (Fig. 23). This electric

cautery can be kept at an even temperature and, therefore, the same amount of stimulation will follow its application to the teeth during a given period. Thus the relative irritability of the pulps can be readily ascertained, which palpably would not be possible with a steel instrument heated in the gas flame. Having, then, heated the electric cautery just to the point of turning paper black, it should be applied to the neck of each tooth for a second at a time. If the consequent pain immediately disappears, the pulp is probably normal, but if the pain does not disappear for three or four seconds, infection of the pulp is indicated; and if a flash of pain extends over the face, causing a lasting neuralgic thrill, the pulp is seriously infected and should

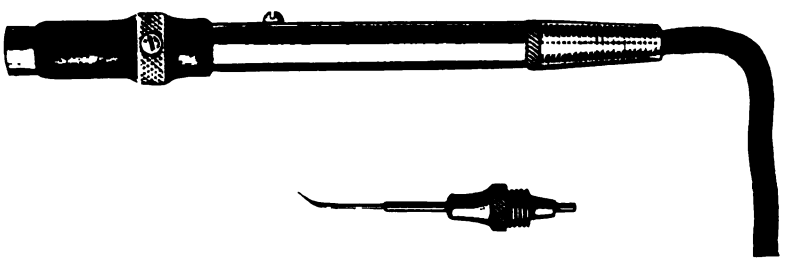

Fig. 23.—Electric cautery used in diagnosing the condition of the dental pulp. (Cut ¾ actual size.)

be removed at once. Where no reaction at all is obtained and the tooth shows no signs of the pulp having been removed and the canals previously filled, the tooth should unquestionably be opened and the canals sterilized and filled, because clinical experience has proved that in such a case the pulp is usually dead and putrescent and may be the cause at any time of violent organic infection. Teeth with dead pulps may be associated with pain during the process of mastication or may be especially sensitive to a sharp rap on the masticating surface, a condition which exists when the irritating infection is acute. But when in the course of time the inflammation has become chronic, the tooth may appear almost normal and the electric cautery is the best diagnostic instrument for detecting the true condition by demonstrating an absence of response to heat. It must, however,

be remembered that some teeth are normally insensitive to heat, while others are supersensitive, this being a systemic condition of the nerves in general. Therefore, variations from the normal response should be regarded as significant of possible pathologic irritation and infection. It also must be remembered that the molars ordinarily respond to changes of temperature much less than central incisors or canines, owing to the difference in the amount of tooth structure the heat has to travel before reaching the pulp. Therefore if a molar and canine respond equally under stimulation, it will indicate that the molar is oversensitive or the canine less sensitive than normal. When a general lack of response to heat is noted, unaccompanied by inflammation in the gums surrounding the teeth, we should always bear in mind that this may be due to a normal atrophy of the pulps, unaccompanied by infection. In such a case, unless there is

Fig. 24.—Automatic hammer, formerly used for inserting gold fillings, now most effective in testing relative sensibility of teeth to the force of percussion.

a systemic depression indicating a masked depot of infection, such teeth should be left undisturbed. If, however, applications of the cautery cause an extraordinary flash of pain in any one tooth, lasting for several seconds, the pulp should be removed and the canals filled. The instrument for testing sensibility under percussion is the automatic hammer that will give a blow of from 4 to 6 pounds (Fig. 24). The old plugger used for malleting gold will serve this purpose admirably. Each tooth should be tested with this hammer on the grinding surface for sensibility at the tips of the roots, for, as just stated, where infection has been forced into the gums, such a blow will be associated with much pain unless the inflammation has become chronic. It is astonishing how these tests for excessive mobility, exploration for pockets and fistulæ, reaction to heat, and reaction to a blow or pressure will corroborate one another. Where a tooth shows excessive mobility, and the pulp is infected to the point of inflammation,

there will be a sharp reaction to heat, and usually it will be associated with a pus pocket in the gum, and frequently will be sore to pressure. Also where there is excessive mobility the tooth may or may not be associated with a pus pocket, there may be no reaction to heat, and it may or may not be sensitive to pressure, showing a state of more or less chronic infection that is none the less dangerous because it is masked.

Fig. 25.—Dry-cell battery, supplied with a milliammeter, used in diagnosis and treatment of blind abscesses. Various terminals are shown.

Electrolysis Test.—There is another test that is occasionally valuable in diagnosing the presence of a blind abscess under the gum, namely, the ionization test with the direct current of an electric battery (Fig. 25). The direct current of a series of dry cells is used. The positive pole is placed in the hand of the patient in the form of a large wet sponge. The negative pole, in the form of a small German-silver electrode, the sides protected by rubber,

is then swept back and forth over the infected areas, with the current turned on until it reaches 1 or 1½ milliamperes.

Four or five dry cells are usually enough to give such a current, but it is better to have 16 in all, to allow for deterioration. When the negative pole has been swept across the gum for a minute or so, a white froth begins to come through the gum, that looks something like pus, but is not pus as it can be obtained from healthy tissue as well as from inflamed tissue, the only difference being that in healthy tissue a stronger current is required. This froth can come through the gum without causing any wound or erosion, and its extraction from an inflamed gum has special therapeutic value. When ½ to 1 dram of this frothy serum has been obtained the pain and irritation of the tissue treated will disappear in a manner almost magical, and in a day or two the tissue will usually be found to have healed. This instrument skilfully used for an hour or more will even abort an acute alveolar abscess. As a test for the presence of a blind fistula the negative pole is swept over the inflamed tissue and the frothy serum is extracted as previously described. If there is a blind fistula near the surface, a red spot will suddenly appear on the gum and the fistula will be actually drawn to the surface. The rest of the gum region being wiped dry will appear unchanged, except that it will be less inflamed and engorged.

A possible though probably incomplete explanation of this phenomenon is as follows: The large positive pole distributes and weakens the intensity of the current to such an extent that there is practically no local therapeutic action. But the current at the negative pole is concentrated, and there the blood-serum is broken up by the ionization into the positive and negative ions—since the positive pole of a battery attracts the negative ions, and the negative pole, the positive ions. The negative pole of the battery extracts these positive ions, leaving the negative ions free within the tissues. A large proportion of the substance of the blood-serum is water, which is composed of hydrogen (positive) and oxygen (negative), and thus the negative pole in extracting frothy serum most probably extracts the positive hydrogen from the water of the serum and leaves within the tis-

sues nascent oxygen which has long been recognized as a powerful germicide and stimulator of cell growth. Just how the oxygen stimulates the cell growth or acts as a germicide may not be quite clear, but just as we know that it is necessary for the oxygen entering the lungs to permeate all the tissues of the body, if the body is to develop and grow, so it is not unreasonable to suppose that by the electric battery applied in this manner we have made a sort of local respiration and have produced locally on tissues of reduced vitality the same stimulation that the oxygen from the lungs is producing generally throughout the body. This theory does not take into account the possibly important action of the other negative ions that are set free with the oxygen, the action of which may also have great therapeutic value.

So, basing the theory of this therapeutic phenomenon on the stimulating action of nascent oxygen set free in the tissues, which theory is admittedly incomplete, the following would be a possible explanation: Inflammatory gum tissue contains more fluid than the normal tissue, and therefore is perhaps a better conductor of electricity. Where there is the greatest current there will naturally be the greatest cell disintegration, and therefore where there is a blind abscess hidden under the gum there will be a natural path for the electric current which will concentrate on that spot and break down the overlying tissues so as to reveal the path of the fistula hidden beneath. When this hidden fistula is revealed, it can be opened and treated surgically. The *x*-ray photograph, as will be shown later, is a valuable guide in diagnosing the conditions of the hard tissues, but it gives very little idea of the inflammatory state of the soft tissues covering the bone, and this ionization test will frequently reveal conditions hidden beneath the mucous membrane that could be revealed in no other way.

This therapeutic phenomenon, as shown by the direct electric current, was brought to the attention of a dental society some fifteen years ago by a man who claimed that he could cure a boil by the application of the current as just described. He even claimed that he could draw pus from a boil on one arm through the body and out on the other arm. This preposterous claim

caused him, metaphorically, to be laughed out of court, and he made very little impression by his statements. However, there were a few who were impressed by his evident sincerity, and they found that while his explanation was wrong, and that he did not extract pus, as he claimed, nevertheless his method did reduce inflammation in an extraordinary degree. It is a matter of fact, however, that this method as just described has been successfully applied to the cure of inflammatory tissue.

The **violet-ray** (Fig. 26) is also a great aid in the diagnosis of the condition of the pulp within a tooth. The current should be turned on until the spark will jump about $\frac{1}{8}$ inch from the electrode to the finger held near it as a test. The electrode should then be placed upon the cutting edge or grinding surface

Fig. 26.—Violet-ray apparatus.

of the tooth to be tested. An interrupted current should then be thrown on the tooth. This can be easily done by the operator tapping the electrode with his finger. If the pulp is inflamed, there will be an intense response; if the pulp is slightly alive, there may be a response that would hardly be obtained by the cautery; and if there is no response at all, it is wise not to be too sure that the pulp is dead unless these tests are corroborated by others. Unbroken tooth enamel sometimes offers complete resistance to the violet-ray, but the exposed dentin ordinarily accepts it readily. This test should always be used as a check to the cautery test, which it supplements in an interesting way. Sometimes the application of the violet-ray will cause an active stimulation to a tooth where the pulp is dead and a blind abscess

has formed at the tip of the root. This may be due to pressure occasioned by liberation of gases from the fluids in the bony cavity beyond the apical foramen. The application of the violet-ray is also an excellent means of reducing general inflammation of the mouth.

And last, and one of the most important means of diagnosis, is the *x*-ray, which will be dwelt upon at length in Chapter XII.

Local Treatment.—Having seen that the patient receives a thorough general treatment in order that the depots of infection may be removed from other parts of the body than the mouth, it is then most essential that the dentist should see that no foci of infection should be overlooked in the region over which he has particular control. Every crown should be examined as a possible depot of infection; if the edges project into the gums and cannot be smoothed so as to be non-irritating to the surrounding tissues, the crown should be removed and replaced by one that will not be a depot of infection. In fact, one of the easiest ways of tightening a loose root is ordinarily to remove a badly fitting crown. This one act is frequently all that is necessary to effect a cure. After the crown has been removed the inside of the root or tooth should be carefully tested for infection within the canal. If the pulp is alive, it should be tested with the cautery or violet-ray electrode to see if it is sound, but as it usually happens in such cases that the pulp is diseased or dead, the canal or canals should be opened and properly cleansed and filled. And here it can be stated that if there is no fistula, open or blind, at the end of a root that has been properly filled, and if there is no pocket around such a tooth, that tooth or root can be excluded absolutely as a source of infection, and attention can confidently be turned to other portions of the mouth. It is well to emphasize this fact, since many good serviceable roots and teeth have been ruthlessly extracted at the order of the medical profession in a desire to get rid of mouth infection; and while it is no doubt better that five good teeth should be extracted rather than that one depot of infection should remain in the mouth of a patient, it is nevertheless unfortunate that any good teeth should be sacrificed for the lack of proper scientific diagnosis and treatment.

But to continue in our surgical treatment of mouth infection. What was said of crowns applies even more to bridges that cannot be cleansed between the bridge and the gums, and especially around the supporting roots. No bridge should be inserted in the mouth that cannot be kept clean as the natural teeth, and where this is impossible, and where the bands of the supporting crowns project into the gums, forming ledges for infection, the bridges should be removed and the supporting abutments investigated, and, if necessary, treated. The non-cleansable bridge should be replaced by a bridge that is natural in appearance, effective for mastication, and capable of being cleansed as thoroughly as any of the natural teeth.

Next, every tooth should be examined for cavities of decay, and all the fillings in the teeth should be carefully examined for recurrence of decay. When a cavity of decay is found or recurrent decay is discovered under a filling, all of the decayed material should be thoroughly removed, and if the pulp is thereby exposed, it should be anesthetized and removed, for it is inconceivable that decay could reach the pulp without seriously infecting it. It is true that such an exposed pulp may be capped and preserved in a living state for years, but ordinarily the extreme sensibility of the tooth to thermal change or the steady decrease in normal sensibility marks it as a source of possible if not probable infection to the system at large. As long as infection was not recognized as a source of systemic danger, the preservation, by capping, of a pulp exposed by decay was defensible, but in the light of our newer knowledge, it is indefensible, and the time is not far distant when it will be called malpractice, for the pulp of a thoroughly developed tooth is not essential to its vitality, appearance, or functions. The pulp is the organ that forms the tooth-bone during its formative period, but that period being over, it is exceedingly prone to deterioration and infection. The real nourishment and maintenance of a tooth come from the membrane supporting it in the tooth socket, and as long as this membrane is healthy and free from infection there is no fear but that the tooth will be able to perform all of its proper functions. It is commonly believed that teeth deprived

of their pulps discolor. This is not necessarily so if the pulp is thoroughly and antiseptically removed. Discolorations of the teeth arise from putrefaction of the pulp within the tooth, which becomes infiltrated with decaying matter. After the living pulp has been removed the application of a 4 per cent. formaldehyd solution or any good albumin coagulant will prevent the breaking down of the albumin of the tooth, and with proper filling of the canal no discoloration need be apprehended. When the decayed spots in the teeth have been cut out and filled, the infected pulps removed, and the infected canals sterilized and properly filled, the dentist must not forget to examine the necks of the teeth for fillings with overhanging edges that may collect masses of infection. Any such overhanging edges should be carefully smoothed and polished with fissure burs, polished until the necks of the teeth are beyond suspicion as collectors of bacterial colonies. Next, the interdental spaces should be carefully examined to see if the approximation of the adjacent teeth is sufficiently accurate to prevent the food from being jammed down on the gum between them during mastication. Such jamming spikes the delicate gum on the underlying point of bone that lies between the teeth, and so starts an infection that, unrestrained, will result in a pus-pocket along the sides of the root. Restoration of the proper approximation of the sides of the teeth is one of the prime means of curing invading infections of the gums between the teeth.

It is also important to restore the normal occlusion of the teeth. When a tooth has become inflamed in its socket, the peridental membrane is apt to acquire a chronic thickening that raises the tooth in its socket and leaves it permanently higher than its neighbor. Thus, in its weakened condition it has to stand the full force of mastication that should be borne by all the teeth on that side of the face. The jaw can ordinarily develop 150 to 300 pounds pressure in the mastication of food, and this weakened tooth while receiving such a shock cannot hope to regain its normal tone. It takes what pressure it can, and then by its painful protest warns its owner of its danger. The owner, therefore, does not bite so hard, but favors it, and in so doing

does not properly chew his food, and so another cause of systemic deterioration is established. Therefore it is of primary importance that all abnormalities of tooth occlusion should be remedied, and if any tooth projects above its normal line it should be cut down with an engine stone until the pressure of mastication can be received equally by all the teeth. It is often worth while to cut a sore tooth down below the normal bite so that it can be given a complete rest until it regains its normal tone.

When a loose tooth can be advantageously saved it should be splinted or fastened to an adjacent firm tooth, so that the act of mastication will not bruise or twist it in the bony sockets of the jaw. This can be done by tying them firmly to each other with twisted silk twine, until the loose tooth yields to treatment and becomes firm. Loose teeth that have become irregular should be straightened before they are tightened by treatment, and the straightening can usually be done by the twisted silk that is

Fig. 27.—Wire needle, No. 26 brass or gold wire, used for threading dental floss in cleansing the interdental spaces.

splinting the teeth together. They can be permanently splinted together when desirable, by means of platinum staples inserted from the nerve canal of one tooth to the nerve canal of another, the staples being set down in the substance of the tooth below the line of mastication. When the tying or stapling is done care should be taken, as before stated, to instruct the patient how to cleanse the interdental spaces. Under such conditions this is accomplished by the use of floss-silk threaded between the teeth by a flexible wire needle (Fig. 27). The needle is made of gold or brass wire, No. 26 gage, cut off to a length of 3 or 4 inches. The end is bent over with a pair of pliers and soldered with soft solder.

One of the prime necessities in examining a case of mouth infection is a good series of x-ray plates. Plates should be made with a hard tube to show the conditions in the roots of the teeth, and other plates should be made with the soft tube to differen-

tiate the softened areas in the alveolar process that the hard tube does not clearly define. This is especially valuable when there is systemic disturbance associated with nervous depression. In the case of impacted teeth such a course of procedure is invaluable, as the hard tube will clearly show the condition of the tooth, while the soft tube will give the condition of the surrounding membrane and bony processes. Whenever impacted teeth are found the impaction should be removed. And when all of these points have been given due consideration we can hope to treat the pockets of infection around the teeth with a fair prospect of success.

The specific treatment of mouth infection will now be discussed. The pockets should be carefully explored for deposits of tartar usually found upon the roots below the gums. The removal of this tartar is absolutely essential for a cure, just as it is necessary to remove a splinter before the wound occasioned by it will heal. So successful is this local treatment when carefully performed that many dentists claim that it is the only procedure necessary for a cure, unmindful of the fact that sometimes these pockets around the teeth occur where no calcareous scale is discoverable. Valuable and necessary as it is that the scale should be thoroughly removed, such dentists sometimes burrow so ruthlessly around the roots of teeth in their efforts to find tartar that they do more harm than good, since their well-meant efforts often result in ripping away much good tooth attachment and occasion laceration of the blood-vessels at the tip of the roots, causing the destruction of the pulps that otherwise might have been saved. Thoroughness should always be commended, but thoroughness that results in the loss of a tooth that more gentle means could have saved is certainly ill-advised. Sets of instruments have been devised for scaling the roots of infected teeth that are so complicated and require such special knowledge that their inventors peddle them around and persuade dentists to loan them patients in order to demonstrate the efficacy of their treatment, and these patients are charged large fees that are divided between the instrument demonstrator and the dentist providing the patient. This practice is certainly unprofessional

in its lack of frankness. A patient has every right to know to whom he is paying his money, and any indirection on this subject is apt to react upon the candor and honesty that is the fundamental basis of the professional relations of doctor and patient. These dentists in claiming that local scraping will cure all pyorrhea pockets are obviously wrong, but careful curetting alleviates so large a proportion of cases that by the laity their claims seem substantiated.



Fig. 28.—Yunger scalers.

There are many simple and effective sets of instruments made for scaling tartar. The Yunger instruments (Fig. 28) have given excellent results, as also have the Logan-Buckley instruments (Fig. 29) and Smith's (Fig. 30). As a matter of fact, it is not the scalers that are so valuable as the man behind the scaler.

Tartar Solvent.—Prior to 1900 there was nothing that would soften tartar without softening the tooth as well. The agonies, sometimes useless, that patients went through in having tartar

removed from the roots of the teeth were unspeakable, and as patient and dentist in this treatment, the author speaks feelingly. When, however, the author discovered, through a series of experiments, that a 20 per cent. aqueous solution of hydrogen ammonium fluorid with 10 per cent. free hydrofluoric acid would

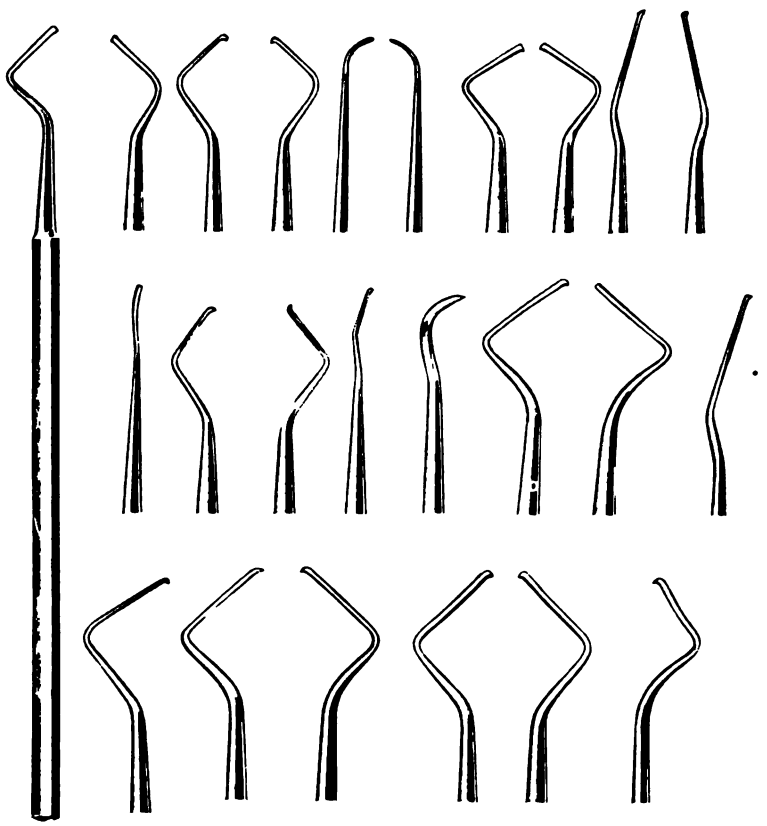

Fig. 29.—Logan-Buckley scalers.

soften the bond between the tartar and tooth without harming the tooth, the necessity for such heroic scraping passed away. This mixture, according to tests made by Dr. A. P. Hitchens, has a germicidal strength more than five times that of c. p. carbolic acid and, in addition to dissolving the tartar bond and

minute calcareous scales, it also stimulates the reattachment of the gum to the root.



Fig. 30.—Smith scalers.

The local treatment of the infected pockets around the teeth is, therefore, as follows: The obvious lumps of tartar should be removed without laceration, and then the bifluorid mixture should be gently flowed around the neck of each tooth and into

each infected pocket. If there is intense inflammation of the gums, the solution should at first be diluted with an equal quantity of water. In acute inflammation the first two or three weekly applications of the undiluted mixture cause intense pain, After the diluted mixture has been applied at weekly interva. two or three times, and great care observed in daily mouth hygienes the strong undiluted mixture can be used with comfort and ad-

Fig. 31.—Syringe for application of bifluorid of ammonium comp. The bulb is soft rubber, the barrel celluloid, and the needle is a platinum tube capable of being bent in any direction.

vantage, great care being taken not to force it into the tissues, especially into the young granulations that are forming at the bottom of the pockets. This solution should be applied with a platinum-pointed syringe with a celluloid barrel and a rubber bulb (Fig. 31). The solution vigorously attacks glass, and therefore such a syringe as described must be used. The gums inside and out should be protected by napkins or cotton rolls,

and the solution gently injected around the necks of the teeth and within the pockets, the excess being wiped off with a napkin. The patient should be allowed to spit without rinsing the mouth, as the action of the saliva has a soothing and protecting effect on the gums. If the solution is allowed to dry on the gums it makes a burn not unlike that of pure carbolic acid. Where the pocket extends along the tooth deep into the gums, it is sometimes good practice to pack cotton between the root and the gum and then soak it with the pure solution. This is not a painful procedure if properly done, and the next day the cotton can be removed, thereby exposing the root to the bottom of the pocket, when any remaining specks of tartar can be readily removed.

The methods just described will, in a majority of cases, be sufficient to bring about a cure of mouth infection, but sometimes recovery is slow or the general symptoms may indicate that the mouth infection has infected other portions of the body beyond the reach of ordinary local surgery or local therapeutic treatment. In such cases it is obvious that a complete cure requires the elimination not only of the mouth infection, but of all of this same infection from every portion of the body. This is what vaccine treatment is supposed to bring about. Therefore this subject will be treated in the following chapter.

CHAPTER V

VACCINES IN THE TREATMENT OF MOUTH INFECTION

Theory of Vaccination.—Bacterial vaccines are merely suspensions of dead bacteria in physiological saline solution. Vaccination is the injection of such suspensions for the purpose of stimulating or increasing the antagonistic forces of the body against the particular species of bacteria contained in the vaccine. Just what these antagonistic forces are and the exact manner in which they act have been subjects of the most careful investigation ever since the epoch-making work of Pasteur, scarcely three decades ago. As a result, certain substances or properties of the blood-serum in vaccinated persons or animals have become well-known facts. The antagonistic effects of these newly formed substances upon the bacteria have been demonstrated in test-tube experiments, and such reactions naturally suggest to a certain degree the train of events following an injection of bacterial vaccines into the tissues.

Unfortunately, however, our knowledge is still incomplete; the chemical and physical reactions that take place within the living body are so subtle that pure hypothesis must supply the connecting links between the known and the unknown. As new facts are disclosed, many of our theories must be modified accordingly, sometimes even discarded altogether. Our speculations are merely a temporary scaffolding from which to erect the solid structure.

Thus, in the matter of therapeutic inoculation, experience has taught us the essential points in the method of injection, and the regulation of dosage; experience has also shown us the great value of therapeutic inoculation. With regard, however, to the intimate mechanism by which these results are obtained, the current explanations offered must be regarded as working hypotheses and nothing more.

As just stated, vaccination consists in inserting dead disease germs into the body so that the blood and tissue cells may be stimulated to form a ferment that will destroy any invading germs of the same species. When this has been done, two important factors against the growth of these disease germs have been created: first, the ferment that will destroy them is actually present in the blood; second, the tissue cells have been impressed with the habit of making this specific ferment in the presence of these particular micro-organisms, so that in future if the tissue cells find themselves adjacent to these germs, they will more readily and effectively form the destroying ferment.

The injection of germs within the body so that the cells may form the special germ-destroying ferment is called active immunization because it stimulates the body to be alert in its defence against the presence of this germ. But where an animal has been injected with disease germs until its blood is full of the protective ferment, and this animal's blood is drawn off aseptically and the serum refined and injected into a patient purely for the benefit to be derived from the protective ferments that are in the serum, the procedure is called passive immunization because this immunization does not create the habit of ferment formation in the body cells of the person injected; it only provides a ferment that is known to be hostile to the germs with which the patient is infected. Active immunization may last for years, while passive immunization gives its protection for only a few weeks at most.

The method by which the body is stimulated to destroy and rid itself of invading infection has been investigated by Ehrlich, Metchnikoff, Wright, Besredka, and Vaughan with such inspired research and such astute patience that the basal principles of the theory of immunization seem fairly well established; and while there are differences in wording, the principles enumerated by each investigator co-ordinate so thoroughly that the doctrine will be treated as a whole, there not being sufficient space here to discuss the special minute differences of their individual teachings.

Any protein that invades the body parenterally—that is, otherwise than through the normal processes of the digestive

tract—is called *antigen*, whether it is in the form of bacteria, flower-pollen, horse-serum, or white of egg, etc. The ferment which destroys this substance and causes its elimination is composed of a combination of two substances called *complement* and *amboceptor*. Complement is always present in the blood in a practically fixed amount. The quantity cannot be markedly increased by any known means. Specific amboceptor does not exist until the body cells are stimulated to produce it. Its specificity is a marked characteristic. It is active only against its corresponding antigen. For instance, typhoid bacilli when they invade the tissues of the body act as an antigen. They stimulate the creation of a typhoid amboceptor that, uniting with the complement in the blood, forms a ferment which breaks up the typhoid germ into substances that are readily digestible by the blood and tissues. Vaughan, in his magnificent work, "Proteins and Split Products in Relation to Immunity and Disease," has shown that the first destructive action of a ferment on the antigen is to split it into a poison that is a common derivative of all proteins, called the *toxophore*, and a harmless split product called the *haptophore*, solely characteristic of the particular antigen from which it is derived. For instance, the toxophores of streptococci, goat-serum, or egg albumin are all toxicologically the same poison, and when set free in the body give rise to the same symptoms, but their respective haptophores, each non-toxic, are specific of each protein from which it is derived; and each haptophore stimulates by its presence the formation of the particular amboceptor as an increased defense against the invasion of its corresponding antigen.

Therefore, it is clear that the administration of proteins parenterally, whether serum or masses of bacteria, whether living or dead, may, under certain circumstances, be as potent in their action for good or evil as strychnin or aconite. By a beautiful series of experiments on animals Vaughan has shown that except where the disease is caused by the few bacteria similar to the diphtheria and tetanus germs, in that they secrete poisons as they grow, fever and death from infectious diseases result primarily from the breaking of protein bacterial masses into

the toxophore and the haptophore groups. Therefore, if the protein substance grows to a sufficient mass before the defensive ferments of the body arrest its growth, so much poison may be let loose upon the system that death results. If, however, the defensive ferment or amboceptor is present or is formed in sufficient quantity to stop the growth of the invading bacteria before enough protein is formed to produce a lethal dose of the toxophore, the poison is gradually and continuously destroyed and the patient recovers. Vaughan has shown that the fever of bacterial disease is not usually due to the growth of the germs, but to their destruction, and the letting loose of the toxophore. He has also shown that complete and effective digestion of a protein will thoroughly destroy the toxophore, while during the process the liberated haptophore will engender in the tissue cells a habit of readiness in the formation of the amboceptor, which thereafter will, whenever it meets it, destroy the particular protein that called it into being. After the formation of the amboceptor has ceased and the need for it has passed, there is ordinarily a tendency for it to disappear, the future defense being left to the educated tissue cells, although occasionally the amboceptor is not eliminated, but remains in large quantities in the blood.

Anaphylaxis.—The storing up of this amboceptor may work for good or ill, according to circumstances. If a certain protein, say horse-serum, is put into the body in small quantities and a large quantity of amboceptor is formed and stored up, a second dose of that protein may result in death by the sudden destructive action of the amboceptor, and the consequent pouring out of the toxophore, that reaches a lethal dose before it can be eliminated by the excretive and digestive processes of the body. Some animals are much more prone to store up the amboceptor in a dangerous manner than others. The guinea-pig is most prone to consistently do this. In man this propensity is, fortunately, rare. For instance, if a guinea-pig is injected with 1 c.c. of horse-serum, and at the end of ten to fifteen days is injected intravenously with another cubic centimeter of horse-serum, the guinea-pig will die of bronchial spasm. If,

however, the second dose consists of a different antigen, such as white of egg or goat-serum, etc., the amboceptor present is not effective, and death or even disturbing symptoms do not result. Moreover, if the second dose of horse-serum is given in three to five days, the amboceptor has not formed in sufficient quantity to let loose a lethal dose of poison, and from then on the doses can be given without the deadly symptoms that would develop if the second dose had been deferred for fifteen days. This state of being hypersensitive to a second dose is called sensitization or anaphylaxis. In man anaphylaxis is a remote though fatal possibility, and such a possibility is always present when a serum is administered for the first time in large quantities. How this sensitization occurs is not known, but that it does exist in some individuals as a natural idiosyncrasy is an established fact, and possibly fatal consequences can only be avoided when serums are administered by careful adherence to the precautionary routine in each case. If a small trial dose of a particular serum, say 0.05 c.c., is first given, and if at the end of an hour no itching or gasping results, the full dose can then be safely administered because the trial dose will have shown that no amboceptor characteristic of that particular serum is present. If, however, the small preliminary dose causes these symptoms, showing that the ferment is present, the result will be harmless, as there is not enough protein in 0.05 c.c. to develop a dangerous quantity of toxophore. If the patient is thus shown to be sensitized, and it is nevertheless essential that the serum be given, two or three trial doses of serum can be given at hourly intervals, so that the stored amboceptor will be gradually and safely eliminated, and then the full therapeutic dose of serum can be administered without any anaphylactic symptoms developing. The danger of bronchial spasms or fatal anaphylactic symptoms is only to be feared in the use of serums, and with these only when they are given in large first doses.

With vaccine the amount of protein represented by the dead bacteria is so small that there is practically no danger of any anaphylactic action other than a very occasional transient rash. 3,000,000,000 staphylococci or streptococci weigh only 1 milligram

or less;[1] 1,000,000,000 represents the maximum dose that is ordinarily given. Thus, if these micro-organisms were considered pure protein, which they are not by a large percentage, so appalling a dose as the 3,000,000,000 bacteria represent would contain much less protein than that found in 0.05 c.c. of horse-serum, which is the preliminary test suggested by Vaughan to be given to a patient to ascertain whether he can safely take antitoxin.[2]

The principal caution to be observed in vaccine treatment is to see to it that small doses are given at the start, and then cautiously increased, in order that there may be complete digestion, which will minimize if not entirely remove any depressing action of the liberated toxophore. After a dose of vaccine, if there is fever or depression lasting over a day, it is a sure sign that the interval between doses should be lengthened or the dose decreased, or both. Sometimes a patient may stand a given dose for five or six times at weekly intervals, and then suddenly show signs of nausea or cerebral or ocular congestion. These are symptoms that should never be disregarded. The vaccine should be stopped for two weeks or more, until the symptoms have entirely ceased, and then the minimum dose should be given again, and slowly raised, great care being taken to stop short at the first signs of the symptoms previously noted. It should also be taken as a cardinal principle not to increase the size of the dose while the patient is receiving a quantity that apparently is sufficient to cause good progress. In this respect patients vary in a remarkable degree. One patient will show a marked reaction to 10,000,000 streptococci, while another can easily accept 100,000,000.

The **preparation of vaccines** for use in vaccine therapy consists of taking one or more species of the infecting germs, growing these germs in suitable media, separating them according to species, combining them in a sterile salt solution according to their recognized dosage per cubic centimeter, and destroying their life but not their substance by heat or judiciously used antiseptics. The vaccine having been thus prepared in the

[1] Wilson and Dickson, "Journal of Hygiene," vol. xx, p. 49.
[2] "Protein Split Products," p. 471.

laboratory is then injected into healthy tissue, which is thereby stimulated to form the corresponding amboceptor. This amboceptor, combining with the complement, then dissolves or causes the digestion of the infecting germs. When the living germs of infection have overpowered a certain mass of tissue cells, as in the case of a pyorrhea pocket, these cells are unable to form the specific amboceptor necessary to sensitize the germs of infection so that the blood can dissolve them. If, however, these same germs are killed without destroying their protein substance and are injected into healthy tissue in judicious quantities, the healthy cells are stimulated and trained in the habit of producing the specific amboceptor. This amboceptor then joins with the complement and sensitizes or dissolves the infecting germs wherever it happens to meet them in the body. And this habit frequently lasts, so that the cells always respond to the stimulation of the specific individual infection, however small the stimulation may be. It is, however, evident that if the infecting germs are in large masses or depots surrounded by an inflammatory or protective wall, the ferment will not be effective, no matter how high its percentage is raised in the blood, since it cannot reach the germs growing within such a defensive mass. Therefore the vaccine treatment will prove of little value unless surgical means are used to remove or break up the inflammatory wall. For that reason every means possible should be used to mechanically remove these bacterial masses; and when that is accomplished the protective ferments in the blood induced by the vaccine will amply be able to destroy the remnants of infection and prevent such infection from traveling through the blood-current to other parts of the body and forming new spots or depots of infection.

Autogenous and Stock Vaccines.—There are two kinds of vaccine—autogenous and stock. The former is grown from germs obtained directly from the seat of disease; the latter from germs that have the same microscopic and cultural characteristics, but are obtained from various outside sources. The value of autogenous vaccine lies in the fact that the vaccine is derived from only those germs with which the body is already infected. Two

germs may show the same characteristics according to the microscopic analysis and growth on culture-media, and yet be essentially different in their pathologic reaction. It is clear, therefore, that the autogenous vaccine, scientifically made from the invading infection, must induce the production of the appropriate amboceptor, while the stock vaccine may or may not do so. The stock vaccine, however, has the advantage of being at once available, while the preparation of the autogenous vaccine takes from one to two weeks. Immediate availability is a great advantage in acute, rapidly spreading infections where prompt treatment is desirable; but in chronic inflammations, such as those around the gums, this haste is usually not needed. The stock vaccine prepared from germs similar in appearance and growth to the germs found in the infected area may produce the exact amboceptor, may merely produce a similar one which is partly effective, or it may produce an antibody that has no curative action at all on the disease to be combated. The stock vaccine has the great advantage that all the germs known to be generally associated with a disease can be incorporated in that vaccine, while material taken for an autogenous vaccine may not contain all of the important germs, some of which may lie too deep to be obtained, or may temporarily be missing in the spot of infection from which the parent germs of the vaccine are obtained.

While both vaccines have their advantages in the treatment of mouth infection, it is perhaps the more conservative treatment in ordinary cases to start with an autogenous vaccine whenever efficient laboratory facilities are at hand; but where these facilities are not available a stock vaccine, containing the principal germs usually associated with the pockets of infection, will prove valuable.

There are in the human mouth innumerable types of germs that are present and grow according to the food eaten and the condition of the saliva. In fact, there is hardly any germ that may not gain entrance to the mouth. Therefore, in obtaining the parent germs for an autogenous vaccine, if great care is not taken to obtain only those germs found deep within the pus

pocket, or within the actual walls of the inflamed region, an unlimited number of extraneous germs may be taken, which would give a vaccine not only of practically no value in restoring the infected region, but would subject the system to unnecessary strain. For instance, supposing some yeast or cheese germs were obtained from the remnants of bread or cheese left around the teeth, obviously a vaccine obtained from such accidental flora could not be expected to cure pyorrhea. In the same way there are doubtless many germs inhabiting the mouth that are, as one might say, accidental, and the incorporation of these in an autogenous vaccine may explain many of the failures of vaccine treatment. As before stated, only the germs deep within the infected pockets and within the infected tissues should be used, and the method by which these parent germs can be obtained to the exclusion of all others will now be discussed.

Obtaining the Parent Germs for a Vaccine.—When the infected area appears at the tip of a root where the pulp has died and the root canal has been filled, the root canal should be drilled out with a fine sterilized piano-wire drill, until the end of the root is nearly reached. The canal should then be sterilized with a hot electric silver sterilizer. When this has been done and the tooth has been carefully guarded with a napkin to prevent infection from the mouth, another sterilized drill should be passed down to the end of the canal and plunged through the tip into the infected area. This drill should then be carefully removed and streaked over blood-agar in such a way that the drill touches nothing in its passage from the tooth to the tube containing the blood-agar. The mouth of the tube should be passed through a flame both before and after removing the cotton plug, and the plug should be held between the second and third fingers of the hand holding the drill. The tube itself should always be held on its side, so that germs from the air cannot fall upon the nutrient material. The tube should be carefully labeled with the name of the patient, the date the material is obtained, and the name of the doctor obtaining it. A good way is to write directly on the tube with a small rapidly revolving engine stone. This will prevent the possibility of the label falling off and consequent

mistakes in the laboratory. The tube should then be sent to the laboratory, and the growths planted as soon as possible.

When the area of infection appears near the tip of a root in which the pulp is alive, the following method should be employed: The mucous membrane over the indurated spot should be anesthetized and a thin cautery (see Fig. 23) plunged down to the bone. An opening should then be made through the outer plate of the alveolar process by a sterilized bone-drill. At the end of two days the outer opening in the gum should be protected by a napkin, anesthetized, and cauterized again. The point of a small sterilized platinum-pointed glass syringe or platinum spear should then be inserted into the bony opening, and, with the same

Fig. 32.—Instrument for obtaining material for autogenous vaccine. The platinum spear is set in a ball-and-socket joint which is loosened or tightened by the ratchet at the end of the handle. Dotted lines indicate various positions the spear can assume. After material is obtained the instrument should be pointed downward and the socket loosened until the spear drops into a straight line with the instrument, then fastened into position by a turn of the screw-head, when the instrument can readily enter the test-tube.

care previously mentioned, a drop of bloody fluid extracted and transferred to the blood-agar tube. This material will unquestionably contain the bacteria from the infected area that have gathered and grown during the two intervening days, owing to the lowered vitality of the wounded tissue.

In taking a specimen from a pyorrhea pocket the following method should be used: The tooth should be protected from mouth contamination by a sterilized cotton roll, the neck of the tooth should then be washed with sterile cotton dipped in sterile salt solution so as to remove outside bacteria as much as possible, and the mouth of the pocket and adjacent tooth neck should then be slightly seared with the cautery. This can be done

without pain to the patient. Then a small cup-shaped spear of thin platinum (Fig. 32) should be heated to a cherry red and plunged to the bottom of the pocket. In this way a twofold purpose is at once accomplished—the extraneous germs near the edge are destroyed by cauterization and the deep-seated germs alone are collected on the thin platinum point, which has cooled before reaching them. This renders it possible to carry to the blood-agar only the germs presumably responsible for the disease in question. It must not be forgotten that pus is sometimes sterile and the true cause of infection probably lies within

Fig. 33.—Streptococcus.

the walls of the abscess, and it is, therefore, from that region alone that the material for the vaccine should be obtained.

In a study of over 300 cases the germs most frequently and consistently found were: streptococcus, present in 95 per cent. of the cases; Micrococcus catarrhalis and Bacillus influenzæ in about 80 per cent., appearing together; pneumococcus, staphylococcus, and diphtheroids in a percentage sufficiently consistent to indicate their probably great importance, and finally a scattering of Friedländer's bacillus, Micrococcus tetragenus, and a few unidentified germs.

All the germs found except the anaërobes and spore formers are used in the preparation of the vaccine. Staphylococci should show 300,000,000 to the cubic centimeter; streptococci, diphtheroids, pneumococci, Friedländer's bacillus, Micrococcus tetragenus, and unclassified bacteria, 50,000,000 each to the cubic centimeter. Where several strains of streptococci are found, they are usually combined so that all the strains mixed together will not give over 100,000,000 to the cubic centimeter. In ordinary cases of chronic pyorrhea the initial dose given is 0.1 of 1 c.c., and the dose is steadily raised according to the

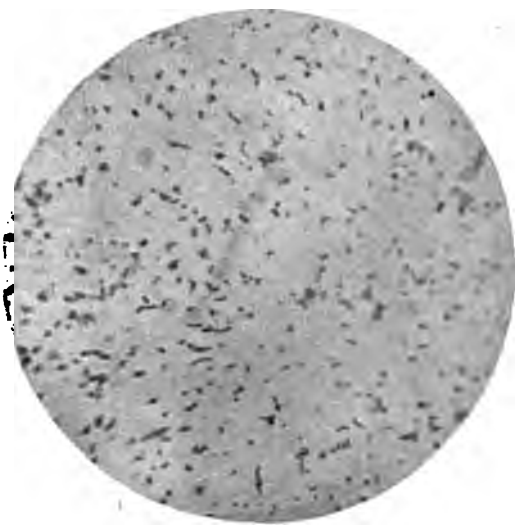

Fig. 34.—Bacillus influenzæ.

reaction at the site of inoculation, and the systemic response. If the patient shows exceptional frailness or the inflammation is unusually acute, or the blood-count shows either a marked leukocytosis or lymphocytosis, the initial dose should be very much smaller. These doses are generally given a week apart in the arm or leg. When the hemoglobin is low or there is poikilocytosis the dosage should be watched with great care.

On account of the consistency with which certain germs were found in gum infections it was considered that these were truly pathogenic and, therefore, valuable in the preparation of a stock

vaccine. These germs are staphylococcus—aureus and albus—streptococcus viridans, bacillus influenzæ, pneumococcus, micrococcus catarrhalis, and diphtheroids. These germs are so frequently present that their presence cannot be considered without significance; for it must not be forgotten that germs harmless to normal and healthy tissue may assume virulent pathologic characteristics when nourished in a mass of impoverished or broken-down cells. The germs used in this stock vaccine were obtained by mixing all the germs of similar types as they occurred in about 100 of my cases. For instance, all the different



Fig. 35.—Micrococcus catarrhalis.

strains of staphylococci were mixed together and the resultant staphylococcus was the one used in the vaccine. The same procedure was followed with the other types mentioned. This was done so that the various germs, when injected, would make ferments that would have a broad specific action on the various strains of bacteria to be combated. Such a vaccine is of special value to those practitioners who do not have a laboratory at hand for the preparation of autogenous vaccines. The further advantage of this stock vaccine lies in the fact that it can be sensitized, if desired, with the sensitized serum of a goat, which

will make it possible to give it in much larger doses than would be feasible with the ordinary autogenous vaccines.

Sensitized Vaccine.—If a sensitized vaccine is required, the vaccine should be first made in the ordinary way, and given in large doses to a goat until the blood of the goat is surcharged with the corresponding amboceptors. Then the goat is bled and its serum containing the amboceptors is allowed to remain in



Fig. 36.—Pneumococcus capsulatus. This germ when it infects the lungs and causes pneumonia results in a frightful mortality owing to the mucilaginous capsule that surrounds it. This capsule is particularly well shown on the three organisms in lower portion of the plate. In one case material taken from a pus-pocket around a tooth contained 80 per cent. of this micro-organism. After vaccine treatment the gums healed promptly, and repeated examinations during a period of three years failed to find this germ anywhere in the tissues around the teeth.

contact with the bacteria for twenty-four hours. The material is then centrifuged and the bacteria are washed with a sterile salt solution until all the free serum has been removed. The germs are then counted and mixed in the proper proportions for the vaccine. In the use of the sensitized stock vaccine the same digestion takes place in the body as with the ordinary vaccines, except that the digestion is more rapid and complete, since

the amboceptor obtained from the goat is already joined to the germs. Thus the protein poison is supposed to be completely destroyed, leaving the harmless protein products to increase the percentage of the therapeutic amboceptor in the blood.

As before stated, in giving vaccines, it must not be forgotten that a dose that is borne with ease for a number of times in succession may suddenly cause a severe reaction. When this is the case the same procedure should be followed as though the reaction came from an increased dose. Why this occurs is not known, but it is possible and probable that when the amboceptor in the blood rises to an effective height it suddenly successfully attacks masses of infection heretofore resistant, and thus the body has thrown upon it not only the split products of germs contained in the vaccine but also all the protein substance from the germs destroyed in the body. An interesting symptom is the occasional persistance of the lump or induration which forms at the point of injection. It appears that this can be due only to a lack of digestion and absorption of the bacterial bodies injected. So long as the induration markedly persists we have an indication that the potentialities of the vaccine injection have not been exhausted. Therefore, under these conditions, further injections may be temporarily withheld or smaller doses given, while absorption in the seat of induration may be stimulated by massage.

If there is a tendency to the rapid formation of creamy tartar deposits on the teeth prior to the vaccine treatment, it will be noted that as the antibodies are formed and the gums show signs of healing, the tartar will be deposited much less rapidly, and the tartar deposited is of a much more solid and removable nature, and does not tend to burrow under the gum margins. This change in the deposition of tartar I have come to consider as a distinct symptom of the successful progress of the vaccine inoculation.

Allen[1] speaks of the value of citric acid in 30-grain doses, three times a day, for the purpose of softening the lymph wall around the foci of infection by reducing the coagulating power

[1] "Vaccine Therapy and Opsonic Treatment," p. 126 (Blakiston).

of the blood. I have found the treatment of service, but give it in the form of 1 ounce of lemon juice three times a day, which is the equivalent of about 34 grains of citric acid for each dose.

When a pus pocket shows signs of sudden inflammation during treatment, it is always wise to open it surgically, drilling along the root to be sure that there is no back pressure of pus and that the antibodies have full opportunity to enter the seat of infection. For, above all things, it should be remembered that vaccine treatment can be successful only when accompanied by judicious local treatment of a surgical and therapeutic character.

When there is active tuberculosis, vaccine, in my experience, should be avoided, or, if given, it should be given with extreme caution. When there is a history of active tuberculosis that has healed, any cough or acute inflammation in the joints developing during the vaccine treatment should be looked upon as a danger signal. When the glands suddenly become enlarged and the clinical thermometer shows a rise in the evening to 100° F., or a rash appears suddenly over the nose and upper cheek bones, the vaccine should be stopped altogether for a considerable period, and if it is recommenced, a dose of not over 1,000,000 or 2,000,000 germs should be given at the start, and the daily temperature carefully noted as a guide. These complications are rare, fortunately, but nevertheless should always be recognized at their first appearance.

Dosage.—While there is no one infallible guide to the dosage of vaccine any more than there is to most of the medicines generally given, the blood-count as a gage of the patient's general tendency has proved of value, especially in the case where the patient is suffering from some acute disease which would call for especial caution, such as endocarditis, Bright's disease, or secondary anemia. Usually when the hemoglobin and red cells are constant the dose can be maintained or even increased; but while this usually has been a valuable guide, it has not always proved reliable, since there have been exceptional cases where the hemoglobin and red cells have steadily risen under treatment toward normal, and the white cells have been in the neighborhood of 7000 or 8000, and yet the patient has had a severe re-

action that came unexpectedly and necessitated a cessation in the treatment for a week or two. Cases of leukocytosis of an unusual nature may develop, that for the time being certainly call for caution. Leukopenia is a symptom that calls for even greater care in dosage than leukocytosis. I am convinced that immunization with small doses is more effective and rapid than that obtained by larger doses, and under these small doses patients hardly ever experience anything but a passing discomfort of a few hours.

A patient came to me with a hemoglobin of 30 per cent., red cells 3,616,000, white cells 4500, with microcytes, macrocytes, and poikilocytes. The patient was so weak that she could hardly walk. I extracted three roots and put her mouth under proper cleansing, and in five days her hemoglobin rose to 37 per cent., the macrocytes, microcytes, and poikilocytes disappeared, and the red cells began to accept the stain in a more normal manner. She was advised to take 3 raw eggs three times a day before meals, and the vaccine, composed of 1 diphtheroid, 1 pigmented streptococcus, and 1 non-hemolytic streptococcus, was given once a week. For a while improvement hung fire. After each dose of vaccine the hemoglobin would drop during two days through a range of 3 or 4 points, and then it would slowly climb up a little higher than at the start, so that gradually the hemoglobin reached 50 or more; the red cells rose to over 4,000,000 and the leukocytes to 9000 or 10,000. The patient's eyes lost their yellow cast and, from being hardly able to walk, she steadily increased in strength so that she felt better than she had in years. In this case, without the blood-count as a guide, the vaccine might have resulted in disaster.

In giving vaccine we must always be on our guard against the possibility of a subchronic infection becoming acute. The onset of such a condition may be shown by reduced heart pressure, nausea, congestion of eyes and forehead, or excessive local inflammatory reactions in the glands and joints.

Vaccines and Osteoarthritis.—Two cases of pronounced osteoarthritis evidently caused by mouth infection will now be given. The first was that of a man who had been suffering

for three years with rapidly progressing arthritis deformans, associated with hardening of the arteries. He was just able to walk with the aid of two canes. He came to me as a last resort for a possible slight relief. I found three necrotic teeth which I extracted. There were numerous live infected pulps that were removed and the canals antiseptically filled. The pockets of infection were invariably associated with loose, painful teeth. The pockets of infection were treated surgically, a scientific mouth hygiene was instituted (see Chapter II), the pockets were syringed with bifluorid of ammonium, and the patient cautiously given autogenous vaccine once a week. At the end of the fourth week he took off his iron boot and was able to walk with but one cane. He soon was able to bend his knees and cross his legs, which before had been impossible. Before long he walked from the station to my office, a distance of half a mile, and finally, in about six weeks, was able to walk a short distance without the cane. In the meantime the pockets of infection disappeared, and the teeth tightened to the point where mastication was comfortable and effective. During the administration of the vaccine he had no reaction whatever, until finally after the twelfth administration the erythrocytes, hemoglobin, and leukocytes suddenly began to drop. The vaccine was at once stopped and he was dismissed, being put on a low protein diet and being warned to keep up the prescribed mouth hygiene. He continued to improve, but in the course of a year carelessness in mouth hygiene caused a reinfection, and at the same time brain symptoms due to hardening of the arteries set in, so that he was finally confined to his chair through mental inertia. The treatment was renewed, and in the course of a year he made a satisfactory recovery as far as his joints and inflammatory symptoms were concerned.

The other case was one to which I was called in consultation. This patient, a man aged sixty-seven, was unable to move himself about without excessive pain in practically all of his muscles and joints. There were three necrotic teeth and pockets of infection about the other teeth. The necrotic teeth were extracted, and an autogenous vaccine made from the infected

pockets. He was treated as has been described in this chapter. He came from the hosptial to my office just four times, a week apart. The first two times he came in the ambulance, the third and fourth times in the trolley cars, and walked with little difficulty, and then he insisted that he was cured and that he was going to his home in West Virginia. I told him that he was foolish, that he was not cured, but still he insisted and went, and, much to my surprise, he appears to have been right, for he kept on improving and now gets in and out of the bath-tub and is in every way normal, so his son, who is a doctor, tells me. He took the vaccine with him and received weekly doses for a period of four months. His leukocytes when he entered the hospital were 15,600, and in two months they had dropped to 9400, where they remained.

The discovery by Barrett and Smith of the ameba in the pyorrhea pocket was considered most important as presenting the possible cause of mouth infection, and consequently ipecac and its alkaloid, emetin, have been given in numerous instances as a possible specific in this disease. I have used emetin, ⅓ grain, administered hypodermically in the arm or back for ten successive days during the treatment of mouth infection, but have no reason to believe that it is of great value. I have also used it in local applications, but have felt that in this respect it is less valuable than the bifluorid ammonium comp. This would indicate that the ameba is not the specific cause of mouth infection. In my opinion, no single drug or vaccine can eliminate mouth infection when it is once intrenched. It can only be cured by the judicious dentist, who must determine just what surgical and therapeutic procedures will be effective. Any specific curative claim for surgery, vaccine, or drugs alone will certainly retard, not advance, the cure of mouth infection.

In closing this chapter I would emphasize the necessity for a complete preliminary study of the patient by a competent physician who will diagnose, as well as may be, the condition of all the organs of the body, so that when the vaccine is given, this diagnosis may be borne in mind and the dosage modified accordingly.

CHAPTER VI

TREATMENT OF ROOT CANALS

EXCISION OF INFECTED OR NECROTIC ROOTS

Alveolar Abscess.—One of the most important causes of mouth infection is the alveolar abscess, due to deterioration of the dental pulp which forms the tooth bone or dentin. The term "dental pulp" will be used to designate the mass of sensitive tissue within the tooth, that among the laity is generally designated as the tooth "nerve."

After a tooth has been erupted for a period of from eight to ten years the essential constructive work of the pulp may be said to have been finished. From then on it slowly shrinks within the bony walls which it still continues to gradually form, and on the slightest provocation accepts infection and calcic infiltration, so that from being a benefit it is a distinct burden and menace to the usefulness and health of the tooth. The chief source of nourishment of a developed tooth is found in the peridental membrane that envelops the root or roots, and this membrane is amply able to maintain the tooth in comfort and stability if there is no complication occasioned by infection and nerve irritation. If the pulp is a healthy, nourishing one, it is of unquestioned benefit to the tooth, but when it becomes infected and irritated so as to be a depressing burden, the sooner it is removed the better, leaving the healthy peridental membrane to fulfil the functions of maintenance and nutrition. But if through the infection of the pulp the peridental membrane also becomes irritated and infected, the tooth will become loose and in danger of being lost.

A comparatively small cavity in a tooth will allow infecting organisms to reach the pulp that may or may not repel the invasion, but when the soft decay itself reaches the pulp, so that

its removal causes an obvious exposure, the pulp must be removed and the root canals filled. Any other procedure is inexcusable. Many an alveolar abscess is derived from an infected pulp and will resist all treatment until the pulp is removed, and then the abscess will heal of itself. Many a loose tooth will refuse to yield to the treatment designed to tighten it until the living pulp is removed, and then it will rapidly become firm. Many times a double-rooted tooth apparently sound and undecayed has developed soreness, looseness, and supersensibility to heat and cold. A careful exploration will show that one of the roots has become infected at the tip by a peridental abscess, which has destroyed the blood circulation in the canal of the root, thereby rendering the pulp half-dead and half-alive—a menace not only to the welfare of the tooth and jaw, but to the health of the entire body. Therefore, when the pulp of a tooth is exposed through decay, or when there is excessive response to heat or cold, or when peridental inflammation is combined with looseness and there is no response to thermal change, the pulp should be removed and the canals sterilized and properly filled. Where, however, all the teeth become sensitive at once or are insensitive to thermal change, we must look for a systemic cause or an idiosyncrasy. Spinal irritation associated with osteoarthritis, lead- or mercury-poisoning, or even an onset of grip may cause a general type of irritation which will frequently depart with the subsidence of the systemic lesion. It must be remembered that some teeth are naturally insensitive, an idiosyncrasy occasionally found, and it would obviously be ill-advised to destroy the pulps in teeth that had the general characteristic of insensibility as their sole pathologic symptom. However, there will ordinarily be no difficulty in differentiating between the local and general disturbance, since with the local cause there will be great variations in the individual teeth, while with the idiosyncrasy or general cause all the teeth will be affected in practically the same manner.

Local Anesthesia.—In inducing local anesthesia the author has found the Farbwerke-Hoechst tablets of novocain-suprarenin to give the best results, the tablet marked E, containing 0.02 gm.

or $\frac{1}{3}$ grain of novocain with 0.00005 gram of suprarenin, being the one usually used. The best results are obtained by dissolving the tablet in 2 or even 4 c.c. of Ringer's solution, which makes a 1 or 0.5 per cent. solution. A sterile normal salt solution containing 0.7 per cent. chlorid of sodium has been used for this purpose in order that the percentage of salt injected should be the same as the salt in the blood-serum, and this has given good results, but the Ringer solution is less irritating to the tis-

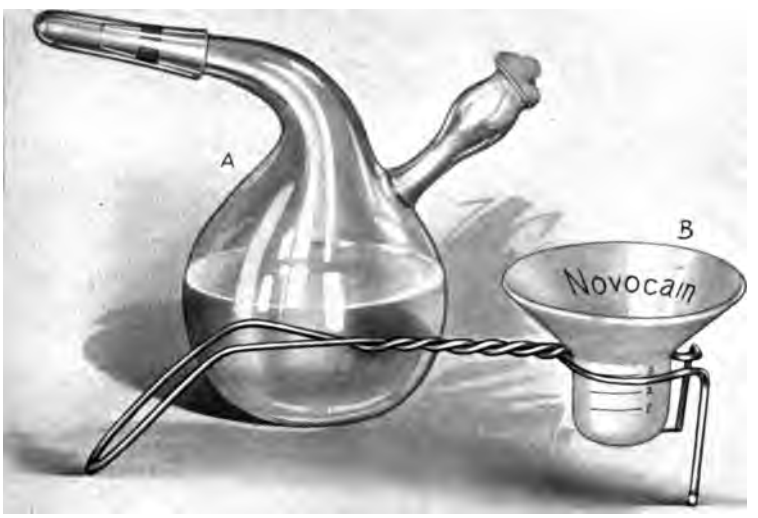

Fig. 37.—*A*, glass flask in which Ringer's solution can be sterilized; *B*, suitable casserole in which solution of novocain and suprarenin can be dissolved and finally sterilized by boiling.

sues and is productive of more rapid infiltration and anesthesia. This is no doubt largely due to the calcium chlorid which is present. The Ringer solution is made by dissolving 1 Ringer tablet in 10 c.c. of distilled water. It contains sodium chlorid 0.5 per cent., calcium chlorid 0.04 per cent., and potassium chlorid 0.02 per cent. Distilled water must be used for the solution, as the suprarenin is seriously affected by any alkaline traces. The flask recommended by Reithmüller, as shown in Fig. 37, *A*,

for holding the solution, is excellent and practical. The solution should be made up as described and sterilized for ten minutes, preferably in a small electric sterilizer. When it is cooled it should be put aside for use as needed. When the novocain-suprarenin solution is to be made, 2 or 4 c.c. of the solution should be poured out of the flask into the porcelain casserole recommended by Fischer, shown in Fig. 37, *B*, and raised to the boiling-point. While hot, one of the E tablets should be added to make either a 1 or ½ per cent. solution, and the mixture again raised to the boiling-point. It should then be drawn into a sterile syringe and injected at blood temperature into the tissues, the spot of injection being first touched with alcohol or tincture of iodin. The solution should remain clear. If it turns reddish or is flocculent it should be thrown away as unfit for use. Such changes usually occur because distilled water was not used for making up the mixture. The anesthetizing solution should be freshly prepared for each operation, as it quickly deteriorates. The great advantage in using the tablets lies in the fact that they will not deteriorate so long as they are kept dry and sealed, and also in the fact that as they contain a fixed amount of novocain and suprarenin there can be no chance of a mistake occurring in the amount of drug administered. The amount of drug is exactly known, and it is wise to over- rather than underdilute it. For instance, a ½ per cent. solution of novocain is better for gum or periosteum infiltration than a 1 per cent. solution, although some feel that a 1 or even 2 per cent. solution gives quicker and better results when used for infiltration around a nerve trunk. The author uses the 0.5 per cent. solution wherever possible, and always in frail or nephritic patients, or those having a tendency to arteriosclerosis. In such cases if an extra quantity of the anesthetizing solution is required, pure novocain can be added with the corresponding amount of Ringer's solution. It is particularly advisable not to increase the suprarenin above 0.00005 gm., the amount contained in one of the E tablets, for even if the entire amount of the solution is given it is only about one-sixth of the generally accepted maximum dose. Novocain has been given in doses up to 1 gram or 2 grams, and there-

fore need not be a source of especial care, since a twentieth or even a thirtieth of this amount is seldom needed in any one operation. This non-toxicity of novocain is a great blessing, and cocain should no longer be used for local anesthesia, for in using cocain one is handling a drug of such deadly possibilities that one never knows when one will have to fight desperately for the life of the patient. Ordinarily 0.1 or even 0.5 grain of cocain will be received hypodermically with perfect complacency, but occasionally a patient will show alarming symptoms of collapse under ridiculously minute doses. The author remembers an extreme case where a patient grew white, cold, and uncon-

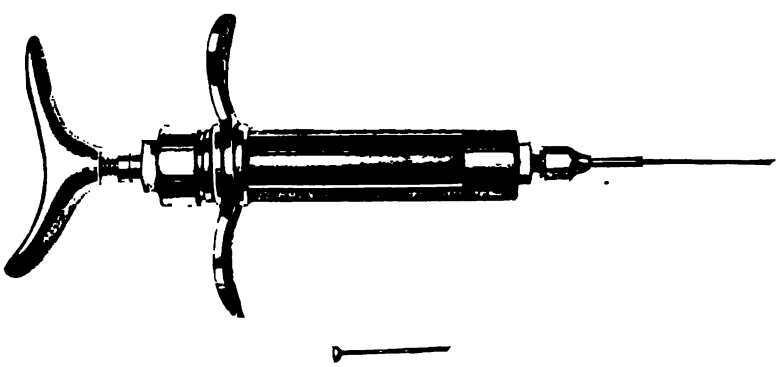

Fig. 38.—Local anesthetic syringe. It will hold 2 c.c. Its fittings are all metal or glass, making complete sterilization simple and easy.

scious from the administration of 0.013 grain of cocain, and only the promptest measures saved his life. Cocain is a veritable tiger in the jungle, always ready to spring upon the backs of those compelled to use it. Novocain shows no such tendency, and with ordinary caution is a perfectly safe drug.

Any good sterile hypodermic syringe of the type shown in Fig. 38 may be employed. Platinum needles are preferable to steel, as the latter rust and break easily. The short needle, 23 mm. in length, can be used for ordinary gum infiltration, while the long needle, 42 mm. in length, is all that is needed for nerve-blocking, a process which will be described later.

Gum Infiltration.—Ordinarily the pulp of any single-rooted tooth can be painlessly removed at the end of five or ten minutes after the injection of 0.02 gm. of novocain and 0.00005 gm. of suprarenin under the periosteum about the tip of the root. The point of the needle should be inserted beneath the periosteum at the labial aspect adjacent to the apical foramen of the root to be treated, and 2 c.c. of the solution slowly injected. The needle should then be withdrawn, and the same procedure should be carried out on the lingual side of the tooth. This, in a modified form, applies to all of the upper teeth. In injecting the lingual sides of the upper bicuspids the needle should be inserted in the peridental membrane at the neck of the tooth, since the tissues of the palate in this region are very sensitive to the stab of the needle. This same procedure also applies to the lower teeth as far back as the first molar, but as nerve-blocking is so wonderfully effective in the lower jaw it should always be given a trial before the infiltration method is used. Sometimes it is necessary to supplement one with the other.

Nerve-blocking consists of flooding a nerve trunk with an anesthetic so as to temporarily stop the passage of sensory impulses. The inferior dental nerve as it enters the inferior dental canal on the inside of the ramus of the jaw can be flooded with a solution containing 0.02 gm. of novovain and 0.00005 gm. of suprarenin, and the lower jaw and lip on that side rendered numb and insensitive for an hour or two. At the expiration of that time the sensibility of the jaw will be restored to its normal condition. If the nerve is flooded as it comes out of the mental foramen that region of the lower jaw between the second bicuspid and the median line will be deadened in a similar manner.

Nerve-blocking.—The method of nerve-blocking as applied to the inferior dental nerve before it enters the inferior dental canal is as follows: The syringe should be filled with 2 c.c. of Ringer's solution in which an E tablet has been dissolved. The solution should be blood temperature or a little warmer. The syringe should be fitted with the 42-mm. platinum needle. The gum should be painted with iodin where the injection is to be made, and then the finger of the left hand should feel for the

lingual edge of the inferior maxillary ramus (Figs. 39, 40), just back of the third molar. This edge, owing to the sudden widening of the jaw, lies in a line with the external cusps of the molars and is designated by *A*. The ridge *B*, marking the outer surface of the ramus, can be felt about $\frac{1}{3}$ inch exteriorly. When the inner edge has been carefully palpated, the point of the hypodermic needle should be inserted just along the bone in the direction of the line *A–C*, outside of the periosteum, about $\frac{1}{8}$ inch above the occlusal line of the lower molars. When entrance has been made and the surface of the ramus felt, the point of the needle should be passed along the surface of the bone for about $\frac{1}{4}$ inch, curving as shown by the dotted line, and keeping the direction of the puncture in the occlusal plane of the lower teeth. At this point, *D*, 0.2 c.c. should be slowly injected to deaden the lingual nerve. At this place the direction of the syringe should be changed, as in the arc *C–E*, so that finally the handle of the syringe will rest across the junction of the first bicuspid and canine on the other side of the jaw. This is necessary in order that the needle point may follow the curve of the ramus. The needle is then advanced in the line of *E–F* to a depth of 0.6 to 0.8 inch along the bone and the remaining contents of the syringe slowly discharged at *F*. The mandibular sulcus containing the inferior dental nerve is shown by *G*. The point of the needle should always lie away from the bone rather than toward it, and if there is any tendency for the needle to jamb or stick it should be withdrawn slightly and advanced in

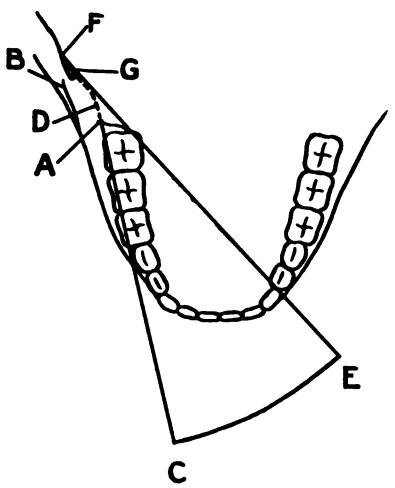

Fig. 39.—Diagrammatic illustration of directions and movements of hypodermic syringe during application of anesthetizing solution to the trunk of inferior dental nerve.

such a manner that an unobstructed entrance can be obtained. At the end of three minutes there should be a tingling and numbness of the lip, at the end of ten minutes the entire side of the face should have become anesthetized. The surgical work can then be commenced.

An injection just posterior to the tip of the first lower bicuspid will anesthetize the inferior dental nerve as it emerges, while an injection just back of the superior canine tip will have a similar effect on all of the teeth anterior to the point of the injection.

Fig. 40.—Lower jaw, showing the syringe and point of needle in final position when the local anesthetic is discharged for the purpose of infiltrating the inferior dental nerve as it enters the inferior dental canal.

In such cases the short needle is sufficient. An injection high up on the maxillary tuberosity between the second molar and the wisdom tooth will also anesthetize the three upper molars. For this the 42-mm. platinum needle is used. Those desiring fuller particulars on local anesthesia are referred to Fischer and Reithmüller's book, "Local Anesthesia in Dentistry."

Valuable as infiltration and nerve-blocking are, they do not always prove successful in completely taking away the sensibility of a badly inflamed pulp that is to be removed; but where a

tooth is to be extracted, or an alveolus is to be drilled, or a root end is to be amputated, the methods just mentioned are to be relied upon. If, therefore, the pulp is very much inflamed, the infiltration method will have to be supplemented by pressure anesthesia, a combination that gives very satisfactory results. Where the tooth is insensitive or quiescent, and the pulp is almost or entirely exposed, the local anesthetization by pressure alone with novocain-suprarenin seems to give the best results. In spite of every precaution there is occasionally pain and soreness for an hour or two after the infiltration or nerve-

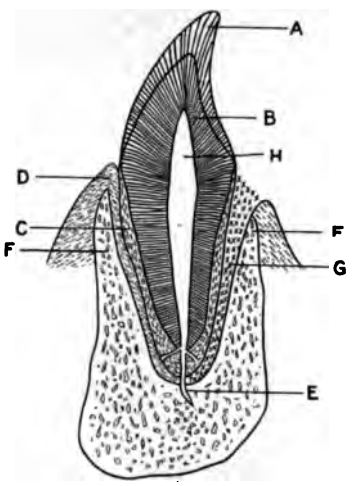

Fig. 41.—Central incisor, showing pyorrhea pocket.

blocking, while under ordinary conditions the pain occasioned by pressure anesthesia is at the time insignificant and usually involves no after-soreness.

Pressure Anesthesia.—The method of forcing novocain-suprarenin into the pulp of a tooth will now be described. In order that the complete technic may be given the case presented will be that of a tooth where the enamel has neither been injured by a blow nor decalcified by decay. In such cases the entrance to the pulp is correspondingly simplified.

Figure 41 represents a single-rooted tooth. *A* represents the enamel covering the tooth that normally extends to the gum;

B represents the dentin or tooth bone that has been formed by the nerve or pulp; *C* represents the cementum or bone-like structure that attaches the tooth to the surrounding peridental membrane, *D*. This membrane secures it to the alveolar process, *F*, which is the portion of the jaw-bone that supports the tooth. When the gum becomes infected by microbes the inflammatory exudate strips it away from the root and the intervening space becomes filled with pus and tartar, which is diagrammatically represented by the dots *G*. *E* represents the blood-vessels and nerve-fibers extending out from the region around the tip of the root. There are frequently several such openings. *H* represents

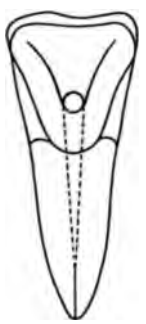

Fig. 42.—Labial aspect of Fig. 41. Circle shows correct spot for entrance of drill into pulp canal indicated by dotted lines.

Fig. 43.—Cross-section of tooth where pulp has been just touched by a sharp drill.

Fig. 44.—Method of squeezing novocain solution into the pulp by pressure upon a rubber plug.

the pulp. As before stated, the pocket of infection marked *G* is one of the common means by which the pulp can be infected without any cavity of decay in the tooth itself. Infection can even attack a pulp solely through germs floating in the blood.

Figure 42 represents the labial aspect of the tooth, the circle showing the spot where the opening should be made into the pulp chamber, which is shown by the dotted lines.

Figure 43 represents the cross-section of the same tooth showing the opening into the pulp. This opening should be made by a sharp, rapidly revolving inverted cone bur large enough not to plunge into the nerve. The bur should just slice the nerve, an

operation which can be done with very little pain to the patient. When the exposure of the pulp has been completed, one or two crystals of novocain wet with a little adrenalin, or about one-quarter of an E tablet powdered and moistened with water, should be placed in the cavity in direct contact with the exposed pulp. A pellet of soft unvulcanized rubber is then placed in the orifice of the tooth, and firm pressure is made upon it with any blunt instrument (Fig. 44) so that the rubber shall be driven well into the cavity, thus driving the novocain into the substance of the pulp. This will be a painful procedure in direct proportion as the circulation in the pulp has been destroyed by infection. If there is fairly good circulation in the pulp, the slightest pressure will squeeze in sufficient of the local anesthetic to completely deaden sensibility, inasmuch as any quantity that is forced in will be immediately distributed by the blood circulation throughout the entire pulp substance. If, however, the circulation is entirely lacking through excessive congestion or calcic infiltration, the local anesthetic must be forced into the pulp by pressure alone, and this causes much more pain. In general practice it is, therefore, wise under the conditions stated to give a firm, sharp punch on the rubber and maintain the pressure. Ordinarily there will be practically no pain, and if there is excessive congestion and pain cannot be avoided, the sooner it is over the better. In extreme cases if the pulp can only be anesthetized for a short distance, and there proves to be great sensibility underneath, the point of a hypodermic needle may be inserted into the deadened area of the pulp and the rest of the pulp injected with the anesthetic. This can usually be accomplished with very little pain, as the injection opens up the congested blood-vessels which the pressure alone had tended to compress. Before insertion, the point of the hypodermic needle should be ground off to an angle of 45 degrees, as the ordinary long point would necessarily run well into the sensitive area, which would, of course, defeat the entire purpose of the procedure.

There are two objections that can be raised against this method of pulp anesthesia: first, the pain, which, however, is not ordinarily more than passing discomfort; second, the possi-

bility of forcing infection through the tip of the root. The danger of spreading infection through the tip is ordinarily negligible, as infected pulps in a large percentage of cases have partly infected the area just outside the tip of the root by which a certain toleration may already have been established, and any infection forced out by the procedure just described will readily be taken care of by the blood-serum in the peridental membrane. At least that has been the author's experience. Of course, if a thoroughly putrescent pulp is subjected to this procedure, enough infection may be forced out to cause an abscess, the bacterial resistance of the parts being overwhelmed. But even in such a case it is astonishing how much infection the tissues at the tips of infected roots can accept without forming an acute abscess. If, however, an acute abscess does start, an aqueous 2 per cent. solution of carbolic acid should be forced through the tip of the root after the pulp has been removed, and if this fails to control the inflammation, the gum on the outside, opposite the tip, should be at once injected with novocain and an opening made through the alveolar plate so as to relieve the inflammatory pressure. This is a sure means of aborting an abscess. However, as before stated, when there is reason to suspect great resistance to the entrance of novocain, or a spreading of infection from pressure through the root foramen, the method described for injecting the periosteum at the tip of the tooth is to be preferred. In fact, if there is resistance to anesthesia by pressure, the infiltration or nerve-blocking method should be used as an auxiliary assistance.

Removal of the Dental Pulp.—When the pulp has been deadened we have usually about half an hour to remove it before it regains sensibility. A bur should thoroughly cut away the bony covering of the pulp, and then a fine piano-wire engine drill should be plunged to the bottom of the canal until it jams (Fig. 45). This will cut off the circulation and nerve connection with the tissues outside of the tooth, and will make it possible, by gradually using larger and larger drills, to thoroughly excavate not only the pulp itself but a large percentage of the decomposable tissue in the dentin, since the dentin lying next to the pulp

contains by far the greatest proportion of organic tissue. If, therefore, the canal is enlarged well into the surrounding dentin, about nine-tenths of all the soft organic material will have been removed from the tooth bone, and consequently there will be just so much less risk of later decomposition and discoloration (Fig. 46).

The greatest advantage of anesthesia over the old arsenic method of devitalization lies in the fact that with novocain anesthesia the dentin is not killed, and can be still nourished by the peridental membrane through the cells of the cementum and the interglobular spaces. After pulps have been removed

Fig. 45.—Showing the use of a fine canal drill in cutting off the tip of the pulp at the apical foramen.

Fig. 46.—Diagram of a typical single-rooted tooth with pulp canal reamed out for filling.

by such anesthesia in some rare cases sensibility of the dentin to the touch has been noticeable for a year or two. Such nerve sensations could only have come by way of the cementum and interglobular spaces. It is true that not over 5 or 6 undoubted cases of such a character have come to my notice during the last twenty-five years, but these are sufficient to convince me that a tooth without its pulp may be a living tooth nourished in all parts.

Tooth Nutrition by the Peridental Membrane.—Recent experiments on guinea-pigs by Dr. Gies, of Columbia University, show that a blue dye, injected into the abdomen of a guinea-pig, in a few days will be found to have stained the entire substance

of the teeth blue—enamel, cementum, dentin, pulp, peridental membrane, and gum. The saliva did not show the stain, so the enamel must have been stained from within through the dentin. This even occurred, although to a lesser degree, when the pulp was removed, which would seem to indicate that even the enamel can be reached by the blood-serum through the peridental membrane, cementum, and dentin. Further experiments on this subject are in progress.

The author emphasizes the possibility of a tooth deprived of its pulp being nourished, and he deplores the general tendency to call such a tooth dead. If a tooth becomes infected it may lose all gum attachments and die, but a tooth deprived of its pulp may still contain living cementum, dentin, and enamel, all of which can be nourished by the healthy peridental membrane. Such a tooth is very much alive, and should not be looked upon as dead, but as a living member, capable of performing its valuable functions.

The anesthesia method, since it allows any remaining pulp to regain sensibility, makes it possible to discover and properly treat minute canals that otherwise might have been overlooked if the tissue had been permanently destroyed by arsenic. This is particularly the case with multiple-rooted teeth, which point will be dwelt upon later.

Root Canal Preparation.—The pulp having been removed from the canal and the canal enlarged, the pulp chamber should then be as carefully sterilized as though the removed pulp had been putrescent. The failure to do this will cause an abscess that otherwise would not occur.

The Beutelrock drills, as shown in Fig. 47, are invaluable, especially where the canal is extremely small. Care should be taken to use the smallest drill first, and then follow up with the next size, until the canal is as large as desired. If the larger drills are used first, followed by the smaller, the point of the drill may become deviated from the true course of the canal, and an opening made in the side of the root, as in Fig. 48. Experience will teach the student that all root canals are not as large or self-evident as the canals shown in most of the published diagrams.



Fig. 47.—Beutelrock dental canal reamers.

They are very often infinitesimal, and show such incalculable variations, from large to minute diameters, that only the greatest care can give consistently good results.

Sets of valuable reamers and broaches are shown in Figs. 49 to 51.

Sterilization and Root Canal Filling.—The methods recommended for sterilizing the canal after the pulp has been removed are so numerous that only one or two will be described. When the canal has been opened and mechanically cleansed of its pulp a drop of half formalin and half tricresol, freshly mixed for each treatment, is flowed in. A small plug of cotton is then inserted and the orifice dried and sealed with a covering of soft phosphate of zinc cement. This formalin-tricresol antiseptic mixture was first recommended by Buckley. It is extremely effective, especially if used with a cement seal, as the heat of the body causes formaldehyd gas to be liberated and driven through all parts of the tooth, and even through the tip into the adjacent parts, causing a complete disinfection and deodorization of the tooth without discoloration. The author finds it better to mix formalin and tricresol fresh each time, as it has been his experience that the formalin and tricresol when mixed together in stock solution tend to discolor the tooth. When there is sensibility at the tip after the pulp has been removed, it is wise to allow the dressing to remain until such sensibility to pressure or mastication has completely disappeared, even it if takes two or three weeks. Within a week of the time that the final root-canal filling is to be inserted, the tooth should be opened and again treated with the formalin mixture in the same way. If the second treatment is accepted without sensibility developing during the first twenty-four hours, and all odor of putrescence is absent, the tooth should be filled as follows: A napkin, cotton roll, or a dam should be applied and the tooth dried with a warm air-blast, great care being taken to see that the canals are free from

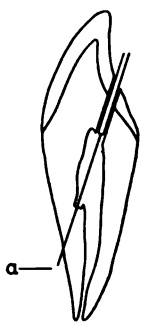

Fig. 48.—Diagram of an accident caused by using a large rigid drill to open the canal. The smaller drill found the pocket in the side of the canal and made a false opening at *a* instead of cleansing the true opening at the apical foramen.

moisture. Then thick, syrupy chlora-percha should be gently flowed to the tip of the canal and suitable gutta-percha cones

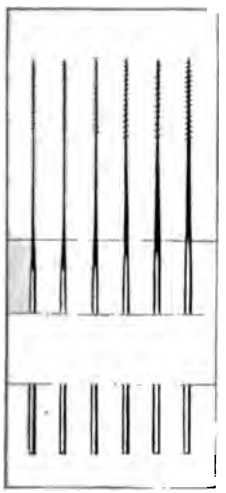

Fig. 49.—Barbed piano-wire broach, originally called the Donaldson nerve broach.



Fig. 50.—Kerr tapered canal reamers.

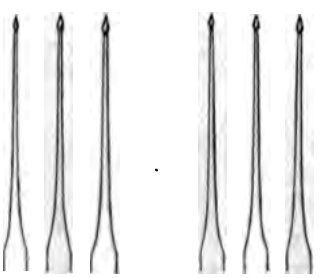

Fig. 51.—Gates-Glidden drills.

inserted, and with a pumping motion gently worked as far into the canal as possible, care being taken not to force the liquid gutta-percha beyond the foramen.

But when there is the slightest danger of forcing the liquid gutta-percha through the tip of the root it is advisable to fill the canal with eucalyptus oil and then insert a gutta-percha cone. When this has been allowed to remain in position for a minute it can be forced up into position near the canal foramen and the interstices will be filled with the gutta-percha dissolved in the oil. With this method there is the minimum danger of forcing the gutta-percha beyond the root canal, and therefore it is frequently to be preferred, as it is better to only partially fill a sterilized canal than to project the filling through the tip. The principal thing to remember is that the canal must be sterile when it is filled. When this procedure has been carried out the gutta-percha should be packed into place with a warm instrument and the exterior opening filled either with silicious cement, gutta-percha, or any other filling material that seems appropriate. When the pulp is dead and putrescent it is always wise to place a drop of the formalin-tricresol mixture within the tooth and seal it up with cement for at least twenty-four hours prior to working on the root canal or canals. This must not be done if the tooth is sensitive to pressure or the peridental membrane is actively inflamed. To do this will increase the trouble by imposing the expanding gas on the infected, irritated tissues. When there is sensibility to pressure, indicating the incipient formation of an abscess, a tooth should merely be opened with a drill and applications of iodin made to the surrounding gum. In a large majority of such cases the inflammation will subside in a few days to the point where the antiseptic mixture will be easily borne, and the procedure just described can be carried out. No root canal should ever be sealed up permanently so long as there is the slightest odor of putrescence. The application of formalin and tricresol will always be effective in removing such a condition.

Calahan Method.—When the root canal is very difficult to find, 50 per cent. aqueous sulphuric acid should be applied, and, if possible, sealed within the pulp chamber. On the following day the root canal will be shown by a small softened discolored spot, while the surrounding dentin or tooth bone will be white and clean. If, however, there is sensibility at the tip of the root

the pressure of the carbon dioxid liberated by the action of the sulphuric acid on the carbonate of calcium in the tooth will be too great to permit sealing the acid within the cavity. Under these circumstances it is sometimes of value to work the acid into the pulp chamber with a small piano-wire probe, afterward washing out the free acid with a bicarbonate of soda solution. This will ordinarily disclose the location of the root canal, which can then be treated in the usual way. It will be noted that it is recommended to work up into the root canal *as far as possible*, because it is not always possible to fill all the fine root canals to the tip. In fact, the root canals frequently have three or four openings on the root, some at the tip and some at the side, and those who claim that they always fill all the root canals to the tip prove themselves by such a statement ignorant of the difficulties to be encountered. Frequently when the pulp canal has become infiltrated with lime salts, observation will not locate it. Under these conditions a fine, sharp piano-wire explorer should be dug into the dentin all over the floor of the pulp chamber, and this, in many instances, will locate the pulp canal that otherwise would be completely masked by the white, soft, calcic infiltration. Such an opening can then be entered by a thin piano-wire drill. If, as before stated, the sensibility at the tip will not allow the formalin-tricresol mixture to be sealed within the tooth, it may be left open, protected only with a light padding of carbolic acid and cotton. Sometimes when the bacterial resistance of the patient is so low that it seems impossible to close the tooth without causing the chronic inflammation at the apex of the root to become acute, it will be found good practice to seal carbolic acid or tricresol and cotton in the root canal with cement, and then to immediately make an opening in the side of the tooth with a small drill into the pulp chamber to eliminate the possibility of gas pressure (Fig. 52). This will obviate any lack of drainage and will enable the tooth to slowly recuperate. Such an opening should always be made when acute sensibility of the tip makes it advisable to eliminate gas pressure. If, as sometimes happens, the inflammation persists in spite of this vent, and counter-irritation on the gum is unavail-

ing, electrolysis with the negative pole of a dry cell battery in series will be valuable in allaying the pain, as is described in Chapter III. If this does not prove completely effective, an opening should be made through the side of the alveolar plate, exposing the tip of the root. The opening at the tip of the root should be enlarged if necessary, and the root filled thoroughly through the tip. The root tip with the protruding gutta-percha should be smoothed with a bur. At the same time any bone found in the alveolar plate lacking its full vitality should be thoroughly bored away. This process will be more fully described later in the chapter.

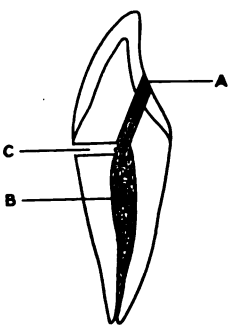

Fig. 52.—*A*, Cement seal; *B*, cotton antiseptic dressing; *C*, vent which allows drainage or the escape of gas that may not be endured by the inflamed tip.

Emetin.—When a root canal has been filled with gutta-percha and a sensibility develops, $\frac{1}{3}$ grain of emetin hydrochlorid, injected intramuscularly four or five days in succession, will often be of great service in allaying the symptoms. The patient should also be required to take 1 ounce of epsom salts. This latter by depleting the blood-serum will greatly assist in reducing any inflammatory tendency, while the emetin, possibly by sensitizing the germs at the tip of the inflamed root, will enable the blood-serum to more readily dispose of them. I mention this possibility because I think it a more probable theory than the supposition that the ameba could be responsible for such inflammatory areas, since such areas are usually cut off from the mouth, and it does not seem credible that the ameba could reach them through the blood-stream. It is also good practice to give calomel where there is an inflammatory tendency, as the liver is much more efficient in combating infection when it has been relieved of any engorgement that is likely to exist under such conditions.

Canal Variations.—In dealing with single-rooted teeth one sometimes finds that there are two or even three canals that

should be opened and mechanically cleansed. It sometimes happens that the root without any warning will curve sharply, forming a complete right angle, as in Fig. 53. Such a condition makes it all but impossible not to perforate the tooth at *A* in an attempt to cleanse the canal, and makes it mechanically quite out of the question to cleanse the canal beyond the sharp angle. Where it is possible to diagnose such a condition with the *x*-ray, some dentists recommend sealing up sulphuric acid in the tooth. This is supposed to burn the pulp sufficiently to permit of its being washed out with a solution of carbonate of soda, and the canal can then be filled with liquid gutta-percha or oxyphosphate of zinc. This procedure is more theoretically than practically possible. There is always the possibility that such a distortion exists, and there is absolutely no means but the *x*-ray for diagosing such a condition. It almost invariably happens, however, that under such conditions an apical abscess eventually develops and, therefore, if a tooth does not heal properly the *x*-ray should always be used, and will be an invaluable guide for operative procedure.

Fig. 53.—Diagrammatic illustration of a not infrequent condition at the tip of a root.

If this is so concerning single-rooted teeth, how much more so is it with multiple-rooted teeth showing abnormalities! One such case was that of an upper second bicuspid that had three roots when there is ordinarily but one, and three root canals, only one of which canals was found and filled. Before the days of *x*-rays how many such anomalies have escaped me and have spread infection, the shade of Æsculapius only knows. Another case was that of an upper central incisor that had two roots and two canals. The unfilled canal naturally continued to spread infection and the tooth eventually had to be extracted. When we consider molars any one of which may have only one large canal, bifurcated or not bifurcated, or may, by chance, have

four, five, or six canals, the man who says that in every instance he finds and fills all of these canals to the tips of the roots is so optimistic that he makes himself ridiculous. This same man, who claims to have such perfect technic in filling root canals, almost invariably claims that he never breaks off a probe or root canal drill during the process of canal excavation. Such an accident, though lamentable and to be avoided, will occur to the most skilful, and the man who never runs the risk of breaking off a delicate drill in a canal, of necessity, has not the courage to properly cleanse the canals. Our dental technic is too good and skilful to require evasions or mendacity as a protection. Better by far that the very occasional tip of a root should be amputated, or even a tooth extracted, than to condemn all teeth to a probable danger of infection through timidity in canal cleansing. The conscientious, frank dentist knows his unavoidable percentage of failures; he can only reduce the failures to a minimum by realizing and appreciating them, not by denying and ignoring them. He knows that central and lateral incisors and canines, upper and lower, nine hundred and ninety-nine times out of a thousand, have only one root canal, which is usually straight and can be successfully filled to the tip. He knows that the upper first bicuspid ordinarily has two canals, and these two canals can ordinarily be successfully filled. The upper second bicuspid and the lower first and second bicuspids ordinarily have one canal. Any of these teeth may have additional roots and canals, and any of these canals may turn suddenly, making complete filling impossible, and yet the dentist can only use judicious cutting and caution. To do otherwise would mean an incalculable waste of tooth structure and time. It would mean a great increase in the openings made through the sides of root canals into the gum; for when the root canals have been properly reamed out all extra cutting merely weakens the tooth and increases the danger of puncturing the cementum. In the same way the dentist knows that the upper and lower first molars ordinarily have three canals, but they may have only one or two, or they may have four or five. He is between Scylla and Charybdis; if there is only one and he hunts for more, he

uselessly sacrifices the tooth. If he finds three and thoroughness makes him rashly hunt for more, for the one time he succeeds in finding the canal he has a hundred failures, and, in reality, the fine hair-like canals ordinarily do not cause irritation that the peridental membrane cannot control. In exploring for root canals the dentist cannot do better than follow the technic of Flagg and his successors, which is about as follows: When a tooth is opened into the pulp chamber the roof of the pulp chamber should be completely removed and the floor burred until the body of the nerve is completely removed and the canal or canals are in plain view. Then at least he should use every effort to find all the canals that are ordinarily present. With single-rooted teeth there must be one canal at least; in reason, let him look carefully for more. Sometimes he will not be able to find even that one. In bicuspids it should be remembered that two canals are not uncommon, and he should see to it that the floor of the pulp chamber is thoroughly exposed, cleansed, and explored. After that let him fill the canals that are found and leave the rest. With the molars he should cut freely and thoroughly to expose to view the floor of the pulp chamber. With first molars let him expect three canals, and not be nonplussed if he finds four or five; neither let him condemn himself too harshly if careful exploration reveals only one or two, lest by too thorough searching he perforates the side of the canal into the gum outside and thus finds a few that do not exist. With second molars three canals are the rule, although they are often difficult to demonstrate. With third molars it is to be remembered that there may be one canal the size of a stick of Italian spaghetti, or there may be four, five, six, or seven of a hair-like quality, to discover which would require the "million magnifier eyes" so eloquently disclaimed by Mr. Samuel Weller. With some of these the skiagraph will only show that the tips have not been reached and will not reveal whether bone infection is or is not going to develop. If such infection should develop it will not be shown by the *x*-ray plate until six months or a year has passed. All the dentist can do is in every instance to follow the rules and do

his best, and not bore his fellow-workers with claims of perfection in technic.

In filling large, obvious canals it is wise to use oil of eucalyptus and a cone of gutta-percha. Oil of eucalyptus should be pumped in first, then the gutta-percha cone inserted and worked slowly up and down until it settles as near the bottom of the canal as possible. It should be allowed to soak up the excess eucalyptus for a minute or two, and then with a hot instrument pushed home and more gutta-percha added until the canal is filled. And each time the conscientious dentist does this, he prays that it has filled the canal to the cementum, and also that neither the cone nor the liquid gutta-percha has been forced through the tip. The cementum being actively alive will frequently satisfactorily close up an aseptic apical foramen if the gutta-percha does not extend beyond it into the soft tissues. The only way to be certain that the root canal is completely filled is to boldly push the gutta-percha through the tip, and then to smooth it off with a bur by going through the alveolus from the outside of the gum. The method of preparing and filling root canals just described almost invariably gives good clinical results, but when it fails and chronic inflammation at a root tip shows that the gutta-percha filling is not acting as a satisfactory protection, the tip should be excised or the root extracted. With the smaller, thread-like canals thin oxyphosphate of zinc makes an excellent filling, since it can readily be pumped into place with a hair-like broach, and if a little excess does escape through the root the excess is absorbed, although not without some pain. However, when the pain goes, there is seldom any bad after-result. When there is a distinct tendency for irritation to persist at the tips of the roots a very small portion of iodoform can be placed at the tip before the gutta-percha is inserted. Great caution should be observed in using iodoform in a front tooth, as when used in any quantity it causes a stain to develop that it is practically impossible to remove. Paraffin and other similar semiliquid materials have been used for filling root canals, but they are apt to be absorbed, leaving the canals unprotected.

Bleaching.—Before we leave the subject of root canal sterilization and filling it must not be forgotten that tooth discoloration may enter as a factor of considerable importance. This discoloration has to be viewed both from the hygienic as well as the cosmetic point of view. Tooth discoloration may come from purely chemical causes, such as amalgam salts, nitrate of silver, iodoform, or any of the essential oils commonly used in the treatment of root canals, or the discoloration may be due to pulp deterioration. This latter discoloration appears first as a faint yellow cloudiness, and as the pulp further loses its vitality and finally dies, this cloudiness may progressively change to a dark brown or a grayish black.

Discolorations due to a chemical or purely mechanical cause, while distressing, are not a pathologic danger sign; but discolorations caused by pulp infection and infiltration into the tooth substance are not only unsightly, but a menace to the general health of the patient. And yet it is not always an easy matter to decide which type of discoloration is presented to us. It may be a combination wherein the tooth has started to discolor through pulp deterioration, and has been assisted along its uncosmetic path by pulp-canal dressings such as iodoform or oil of cloves. Such chemical discolorations cannot be bleached by any known materials. When such a discoloration occurs the best bleacher is the bur or stone that cuts out the discolored tooth substance and makes room for a suitable porcelain or cement restoration. But where there is the possibility that the discoloration may also arise from previous pulp decomposition and infiltration throughout the tooth, the root canals should be carefully treated and the tips filled as just described. Thorough attempts at bleaching should then be inaugurated, whether they prove successful or not, for the process of restoring the natural color to a tooth discolored by pulp infection is accomplished by actually oxidizing and destroying the putrescent substance of the pulp that has permeated the tooth; and therefore, even if the bleaching process is not able to remove the chemical stain, it is nevertheless hygienically of the utmost value. For if the crown of a tooth blackened by the infiltration of pulp infection is merely

cut off and replaced by a suitable porcelain substitute, the infection in the root may and probably will continue to grow, because all the germ food on which the infection could subsist is still present, ready for the nourishment of any stray germs that may possibly have escaped the antiseptics, or may later obtain entrance through a defectively filled apical foramen.

Therefore, tooth discolorations that arise from the death of the pulp and the infiltration of the infected mass into the interstices of the tooth should not be tolerated. This discoloration is not merely unsightly, it is a source of deterioration that in time will actually undermine the stability and usefulness of the tooth, and the dentist who does not appreciate the danger is probably not thorough in his sterilization, and thus the slowly decomposing material will be sealed within the tooth substance, and the gas that is formed will slowly and surely drive the depressing bacterial toxins through all parts of the tooth and even out into the body at large. Thus the peridental membrane when attacked by actual infection from within is so weakened in its bacterial resistance that it readily accepts any infection that may be either floating in the blood-stream or attempting to gain an entrance at the gum margin.

The two bleaching agents most valuable in the treatment of discolored teeth are a 30 per cent. aqueous solution of peroxid of hydrogen and a saturated aqueous solution of oxalic acid. If the iron of the hemoglobin has darkened the tooth, as is indicated by the presence of the brown stain, it is wise to use the oxalic acid alternately with the peroxid, but if the tooth has a gray or black discoloration and has not been stained with amalgam or previously treated, peroxid alone will usually be able to permanently restore the tooth to its normal color.

The method of using these two bleaching agents is as follows: The root canal or canals should be sterilized with tricresol and formalin freshly mixed. Then one or two drops of 50 per cent. aqueous solution of sulphuric acid should be placed within the pulp cavity, where it should be allowed to remain for a few minutes. It should then be neutralized with a concentrated aqueous solution of bicarbonate of soda. This will cause the formation

of carbon dioxid at the further ramification of the dentin tubes, which will tend to sweep out any loose, decomposed material that may be present. The sulphuric acid is also a powerful germicide, and such an application seems to have no harmful effect if it is not repeated too often, and if it is not allowed to remain upon the outside surface of the enamel of the tooth. When the tooth has been sterilized and the loose discoloration has been removed from the pulp chamber and its environs by the mechanical means of the gas formation, and the tips of the canals have been thoroughly sealed with a pellet of gutta-percha, the actual bleaching may be attempted. But it must be remembered that it is just as necessary for the root under the gum to be bleached as it is for the tooth crown, if permanent results are to be secured; for any discoloration that is left anywhere within the tooth, especially within the pulp canal, will tend to become infiltrated throughout the entire organ. Therefore the tip of the root should be sealed, and as much of the canal as possible should be left open to the action of the bleaching agents. The best way to do this is to fill the canal completely with gutta-percha during one visit, and then on a later occasion, when the gutta-percha is absolutely hard, to drill it out almost to the apical foramen, leaving the tip completely sealed. It is particularly necessary for the tip to be sealed completely when bleaching is undertaken, for if the bleaching material is forced up through the tip into the gum an acute abscess is likely to be the result.

Let us recapitulate: The root canal has been opened mechanically, cleansed, and sterilized. It has been flooded with 50 per cent. sulphuric acid, washed out with bicarbonate of soda, and the end of the root has been sealed. When this has been done the root canal should be carefully dried and a twist of cotton wet with a saturated aqueous solution of oxalic acid should be inserted, and then a small electric cautery (see Fig. 23) should be heated to a point just below redness and plunged into the pulp cavity, vaporizing the oxalic acid solution. The cotton dressing should be removed when it is dry and the process repeated several times. Finally, the oxalic acid and cotton should be temporarily sealed tightly within the pulp chamber with cement

and the patient dismissed. The amount of acid used is so small that there is no danger even if the solution escapes into the mouth through a defective seal of the cavity. When the patient returns on the following day the same procedure should be carried out with the 30 per cent. peroxid of hydrogen solution. The peroxid is particularly effective as a bleacher when it is converted into steam within the pulp cavity, since the oxygen thus liberated is free atomic oxygen, which attacks the organic discoloration not merely as molecular oxygen would, but it attacks it with all the force that is usually expended by the atoms in uniting within the molecule. When the tooth has been steamed from within several times, cotton wet with peroxid should be sealed in the canal with cement, and then the outside of the tooth gone over with the hot instrument. This heat liberates the nascent oxygen under pressure and causes a sudden whitening of the tooth substance that is most satisfactory and effective. If, under these conditions, the apical foramen of the canal has not been carefully sealed, the oxygen escaping from the solution may cause an abscess by rupturing the tissues on the outside of the tooth. With oxalic acid the danger does not exist to such an extent. When this sealing and external ironing has been done several times, the solution can be sealed within the tooth for a week or more with the expectation that the heat of the body will slowly liberate the oxygen, causing a still further antiseptic and bleaching effect. At the end of each operation, prior to the final filling, the pulp canal should be flooded with hot water to wash out the soluble iron salts.

Sometimes when the peridental membrane is particularly sensitive the pressure of the gas through the tooth substance may cause an external irritation. This has happened very occasionally in my experience, and when it does occur it is wise to put a slight vent in the cement seal so as to temporarily relieve the pressure.

When stains occur on the outside of the enamel of a tooth with a living pulp the external steaming process, just described, can be effectively used on the enamel if the tooth is not over-sensitive to heat.

The details by which the mouth and lips are protected from injury or irritation by napkin or rubber-dam have not been dwelt upon, as this is a commonly understood dental procedure.

Root Amputation and x-Ray Diagnosis.—Let us now take up the question of root amputation, preserving a part of a tooth by excision either of the tip of the root, or in the case of molars, by removing the necrosed roots, leaving the healthy root or roots as a useful support for filling or crown.

Amputation of roots should be preceded by a careful *x*-ray study of the region involved. Emphasis is laid on the word *careful* as applying both to the method of taking the *x*-ray and to its interpretation in conjunction with the clinical facts. The darkened area at the tip of a root, as shown by an *x*-ray plate, may indicate absorption or the presence of chronic inflammation of the bone, or a thickened peridental membrane. The too clear differentiation of a root tip in the alveolus is just as significant of lost vitality, but as bones and roots vary in density, it is not always easy to differentiate and diagnose a case of this character. Therefore, when it comes to saying, by *x*-ray alone, whether a pyorrhea pocket is getting well and has ceased spreading infection, or is increasing so as to be a menace to the health of the patient, the *x*-ray man is helpless, and frequently makes himself ridiculous if he does not allow caution to temper his enthusiasm.

The following is a case in point: A young married woman had been under treatment for gum infection and loose teeth during a period of six years, and had showed marked improvement. The gums had healed, the pus had ceased to flow, and the teeth had tightened. There was unquestionably progressive improvement. Many of the teeth that originally were so loose that they could have been pulled out by the fingers had become firm, the gums around them had assumed a healthy color, and the pockets of infection had disappeared. There were two or three teeth that did not show the improvement of the rest, but the mouth as a whole was becoming comfortable and healthy. In the meanwhile the patient suffered from enteroptosis and went to her physician, who sent her to a prominent *x*-ray man for an

examination of her bowel convolutions. Incidentally, he took an x-ray of her teeth and reported to her physician that he did not find a single healthy tooth in the upper jaw and only three in the lower. This report was enthusiastically received by her physician, who said that the x-ray report was one of the most beautiful and complete he had ever known, and complimented the x-ray specialist very highly on the brilliancy of his report. As a matter of fact, all of the teeth except three were in a fairly healthy condition and certainly were not causing the general systemic infection. Two of these three still had a good chance of healing as was later demonstrated. This was a case where it was impossible to interpret the x-ray of the mouth correctly without knowing the clinical facts and history of the case.

Perhaps, then, it might be wise to say that we should learn all that we can by the x-ray plate, but not rely too much on the finality of its data, for many a surgeon knows that two ends of a bone will make a thoroughly practical union even though the x-ray would conclusively demonstrate that the dressing should be removed and the patient subjected to the agony of an attempt to get a juxtaposition that would be only theoretically an improvement. The author does not wish to be interpreted as discrediting the x-ray; he discredits the overzealous interpretations of some x-ray men who claim that all other methods of diagnosis are to be subservient to their valuable but, in reality, limited scope of vision.

The method of procedure in the amputation of the necrotic tip of a root follows, Figs. 54, 55 representing any typical single-rooted tooth:

A 2-c.c. hypodermic syringe is filled with a 0.5 per cent. solution of novocain and suprarenin. Iodin should be applied over the places to be punctured. The lip is retracted and the tip of the needle is inserted beneath the periosteum near the tip of the root on the labial side. The 2 c.c. are then injected and the same procedure is carried out in the lingual surface. A 1 per cent. solution may be used and half the amount injected on each side if desired. If this is done properly, at the end of five minutes the surrounding parts should be white and insensitive.

Then an opening is made through the gum either with a cautery or knife, and the dead bone and tip of the root thoroughly removed with bone drills (Fig. 56). The suprarenin makes this a practically bloodless operation. The root canal should then be sterilized, dried, and filled with a gutta-percha cone, as previously described, and the projecting end should be made smooth either with a bur or hot instrument. Some prefer packing the pocket thus made with subnitrate of bismuth, while others allow a blood-clot to form and then stitch the periosteum and gum in place, but the author usually finds that it is better to pack

Fig. 54.—*A*, Cross-section of tooth; *B*, the lip; *C*, abscess in the bone at the tip of the root.

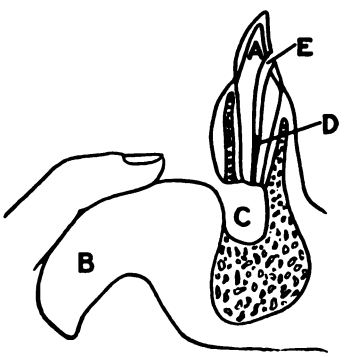

Fig. 55.—Operation of root amputation completed: *A*, Tooth; *B*, lip; *C*, excised abscess area; *D*, gutta-percha root canal filling; *E*, unfilled portion of root canal.

the wound with iodoform gauze, and keep it open by repeated dressings until granulations cover the bottom of the wound, and show conclusively that healing is progressing satisfactorily. To treat such a wound aseptically seems absurd, for to make such a wound surely aseptic would mean such an extension of the surgical area that much valuable tissue would be lost and many teeth sacrificed. Therefore, since it is hardly possible to closely differentiate between dead bone and living bone with a bur, it seems best to keep the wound open until it is apparent that all the bone is healing properly, so that all parts that do

not heal can be curetted until they do heal. The mouth of the wound should be kept open until granulations cause the cavity to be shallower than it is wide. Then healing will ordinarily progress to a satisfactory termination. This procedure applies to all of the single-rooted teeth and the upper first bicuspid, but when we come to the molar teeth a different procedure is usually necessary.

Root Excision.—When the buccal root or roots of the first or second upper molars have become necrotic at the tip, the same procedure can be used as has just been recommended for the

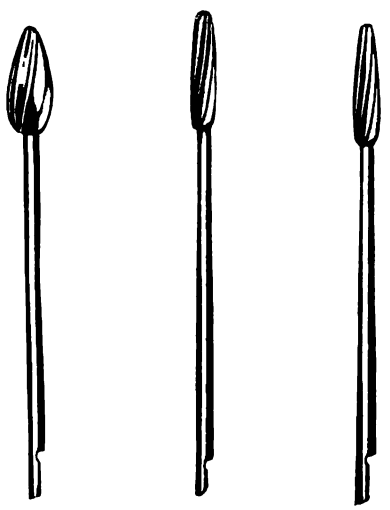

Fig. 56.—Bone drills.

single-rooted teeth, but when the palatal root of the upper first or second molars has become necrotic at the tip, complete excision of the root from the rest of the tooth is usually to be preferred. It has been the author's clinical experience that necrosis or absorption at the tip of the palatal root is usually associated with a pyorrhea pocket at the bifurcation of the roots.

For instance, let us suppose Fig. 57 represents a superior first molar. *A* represents a pocket of infection in the bifurcation of the roots beneath the gum which extends its influence to *B*, which represents a necrotic tip of the palatal root; *F* represents

the crown of the tooth; *C* represents the palatal root; *D* and *E*, the buccal roots. Such a condition usually exists when the pulp has either completely died, or when it has become so infected that the living pulp is causing an abscess at one of the root tips, usually the palatal. Volumes have been written about the instruments that can curet and cure such a spot as *A* represents, surrounded as it is by three roots, but any conscientious experienced dentist knows that this is a more theoretic than a practical possibility. Curetting and stimulating antiseptics may quiet and mask such an abscess, but in ninety times out of a hundred no treatment will cure it so that there will be reattachment of the membranes to the root; and as such an abscess may result in grave systemic complications, any such

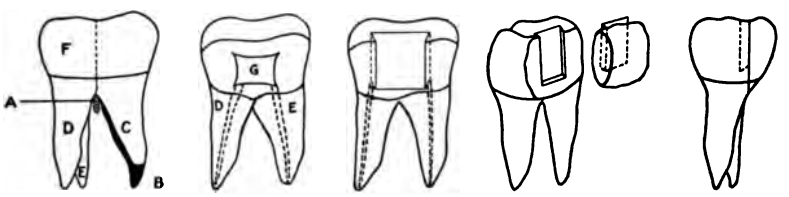

Fig. 57. Fig. 58. Fig. 59. Fig. 60. Fig. 61. Fig. 62.

Figs. 57–62.—Progressive steps by which a necrotic palatal root may be excised from the sound portion of the tooth, and the steps by which the remaining healthy portion of the tooth may be restored to comfort and usefulness.

temporizing procedure should be out of the question. The first step, under such conditions, is to anesthetize and remove the pulp, as has just been described. When this has been done, a fissure bur should be inserted between the buccal and palatal roots at the point *A*, and a cut should be made through into the pulp chamber and up to the grinding surface, as is designated by the dotted line. This may either be repeated on the other side, or the cut may be continued directly through the pulp chamber until the crown has been completely cut in two, leaving one half attached to the buccal roots and the other half to the palatal root. Then the novocain mixture should be injected freely about the palatal root until the gum is white and insensitive, when a single pry with a spoon elevator between the adjacent molar and the palatal root will extract it, leaving the buccal

roots with the attached half of the crown as in Fig. 58. *G* represents exposed pulp chamber not yet prepared for filling. Of course forceps can be used to extract the root if desired, but the elevator usually gives the best results. The pulp chamber and canals in the buccal roots should now be sterilized with formalin and tricresol and cut out and filled. If the attached portion of the crown is sound and undecayed it can be dovetailed as in Figs. 59 and 60 and filled with any filling material or with an inlay (Fig. 61), so that when it is completed it will resemble Fig. 62. It will then resemble a large, plump, useful bicuspid with two roots, turned on its side. Such a tooth will give excellent service in the mastication of food, and as regards looks, from the outside it appears just as before, since the buccal cusps have not been altered. Where the crown is decayed or missing the remaining roots should be restored with amalgam, as described in Chapter VII, and fitted with a suitable crown, either of gold or platinum, with a porcelain facing.

When a buccal root of a superior first or second molar is necrotic and has to be removed, somewhat the same procedure should be followed. In Fig. 63, *A* represents a necrotic buccal root, *B* the palatal, and *C* the normal buccal root, *D* the crown of the defective tooth, and *E* the crown of the adjacent tooth to which a sufficient contour should be made or preserved. The dotted line shows how the cut should be made so as to maintain the supporting contour against the adjacent tooth *E*. This can be made with a fissure bur in a manner similar to the method just described, and should be done after the pulp chamber and the root canals in the two sound roots have been filled. When the root has been cut absolutely free from the tooth, novocain can be used and the root can be extracted with an elevator. If the crown is not perfect, and a good support against the adjacent tooth is not present, the crown should be made perfect with some suitable filling. Of course, the natural crown, if preserved, should be polished smooth with stones where the root has been excised.

Figure 64 represents the crown *D* with the defective buccal root removed. When this operation is properly completed it

should be possible to easily cleanse the contours of the interdental space with floss-silk.

When we come to the lower first and second molars the procedure is the same but more simple, as here we have usually but two roots. As described in the previous case, when a ne-

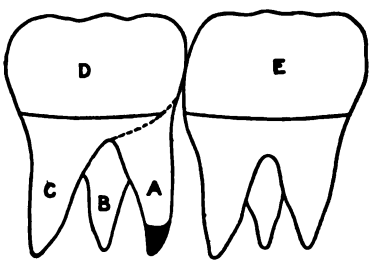

Fig. 63.

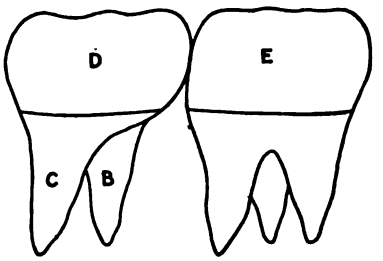

Fig. 64.

Figs. 63, 64 show the method of removing a defective buccal root from an upper molar so as to preserve the approximal contact with the adjacent teeth.

crotic root is associated with a partly living pulp, the pulp in all the canals of the infected tooth should be removed prior to the excision of the root. When this has been accomplished we can proceed to the excision and removal of the necrotic root in ques-

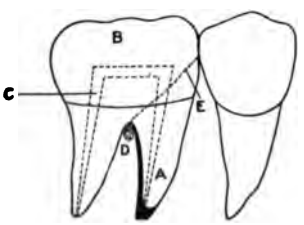

Fig. 65.

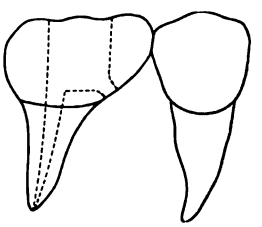

Fig. 66.

Figs. 65, 66 show how the defective anterior root of a two-rooted lower molar can be removed and the contact with the adjacent tooth preserved.

tion. Figure 65 represents a first lower molar with an undecayed crown. The anterior root *A* is necrosed and the pulp dead. The posterior root is sound, with a living pulp. *B* is the crown, *C* the pulp outline, *D* the spot of infection in the bifurcation

The abscess at the fork of the roots makes a complete canal of infection underneath the tooth. Let us suppose that the pulp canal has been opened and the living pulp removed. If the crown is undecayed, a complete operation can be performed by inserting the fissure bur at the bifurcation of the roots, and excising the root along the dotted line *E*, so that the contour and approximation against the adjacent tooth can be retained. When this has been done, the root can be pried out sidewise by means of an elevator, leaving the tooth as in Fig. 66. The remaining pulp canal in the posterior root can then be sterilized in the usual way and the root and crown filled, care being taken to smooth the filling within the pulp chamber where the root was excised.

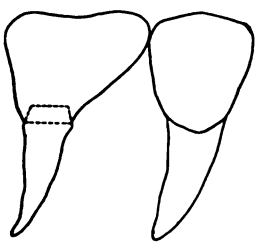

Fig. 67.—Diagrammatic method of restoring a single molar root with a crown so that the interdental space can be preserved.

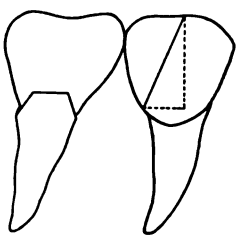

Fig. 68.—Same case, with the interdental space divided between the crown and the filling in the adjacent tooth.

Where the crown of the molar is badly decayed, the remaining root should be fitted with a properly contoured crown, so that it will rest securely against the adjacent tooth. This support is most essential and will prevent undue tipping until the bony socket of the extracted root has completely filled in and healed (Fig. 67). If the root is decayed below the gum it must be filled up with amalgam and properly contoured before it is covered by a suitable crown, as described in Chapter VII. If, as sometimes happens, the adjacent tooth is decayed or already has a filling, the extra contour necessitated by the loss of the root can be divided between the two teeth, the filling being made larger, and the crown being correspondingly decreased in size, as in Fig. 68. Sometimes we have a lower molar where the tips of the roots are

healthy, but the gum and alveolar process have receded to such an extent that the infection has worked completely through the bifurcation of the roots, forming a channel under the tooth that the ordinary daily cleansing cannot possibly reach or restore to healthy condition, as in Fig. 69.

A represents the crown of a lower molar, *C* represents the gum line, showing the recession, and *B* represents the spot of infection and tartar in the bifurcation of the roots. The hopeless future of such a molar is apparent. The gum that has receded cannot be restored to cover up the bifurcation, and the opening will be a constant invitation for the lodgment of bacteria and tartar, which will not only result in the eventual loss of the

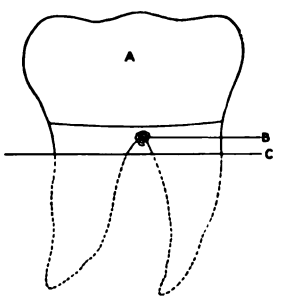

Fig. 69.—Molar with the bifurcation of the roots exposed and infected, where cleansing is impossible.

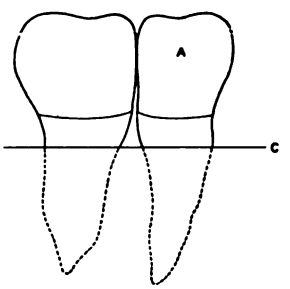

Fig. 70.—Tooth divided and converted into two bicuspids which can readily be cleansed with brush and dental floss.

tooth, but also in grave systemic infection. Such a condition cannot possibly be tolerated even if the remedy demands the loss of the tooth. But such a sacrifice is by no means always necessary. The principal need is a chance to thoroughly cleanse the channel under the tooth and a chance to keep it clean, and that can be accomplished as in Fig. 70. When the pulp has been devitalized and the root canals filled, the bifurcation should be boldly extended up through the middle of the crown of the molar until the roots are completely separated; and the separated parts of the crown should be filled as though each was a bicuspid, leaving a cleansing space through which the floss-silk can be passed just as in any of the approximal spaces of the other teeth.

If there is excessive mobility a staple of platinum can be inserted in the adjacent fillings so as to make them join (Fig. 71). If this is done, the floss-silk will have to be passed underneath the staple by means of a needle with a blunt point. The floss-silk can be slipped through the eye, the flexible needle passed between the teeth that are stapled together and drawn through, carrying the silk with it. The silk can then be swept over all the surfaces and the bacterial deposits entirely removed.

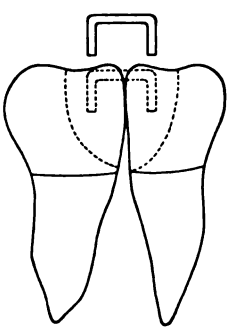

Fig. 71.—Two parts of tooth strapped together by a cemented staple for the purpose of securing greater stability. Here the interdental space must be cleansed with dental floss inserted beneath the staple by a wire needle.

Sometimes when the roots have been cut apart and the pulp chamber is still open, it is well to put in a gutta-percha filling for a month or so, in order that the mastication on the gutta-percha shall spread the two portions of the divided tooth into absolute contact with the adjacent teeth; thus the fillings put in the two halves of the pulp chamber will have a more perfect support from the dental arch. When the crown is badly decayed the separate roots must be capped, as is ordinarily done with single-rooted teeth.

CHAPTER VII

FILLINGS

Hammered Gold. Inlays—Porcelain and Gold. Advantages and Disadvantages of Cement. Silicious Cement, Amalgam, and Gutta-Percha

Operative Efficiency.—Frederick W. Taylor in his scientific shop management showed conclusively that there should be no such thing as unskilled labor. He started on the basis that there is a best way to do everything. He searched until this best way was discovered, and then he saw to it that each workman under his care was instructed and even compelled to use this way. Thus the workmen, instead of using various methods according to their individual whims, all became skilled workmen, to the great benefit of their employers and themselves. By his plan as simple a proceeding as loading pig-iron on a car was reduced from a haphazard process to a science. The man that could load only 12.5 tons of pig-iron a day when left to his own devices, under scientific management readily loaded 47 tons in the same time. Mr. Taylor found that 21 pounds was the proper weight for each shovelful for the average man if he would do his best work and not become tired during the day; he also showed the men the most efficient method of shoveling. Then, by having shovels of various sizes to suit the kind of material shoveled, he made a man carry in his shovel 21 pounds, whether he was shoveling iron ore, coal, or sawdust.

The great value of such a plan is obvious. Dentists are suffering from the lack of just such training. Each teacher in the dental schools is apt to advocate the methods used by his former teachers, which methods are varied according to the instructor's personal skill or mechanical bias. There is no standard best method which all students are taught. Some men employ

methods that will obviously give better results in one-half the time. These methods should not be brushed aside as requiring skill unattainable by others. They should be studied and collected into a system that would stand as a model for all teachers to use until scientific research has demonstrated a further advance. In fact, the dentists of the future should be taught dentistry in reference to a recognized standard, both as regards rapidity and efficiency. Since we are working on living organisms, it is especially necessary that no judicious means of shortening the time of an operation should be overlooked.

In a surgical operation rapidity of action is a recognized element of great importance. The longer the patient is kept under ether, the greater is the danger from exhaustion and surgical shock. At such a time a life may hang on the question of ten minutes. Before the days of anesthetics speed was considered of even more importance than now. And yet some dentists perform operations on conscious patients sometimes consuming two or three hours of agonizing procedure to accomplish a result that other dentists will attain in one-half the time by work that is comparatively painless. Dentists will always differ in their relative skill and speed, but such differences as now exist can only come from defective technic. Some dentists prepare cavities for filling in five minutes that other operators require an hour to shape. A man will sometimes take ten or fifteen minutes to adjust a rubber-dam under a sensitive gum, causing great laceration of the peridental membranes, in order to put in a gutta-percha or amalgam filling that ought not to have taken over two or three minutes to insert with the aid of the cotton roll or napkin.

The Old Hammered Filling.—For instance, what could be more ridiculous than the present employment of the hammered gold filling for repairing a decayed spot in a tooth? It is a long, tedious, painful process to both the patient and the dentist. The most skilful operator has a decided percentage of non-bacteria-proof edges, and the average dentist seldom makes any bacteria-proof edges at all, so that the tooth filled with hammered gold ordinarily begins to decay as soon as the filling is

inserted. Especially is this so if the filling is between the teeth, where the mastication of food will not sweep it clean and the bacterial plaques are allowed to grow upon it unmolested. Apropos of the way a joint that is not bacteria-tight can be a source of decay, I might mention an experience of my own early days of practice. It was during my first year after graduation that a child came to me with characteristic softening of the sulci in the four upper bicuspids. The teeth were sensitive to the blows of the hammer, and yet I cut out the four sulci and inserted four shallow gold fillings. Accurate condensation of the gold was impossible owing to the fact that the tips of the roots had not been formed sufficiently to withstand the stroke of a strong enough blow to do the work. In two years the child returned, and where two of the fillings had dropped out there was no decay, and where the two remaining ones were still clinging to their undercuts, well-defined decay was making its insidious inroads toward the pulp. The two fillings that had dropped out had fortunately done so before the decay had had a chance to become intrenched in the imperfect margins, leaving cavities that were shallow enough to be self-cleansing by the action of mastication. Ever since that experience I have merely polished out these soft sulci wherever it was possible to leave them with hard, perfect cups of enamel that were self-cleansing. This is always possible if the tooth is examined for such soft spots as soon as it comes through the gum. It cannot be stated too often that the thinnest coating of enamel is a far better protection than the best filling that has yet been invented.

We constantly hear of the beautiful gold fillings with perfect edges that lasted over fifty years. In speaking of such a filling it is invariably intimated that with careful technic perfect fillings are always possible. In my experience, however, even the dentists most skilful in making hammered gold fillings have had a high percentage of failures, and most of them frankly admit it.

I continued to put in hammered gold fillings for some fifteen years, and finally even made gold fillings that had a specific gravity greater than cast gold. I have put in gold fillings that have now lasted twenty-five years, and admit that probably

this is due more to the fact that the gums have receded, leaving the margins self-cleansing, than to any intrinsic value in the method. But such a fact does not prove in the least degree that the hammered gold filling or the gold filling put in against bare dentin is not now antiquated. When it is necessary to use gold to resist the force of mastication it should always be put in with cement as a bond between it and the tooth structure. By this means a bacteria-tight joint can be insured, and every filling that is inserted will faithfully perform its part of the tooth preservation, whether it is inserted by expert or beginner. This is especially so since the advent of the new silicious cements that are insoluble in the mouth, and have a strength of substance that makes them suitable for attaching fillings to the tooth structure. The cement also protects the tooth from the shock due to the great thermal conductibility of the gold.

Even when the only cements available were soluble in the mouth, the inlay fairly won its way against the hammered gold filling, both because it preserved more teeth and because it avoided the long, battering strain. But now, with an insoluble cement available, the inlay should always be preferred wherever a hammered gold filling might in the past have been deemed advisable. In view of the fact that the silicious cements are being so perfected as to insolubility, color, translucency and strength of material, it is a question whether in time they may not largely, if not entirely supplant all of the other fillings, the inlay itself not being excepted. In fact, this insoluble cement, capable of absolutely matching a tooth, may sweep away the necessity for a large part of the intense, mechanical refinement that has so loaded down the dentist in the past, and give him the time essential for mastering the medical aspects of his work. With the hammering of gold fillings eliminated, and gold inlays made in five to fifteen minutes rather than in an hour or two, with crowns and bridges set in a cement that will conceal the joint of the porcelain, and fillings made boldly above the gum because the color of the teeth can be matched, two-thirds of the mechanical drudgery of the dental student can be thrown into the scrap basket of dead processes, and he will be able to

devote the time thus saved to the study of pathology, bacteriology, immunology, and surgery. With the new dentistry thus instituted, it is possible that false teeth, crowns, bridges, fillings, and pyorrhea instrumentation will be reduced in volume to 1 per cent. of their present appalling proportions, and the future medically trained dentists will be able to cope with the disease of mouth infection, now almost universal, through efficient instruction of the public in the technic of scientific mouth hygiene.

Before the days of plastics, the making of a filling was a very serious and exhaustive problem, yet many dentists, in spite of the general improvement in materials, are still using the materials and methods of the dark ages. Simple cavities in the grinding surfaces of molars and bicuspids, cavities in the sides of the teeth where there is no force of mastication to be resisted, as well as the compound cavities, are still hammered full of gold, with useless agony and fatigue to both dentist and patient. But, fortunately, the great majority of these cavities can now be quickly and permanently filled with silicious cement. The fillings that can be safely made with silicious cement are those that do not receive the force of mastication, and those that do receive it, but are supported on all sides by enamel walls; for silicious cement is insoluble, strongly resists abrasion and withstands a high crushing strain. When, however, a filling is not supported on all sides, as in an approximal contour cavity, such as we find in molars and bicuspids, and receives the full force of strong mastication, the cement is apt to crack off, its cleavage resistance being particularly low. In such cases an inlay set in silicious cement should be used (Fig. 72).

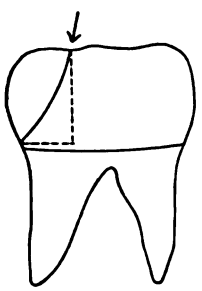

Fig. 72.—Arrow represents point of cleavage.

Porcelain Inlays.—Such an inlay may be of either porcelain or gold. Where excessive force is to be withstood and the filling is out of sight, the gold should be used with modern silicious cement as a binder. But where the inlay is plainly visible,

porcelain may be used, as it can be matched to the tooth so as to be really invisible, and it has sufficient strength to withstand the force of mastication to an astonishing degree. Delicate, frail porcelain tips cemented on the fractured corners of incisors have already given good service for fifteen years and show every sign of lasting indefinitely. It is true that any chance blow or bite on a piece of bone or stone may dislodge them at any time, but that may also be said of a corner of a natural tooth. The wonder is not that a few insecure or frail inlays break away, the great wonder lies in the fact that so many of them last indefinitely.

In displacing hammered gold for porcelain we are confronted with the question: Will porcelain withstand the force of mastication, not better than gold, but sufficiently well to be worth while? There is no question of comparing it with gold, for in porcelain we have brittleness as an obvious danger, and therefore in using porcelain as an inlay we must carefully consider its relative strength and brittleness.

Porcelain Strength.—The principal forces that tend to dislodge a porcelain tip are pressure, shear, and percussion. The more the force is exerted longitudinally, that is, along the axis of the tooth, and the nearer it is exerted to the cement base, the less tendency there is for fracture. The more the force is exerted transversely and the farther it is exerted from the base, the greater the tendency for fracture. Of course, when force is applied absolutely in the axis of the filling, the distance from the base, theoretically, makes no difference, as there is no tensile strain put on either side.

Dr. Jenkins' tests[1] proved that pieces of porcelain 1 cm. square by 2.3 mm. deep can stand a steady pressure of from ¼ ton for the Whiteley to 1 ton for the Jenkins porcelain, the others falling somewhere within the intervening ¾ ton. Dr. Jenkins tells us of the German laboratory in which these results were obtained and how long it took to make them, but does not tell us how they were made. I feel, however, that this great pressure resistance could only have been obtained under the most perfect

[1] Cosmos, May, 1902.

conditions, where there was pure compression without percussion or shear. However, if we could approximate these conditions in the mouth, most of us would be satisfied with the Whiteley ¼-ton resistance, as it is not likely that the human jaw would care to tax itself more than that.

So much for steady compression. On this point, obviously all porcelains are able to take care of themselves. We must,

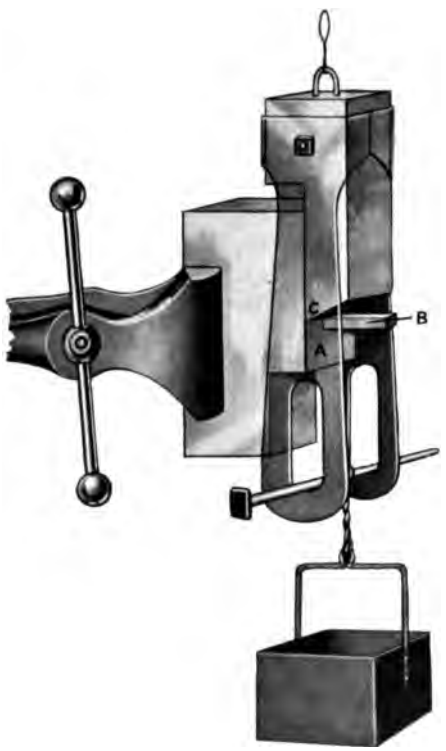

Fig. 73.—Instrument for measuring shearing strength of porcelain.

then, look to shear and percussion for the weak points. First, let us consider the effects of shear. For this purpose we have a bar of porcelain, 0.075 by 0.125 inch, cemented into a block of ivory and projecting perpendicularly from its surface. These dimensions were chosen because they were felt to be safely above the average size of any porcelain tip or corner, and yet to fairly

well approximate the conditions in the mouth. The porcelains, unless otherwise stated, were fused on platinum and afterward cut to the proper dimensions on a carborundum wheel. They were identical, according to the Brown & Sharpe gage, within 0.001 inch. Three separate instruments for measuring the shear had to be made before friction, jam and variations in the pull were successfully eliminated. Finally this simple apparatus was devised (Fig. 73): *A* represents a block of ivory with a smooth, flat surface; *B* represents the porcelain bar, 0.075 by 0.125 inch cemented into the ivory block, *A*, at right angles to the smooth surface; *C* represents a second block of ivory with a smooth, flat face terminating in a knife edge. Block *A* was screwed into a vise, so that its smooth face was absolutely perpendicular. The smooth surfaces of *A* and *C* were placed in apposition, with the knife-edge of *C* resting on the base of the projecting porcelain, *B*. A bucket for weights was attached in such a way as to bring the vertical line of force in the coincident planes of *A* and *C* exactly at the base of the porcelain bar. Fine shot was slowly and steadily poured into the bucket until the porcelain snapped. The shot, bucket, and block *C* were weighed and the result noted. Block *A* was then removed from the vise; the remaining bit of porcelain was crushed by a small punch, reamed out with a drill, and another bar of porcelain cemented into position. The procedure was then repeated.

The inlay porcelains tested in this way were Jenkins', Brewster's, Whiteley's, and S. S. White's.

The Jenkins inlay material obtained in 1900 stood 23, 36, 27, 16, 33, 23, 23 pounds; average, 26 pounds.

The Jenkins improved inlay material stood 16, 14, 16, 15, 13 pounds; average, 15 pounds.

The Whiteley stood 28, 21, 19, 19, 18, 19 pounds; average, 21 pounds.

The Brewster stood 15, 20, 18, 23, 19 pounds; average, 19 pounds.

The S. S. White stood 29, 24, 25, 24, 25 pounds; average, 26 pounds.

Experiments were made on bars cut from blocks of molded

porcelain made respectively of Whiteley and S. S. White inlay materials, resulting in the following figures: S. S. White, 19 and 20 pounds; Whiteley, 14 and 18 pounds. In these tests the compressed porcelain shows less strength than the uncompressed. It will be noted that the Jenkins improved material had much less shearing strength than the older material, which is probably due to the fact that Jenkins' improved material made a better filling material although at a slight sacrifice of shearing strength.

It was then determined to make pressure away from the base of the bar so as to note the modifying effect of leverage. The ivory block *C* was cut so that the knife-edge rested on the porcelain bar 0.075 inch out from its base, and the attachment holding the weight was adjusted to the new plane. Experiments showed that porcelain standing 26 pounds, when applied at the base, now broke at 6 pounds, demonstrating what a tremendous difference is made by a very small leverage. Further tests were made with the porcelain bar fastened into the base with a thin packing of rubber-dam, and it was found that such a springy base, not unlike the peridental membrane around a tooth, made no difference in the amount of direct pressure required to break the bar.

To try the effect of a percussion blow the same apparatus was adjusted horizontally, and instead of weights, rubber bands were used to give the blow (Fig. 74). The procedure was as follows: The ivory block holding the bar of porcelain was sunk into an oak board to make a secure foundation. The plane surface in which the porcelain bars were to be cemented was parallel and true with the surface of the board. Nails at small intervals were driven into the board for attachments for rubber bands, which when attached to the 2-ounce ivory wedge would snap it through a distance of $\frac{1}{4}$ or $\frac{1}{8}$ inch before it hit the porcelain bar. The force of the rubber bands was so arranged as to draw the ivory wedge perfectly true along the surface of the ivory before it struck the base of the perpendicular porcelain bar. After the porcelain broke, the pull of the rubber was measured by a spring balance. The distance that the plunger was held from the porce-

lain was controlled by a small loop of twine fastened from the head of the plunger to a nail driven into the wood at a suitable place. It was found that perpendicular bars of porcelain hit by the 2-ounce plunger through a distance of ¼ inch broke at a ridiculously low figure.

With blows through ¼ inch, a bar of Jenkins' old material, cemented into the ivory surface, broke at 6, 8, 7, 5, 5, 5 ounces; average, 6 ounces.

Jenkins' new material broke at 8, 9, 8, 9, 8 ounces; average, 8.4 ounces.

Whiteley's broke at 7, 8, 9, 10, 7, 6 ounces; average, 8 ounces.

Bars from Brewster body broke at 6, 5, 6, 5 ounces; average, 5.5 ounces.

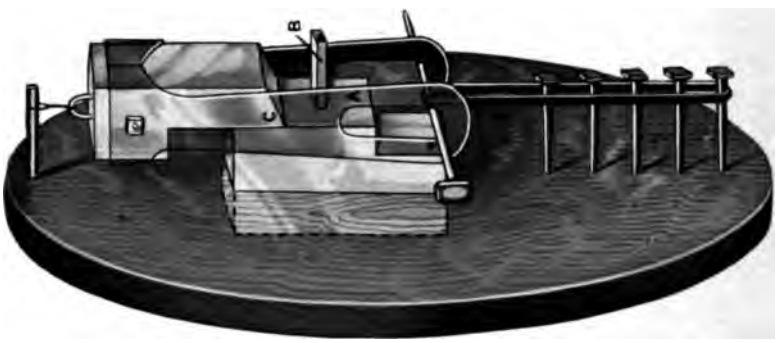

Fig. 74.—Instrument for measuring the strength of porcelain under percussion.

Bars from an old S. S. White porcelain tooth broke at 5, 5, 6, 5 ounces; average, 5 ounces.

The S. S. White bars made from compressed porcelain broke at 5, 6, 5, 6 ounces; average, 5.5 ounces.

The author does not care to make any general deductions from these figures, but it is interesting to note that in general the porcelain that stood the least shearing force had the greatest percussion strength. Also that the compressed porcelain seemed to have less percussion strength and less resistance to shear than porcelain made without compression. All of these bars of porcelain, when surrounded by rubber-dam instead of cement in the ivory base, broke at 14 to 16 ounces, indicating that with per-

cussion blows the spring of the peridental membrane undoubtedly greatly increases the force required to break porcelain.

Now as to the effect of percussion on the surface of a simple porcelain inlay. The machine for testing was as follows: A $\frac{1}{4}$-inch square filling of Jenkins' inlay material, 0.1 inch deep, was cemented into a block of ivory. The sides were parallel and perpendicular to the surface of the ivory. The block of ivory was screwed into a board so that the side containing the filling was perpendicular to the board. Then a brass plunger, headed with a lower bicuspid tooth, was projected by means of rubber bands against the filling through a distance of $\frac{1}{4}$ and $\frac{1}{8}$ inch respectively. The strength of the pull of the rubber bands was measured by scales fastened to the back of the plunger. The results obtained were as follows: The edge was slightly powdered at the first 5-ounce blow; at the third 5-ounce blow a crack ran across the corner. This block of porcelain, the corner of which was fractured by a 5-ounce blow, was thicker than the block of porcelain of the same material claimed by Dr. Jenkins to have stood a steady pressure of 2020 pounds. This corner began to be powdered at the fourth 10-ounce blow. These blows were all through a distance of $\frac{1}{4}$ inch. The same blows were given through $\frac{1}{8}$ inch, and it was found that it took 7 ounces to chip the edge. Another corner was tried, and it took 1-pound blows to break the corner, delivered through $\frac{1}{4}$ inch.

The experiment was then tried of cutting a corner free from the cement and ivory, leaving it supported beneath, about as a corner of a tooth would be. The first 5-ounce blow chipped it off a little and a 22-ounce blow was required to break it off entirely. This test seemed to prove conclusively that porcelain cannot withstand the full percussive force of the teeth. It apparently can stand this force and more under steady pressure, especially as this force is usually applied through the intervening medium of food, but we must accept the fact that no porcelain has yet been made that can withstand the ordinary percussive force that during mastication may at any time be developed. Fillings, therefore, must be rounded so as to receive glancing blows, the edges must be kept as free as pos-

sible from strain, and if they chip, the powdered edge should be cut out with a fine inverted cone bur and filled with silicious cement.

The author has not gone into the subject of the specific gravity of porcelains, for he has not been able to find that it has any particular bearing on the case. In fact, glass, which is porcelain fused to even consistency, according to Hovenstadt's Jena glass tests, seems to resist crushing force almost inversely proportional to its specific gravity. It is interesting to note that all the thirty-five glasses tested for crushing force stood from seven to fourteen times as much as any of the porcelains tested by Dr. Jenkins. It is also of interest to note that the bars of compressed porcelain of S. S. White and Whitely inlay materials did not stand as great a test as bars of the same material molded in the ordinary way without pressure, seeming to show again that great density is not necessarily a factor that makes for strength in withstanding the force of mastication.

These facts seem to point to the following conclusions: All of the standard porcelains in the market are, for practical purposes, equally strong, but none of them are strong enough to receive the full force of mastication. So the question resolves itself into which porcelain has the best colors and which is most easily manipulated.

The Porcelain Inlay Matrix.—In 1887 Dr. C. H. Land made mechanically perfect edges possible for intricate porcelain inlays by devising the metal matrix. He made use of both gold and platinum matrices, but found the latter preferable, as platinum could be adapted with a facility equal to gold, and allowed the use of a high-fusing porcelain body that insured insolubility as well as giving the most life-like reproduction of the color of the tooth to be repaired. From this discovery dates all effective porcelain filling. Before this, pieces of porcelain had been ground to fit labial cavities with fairly good results, and pieces of natural enamel from extracted teeth had been inserted in a similar manner, but the accurate adaptation of porcelain to approximal or compound cavities was practically impossible until the metal matrix was evolved. Some men still use a porcelain that can

be fused upon gold, but the higher-fusing porcelain requiring a platinum matrix gives more consistent and better results.

Construction of a Porcelain Inlay.—The cavities should be free from undercuts. If these are unavoidable through extensive decay, the cavity should first be filled with phosphate of zinc, then shaped into a perfect cup with a flat bottom. The edges should be sharp and smooth, and where they are approximal there must be sufficient separation to allow the metallic material in which the porcelain is to be fused to be withdrawn without distortion. The final polishing of the edges of the cavity can be done with a small carborundum stone, which can be carved to any shape and size with a diamond point. A finishing bur is also excellent for this purpose, as is also a sand-paper engine disk.

Fig. 75.—Cavities formerly filled with gold or porcelain—now advantageously filled with silicious cement.

The silicious cements have so far replaced the insertion of porcelain in simple labial or buccal cavities, as in Fig. 75, that there is not one inserted now where there used to be a hundred; and yet there are cases where the porcelain can be used with advantage, for example, in the mouths of tobacco smokers, where the cement would ordinarily discolor. Therefore the technic of making such a porcelain filling can be advantageously included in the general study of porcelain inlays.

Where the inlay is to stand the force of mastication the edges of the cavity should be at right angles to the grinding surface (Figs. 76 and 77). Such a precaution will obviously add to the permanency of the filling, as it provides the greatest possible resistance of both tooth and filling to the strain of mastication.

The preparation of the cavity being completed, the matrix is made with rolled platinum, 0.001 inch in thickness. Foil thinner than 0.001 inch seems to lack sufficient body to stretch properly without tearing. This platinum if annealed in a Bunsen burner or with a blow-pipe will be harsh and unfit for use, but when annealed in an electric furnace it becomes soft and tough. It is most essential that the platinum be absolutely soft. The platinum is placed over the cavity and pressed with spunk or bibulous paper as far as possible without tearing. This gives us the greatest amount of metal with which to form a mold. The edges now have become distinctly outlined, and from this time the platinum must be held absolutely immovable or good results cannot be obtained. When the edges have become outlined

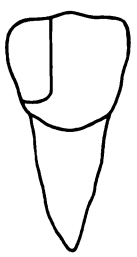

Fig. 76.—Correct incisal angle for a porcelain filling.

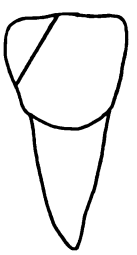

Fig. 77.—Incorrect incisal angle for a porcelain filling.

they should be gone over carefully with ball burnishers (Fig. 78, *a* and *b*) and made sharp and free from wrinkles, the metal being spun down into the cavity as far as can be done without danger of tearing. Should wrinkles in the metal occur they must be smoothed out before they reach the edge with the spatula shown in Fig. 78, *d*. Then the metal should be boldly swaged to the bottom of the cavity with bibulous paper held with the pliers (Fig. 78, *c*). This can usually be accomplished without tearing the foil, but if tears do occur they are quite harmless, as they cannot extend to the edge where the foil has already been adapted. Where the labial cavity extends under the gum a larger piece of foil, held immovable well up on the gum and swaged down on the cavity with bibulous paper, will form an

arch that presses and holds the gum back, so that in cases that at first seem absolutely hopeless of success the upper margin of the cavity will be clearly defined.

The soft, unburnished platinum takes a beautiful impression, but when the metal has been burnished or swaged it be-



Fig. 78.—Instruments useful for forming a matrix.

comes elastic. If, therefore, the matrix be moved during its formation an accurate impression is practically impossible, for the elastic platinum, when distorted, cannot be forced back accurately into position until it has been re-annealed. The matrix when finished should be carefully heated to redness in order to render it sterile. In labial cavities the piece of platinum

should be cut sufficiently large to extend beyond the two adjacent teeth, and the metal should be moulded to the three teeth

Fig. 79.—Position of instrument and fingers in burnishing a matrix into place on upper incisors or canines.

by pressure with cotton and bibulous paper. The metal is then held firmly upon the two adjacent teeth by the first and second fingers, as in Fig. 79, when the general directions for adjusting

Fig. 80.—Position of fingers in forming a matrix to cavity in incisal corner of an incisor.

the matrix to the cavity may be readily carried out. The large piece of platinum has two great advantages—it conduces to

Fig. 81.—Position of hands in forming a matrix for a compound cavity on the anterior approximal surface of a left upper molar.

Fig. 82.—Position of fingers in forming a matrix for the compound approximal cavity in the posterior surface of an upper bicuspid or molar.

immobility of the metal during the formation of the matrix, and it gives the entire labial form of the tooth, so that an accurate idea may be obtained of the desired contour of the filling.

In corners of centrals, as in Fig. 80, the platinum should be folded well over the labial and lingual surfaces of the teeth, then it should also be bent over the cutting edge, forming a cap beneath which shows the entire contour of the tooth, and by means of which entire immobility may be obtained while the cavity margins are being defined and the matrix formed. The same principle applies in forming a half cap from a large piece of platinum for

Fig. 83.—Method of splitting platinum matrix near the impression of the cavity in order to facilitate easy removal of the foil through a narrow space without distortion.

the approximal cavities of bicuspids and molars. The platinum should extend, as in Figs. 81 and 82, from grinding edges to cervical margin, and along the adjacent sides of the tooth. This can be firmly held with the index-finger and thumb of the left hand, while the right hand with tweezers and bibulous paper presses the metal partly into the cavity. The margins and floor of the matrix may then be defined with a burnisher. It is most

important that the greater part of the grinding surface of the tooth shall be outlined in making the mold, as by this means a truss effect is produced that will prevent the distortion of the sides of the matrix, both when it is taken off the tooth and when the porcelain is being fused. In mesial cavities the metal must be pushed away from the operator and the matrix held by means

Fig. 84.—An excellent device for holding metal immovable while being burnished into position.

of the thumb and forefinger, as in Fig. 81. In distal cavities the metal is pulled toward the operator, who works around and beyond the fingers holding the platinum as in Fig. 82. When, as sometimes occurs, the adapted platinum is dove-tailed around the teeth so as to render its removal difficult or impossible without distortion, the outer edge of the platinum may be split with a sharp knife from the gum line to a point just beyond the cavity

margins, as is shown in Fig. 83. Figure 84 shows a method of obtaining immobility of the matrix by a clamp that is sometimes useful. Figures 85 and 86 show the position of the fingers when

Fig. 85.—Position of fingers in holding the foil while matrix is being formed on lower right side of jaw.

manipulating the matrix on the lower teeth. This, as before stated, should be done while the matrix is held motionless in the cavity. It is sometimes advisable, in order tht pearfect immo-

Fig. 86.—Position of fingers in holding foil while matrix is being spun into cavity on lower left side of jaw.

bility may be obtained during the final burnishing of the margins, to re-anneal the matrix just before its completion, and then after its replacement to pack it full of cotton or bibulous paper,

leaving the edges exposed to the unrestricted action of the burnisher. When this has been done and the packing removed there will be no difficulty in teasing out an undistorted matrix from the cavity.

Color Selection.—The color of the filling must next be considered. This is one of the most important steps in the entire operation, and while the accuracy of selection must ultimately rest with the color sense of the operator, there are nevertheless a few fundamental rules that will be of material assistance. There are two great factors that must be solved if a porcelain filling is to accurately match the tooth into which it is inserted: first, the proper color must be decided upon by means of a sample piece of porcelain on a shade ring; second, that porcelain must be accurately reproduced by a judicious mixing of the basal porcelain shades and by accurate baking. The question of deciding on a color is not a mere question of matching the tooth, but of deciding on the porcelain that will match the tooth perfectly after the porcelain is cemented into position. An inlay may match a tooth perfectly before it is cemented into place, and afterward be hopelessly off color, and the reverse is also true. Many times the porcelain filling that does not match at all out of the mouth, when it is cemented into position will melt out of sight and become invisible. In plain words, the shadow cast by the cement that holds the inlay in position, or the shadow cast by the tooth walls modifies the color of the inlay in an astonishing degree. Therefore, in addition to the classification —labial, buccal, approximal, contour, etc.—porcelain fillings are to be considered in regard to their positions in the mouth, viz., fillings that keep their color when cemented into place and those that will be darkened by consequent shadow. The color of a porcelain filling is dependent upon the perfection with which the light is reflected to the eye of the observer. In a bright, direct light yellow porcelain is yellow because all the other rays that make up the light are absorbed and only the yellow are reflected. If the light be gradually decreased, fewer yellow rays will be reflected and the color will become darker. When there is no light the porcelain will appear black. Take, for instance, a

simple labial cavity, as illustrated in Fig. 87. If this extends into the dentin sufficiently deep to prevent the color of the cement from shining through it, and the porcelain is not overbaked, the true color of the porcelain will be given. This is especially so when the modern silicious cements are used for a binding. With the old opaque phosphate cement it was always an approximate match, "good if one didn't look at it too hard." In Fig. 88 the fillings go straight through the labial and palatal walls of the enamel, and yet, if both fillings are made of porcelain that matches the tooth substance, the corner inlay when cemented into position will look well, while the half-moon shaped filling will look dark. If, however, the moon-shaped filling does not go through the

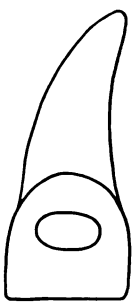

Fg. 87.—Porcelain inlay where color of tooth is easily matched.

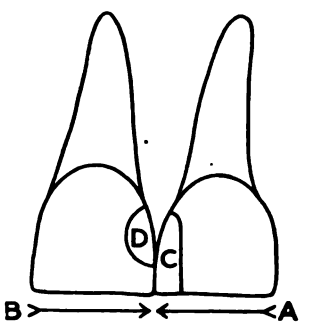

Fig. 88.—*C*, Easy to match; *D*, difficult to match.

lingual wall and the cement extends entirely behind it, its color will be nearly if not quite as good as that of the corner. The difference of the shade of these two fillings may be explained as follows: the corner *C* is illuminated by the side light from the cutting edge, while the half-moon shaped filling *D* is shut in on four sides, on three by cement and on the fourth by the adjacent tooth. With *D* the light passes through the porcelain with a great loss of reflection and with a loss of light, while with *C* the side light brings out the color. It must be further noted, with reference to the corner *C*, that if it is looked at directly from in front or from the direction of the arrow *B* toward the cement, the color will be good. If, however, it is looked at away from the cement,

as indicated by the arrow *A*, the color will be lighter or darker according to the intensity of the light. This, however, is much less apparent since the translucent silicious cements have become available. It should therefore be easy to obtain a good color in a corner inlay. Buccal fillings in bicuspids and molars are as easily matched as simple labial cavities, for they come under the same condition of light reflection. Cervical fillings that extend to or under the gum are affected by the shadow of the gum, and all approximal inlays from the posterior surface of the canines back through the molars show the same falling off in color, and unless proper allowance is made for this, disheartening results will be the outcome of otherwise careful work. There will be a darkening of the inlay in direct proportion as the cement shuts off the light and throws a shadow into the body of the porcelain, which shadow can be overcome to a certain extent by the judicious addition of yellow.

It will be found where a silicious cement filling is used instead of porcelain that the same law holds, and that a judicious modification in color must be made if a good match is to be obtained. Those fillings not materially affected by shadow are simple labial cavities, corners and tips of central and lateral incisors, and the cusps of canines and bicuspids. Those most affected are posterior cavities in canines, bicuspids, and molars.

There are a few principles that will be a guide in combating this change of color. The shadow casts a blue into the filling, or, at least, if that is not correct from the law of physics, blue added to a filling will increase the shadow effect and yellow will counteract it. I shall give as an illustration an experience of my early days in porcelain. I wished to insert an inlay in the posterior surface of a canine, as in Fig. 89, that had a light yellowish-blue color. I tried matching the tooth accurately and when the inlay was cemented into place it looked like a piece of gray mud. It was taken out, and after several trials I decided to make the next inlay, if anything, too yellow. So a filling of light chrome yellow was made and when cemented into place, it turned exactly the color of the tooth, light yellowish blue. So, in cavities between teeth where the depth and cavity walls will cause but



90A

90B

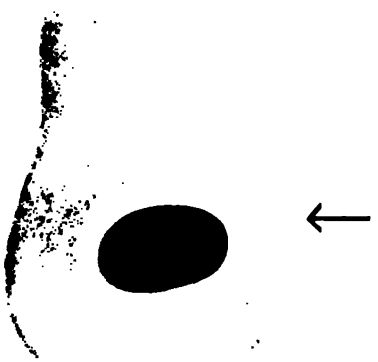

91A

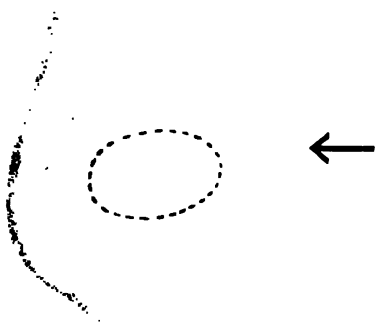

91B

Figs. 90A, 90B.- Porcelain inlays shown by the dotted line and the yellow spot. These inlays have their respective colors when the light is thrown directly upon them from a perpendicular axis, but when the light is thrown from the side, as in Figs. 91A and 91B, the formerly perfectly matched filling of 90A appears dark and the formerly yellow filling of 90B modified by the shadow of the cement and cavity walls becomes a perfect match with the tooth color.

little shadow, the use of light yellow is a valuable aid in counteracting the color change; but when the inlay represents a bad case of shadow to be overcome, deep yellow should be used and marvelous matches will sometimes be achieved—matches that seem like the work of necromancy (Fig. 90). For instance, we here have two sound bicuspids with simple buccal cavities which have been filled with porcelain inlays. The color of the teeth in each instance is light yellowish gray, as is shown by the illustration. The illuminating light in this instance is supposed to come from the front, where each filling will get direct light and reflection. It will be noted that while the filling in *A* is a perfect match, the filling in *B* is a decided yellow. This light reflection gives the fillings their genuine color values. If, however, the light comes in the direction of the arrow and the cavity walls and cement thus cast a shadow (Fig. 91), it will be found that the supposedly well-matched filling in *A* becomes a dark spot, while the filling in *B* matches, the yellow fading into light yellowish gray. With the tooth *B* the yellow will have to be added in sufficient quantity. If there is not enough shadow the filling will still be yellow; if there is too much shadow even the yellow filling will be dark.

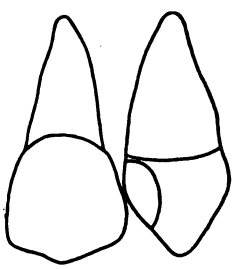

Fig. 89.—Posterior porcelain filling where addition of yellow will counteract shadow.

The same principle applies in the mixing of cements, especially the silicious cements. In matching the teeth the author uses only three colors—dark yellow, light yellow, and dark bluish gray. There are, of course, a great variety of colors that could be obtained, but they seldom just match and are usually a compromise; but with the three basal colors boldly used any effect can be obtained, and the author strongly advises all young dentists to learn to mix their colors from the basal colors rather than to depend upon the selections of the manufacturers. The same principle applies even more strongly in the mixing of the various colors in porcelain work, for, as in the cements, the

various manufacturers of porcelains make a large variety of mixtures, hoping to relieve the dentist of the artistic responsibility of mixing his own colors. It is as though a professional house painter depended upon the colors that were to be had in sample cans, and never trained himself to actually mix the fundamental colors himself. Such a painter, among his fellows, would be considered a joke.

There is but one set of porcelains, to my knowledge, that practically overcomes this ridiculous limitation. It is the porcelain made by Whiteley, with the shade rings (Fig. 92). This set consists of seven fundamental colors, which, when variously mixed, can make any shade in the shade ring. Not only are the basal colors supplied, but also a table stating the approximate proportions in which these colors should be mixed to form any shade. The set also provides a box of powdered white silex, that, when mixed with the porcelain in the proportion of 1 to 5, will reduce the shrinkage so that a filling can be made in two bakings rather than in six or seven, as is customary with other makes of porcelain. The silex mixture can be used in the preliminary bakings, but the final baking should be made with porcelain that does not contain the silex, as the silex has a slightly lightening effect, which, however, is not sufficiently marked to show through and affect the color of the outside coating of porcelain. When the various shades of porcelain have been selected they should be mixed together on a clean glass slab and made into a paste with water. The standard dryness is obtained by pressing a muslin napkin or a piece of blotting-paper upon the mixture until it has the consistence of dough. If the silex is to be used, as is wise in the larger fillings, this dough should be divided into two portions and the silex thoroughly mixed with one portion, in the ratio of 1 to 4 or 5 parts.

Making and Baking the Filling.—We are now ready to fill the matrix with the porcelain dough. This should be done as follows: The matrix should be seized with a pair of pliers at such a portion of the platinum as will not distort or infringe on the model of the cavity, and then a portion of the porcelain dough should be placed within the matrix on the point of a brush

A

B

Fig. 92.—*A*, Seven fundamental colors which, judiciously selected and mixed, can reproduce any color on the circular shade ring below, *B*.

or spatula (Fig. 93) and settled into position with a rub of the rough handle on the pliers that hold the platinum. This rubbing of the rough handle on the pliers jostles the porcelain particles closer together and makes them float in the water of the dough, so that with skilful manipulation the porcelain can be placed in any shape or position desired. More porcelain paste can be added at will until it comes up to the edges, which should be kept scrupulously clean. The making of the contour is most important and is one of the great tests of the skill and artistic sense of the porcelain worker. After the filled matrix has been carefully dried, by keeping it face downward on a piece of soft muslin, it is placed at the door of an electric furnace, carefully dried until all steam stops rising from it, and then it is placed in the oven and baked until a gloss appears. It is advisable to support the filled matrix on a piece of platinum to prevent its possible adherence to the floor of the furnace.

Fig. 93.—Brush and instrument for handling and molding porcelain paste.

The baking will cause the porcelain to shrink about one-fifth of its bulk. The partly filled matrix must then be removed, allowed to cool, filled once more up to the edges with porcelain, and baked again. A third or fourth baking may be used as needed. After the baking is completed, the filling may be taken from the furnace almost immediately, as practically only very large pieces need to be cooled slowly, although, theoretically, a gradual cooling will make the porcelain tougher. The platinum should now be stripped off, care being taken to pull it away from the edge. Should it be pulled toward the edge, chipping is likely to occur.

If small portions of platinum stick to the porcelain they can be pulled off with a sharp-pointed, tempered instrument or a small, sharp engine bur.

In large or difficult cavities a double burnishing is sometimes advisable. The procedure is as follows: The first addition of the porcelain to the matrix is not allowed to come to the edge. This is baked and cooled. The matrix is put again accurately into the cavity, held immovable, and the edges reburnished.

Inserting the Inlay.—Before cementing the inlay into place, grooves should be made in the porcelain by using a thin copper or steel disk charged with diamond-dust or carborundum powder (Fig. 94). The diamond-dust is incorporated in the metal by a mechanical process, but the carborundum is used as a paste, made with glycerin or cane syrup, in which the disk is immersed

Fig. 94.—Disk charged with diamond-dust.

before the cutting of the porcelain is attempted. The diamond disk is more easily manipulated, but it is also very expensive and wears out quickly, while the loose carborundum and revolving metal disk is sharp and permanently effective for all but the smallest fillings. It is well not to mar the edges of the fillings with the grooves, but this is not now as great an injury as formerly, when only phosphate of zinc cement was available. If there is a slight imperfection in the margins, well-selected silicious cement will fill it so as to make it quite invisible. The disk and porcelain must be kept thoroughly wet while the grooves are being cut, and the grooves should be as deep as the size of the filling will permit, so as to allow the cement to enter and act as a dowel for the attachment of the inlay to the tooth. The mere adhesion of the cement is an uncertain quantity and should not be depended upon to retain the filling in position. For instance, in Fig. 95,

A represents the filling in position; *B* the tooth in which we find the cavity. Such a filling cemented into place with rough sides would be only moderately secure, but if the inlay and tooth cavity were grooved so that the grooves would be opposite each other, as in Fig. 96, the cement would act as a pin, holding the inlay in position in the tooth, and it would only be dislodged by the actual breaking of the cement. Thus, it is evident that greater stability is obtained by large grooves than by the adhesion

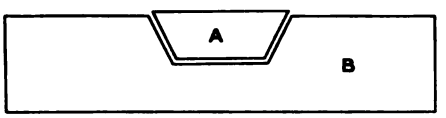

Fig. 95.—Incorrect and insecure method of securing an inlay in position. The inlay here depends upon the adhesion of cement alone.

obtained by merely roughening the inlay and cavity walls. In fact, the nearer we can approximate the shape of a collar-button in shaping the inlay for retention, the greater will be the stability obtained. While the grooves are being cut the inlay should be held so that the edge adjacent to the intended groove may be buried in the skin of the finger. The groove can then be fearlessly made by the swiftly revolving metal disk, that cuts only the hard porcelain and pushes back the yielding tissue of the finger without

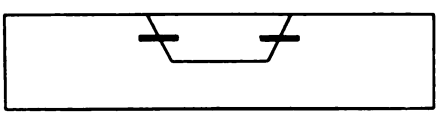

Fig. 96.—Dowel principle of holding an inlay in position with cement.

inflicting injury. With large inlays, where there is plenty of room for the grooves, carborundum disks are most useful. If the porcelain is blackened by the disk the discoloration may be readily removed by a strong jet of water thrown upon it.

The method of inserting the inlay is as follows: The filling and cavity should be washed in alcohol and dried, and the cavity protected by a napkin or rubber-dam. Silicious cement of the proper color should be mixed to the consistency of soft dough

and placed in the cavity, and the inlay picked up with the sticky spatula, placed in position, and settled home by a tapping motion that will rapidly bring the inlay into position. When it is in position the setting of the cement can be hastened by flowing hot paraffin upon it. This setting will be accomplished in a minute or two so that the patient can be dismissed. Wherever it is possible it is well to leave an excess of cement to be polished off at a later visit, as, theoretically, the more thoroughly the cement is protected from the action of the saliva during setting, the more perfect the results. On the following day the edges may be ground with an Arkansas stone or polished with sand-paper. It is better for finishing that the edges of the filling should be a little below the edges of the cavity rather than too high. If, however, the porcelain is too high, it can be ground down and still give good results, but the original gloss, in most cases, is to be preferred.

Cautions.—Having described the general operation of making and putting in a porcelain filling, a few cautions may not be out of place. Overfusing is one of the great causes of poor colors, that is to say, the porcelain should never lose its amorphous consistency. In very deep cavities a bar of porcelain extending through the bottom of the matrix makes a valuable anchorage to which the rest of the porcelain can be advantageously added. In large contours excessive contraction should be overcome by adding 1 part in 4 of ground silex to the part of the porcelain that is to be used for the first baking, as the unfused particles of silex extend across the matrix in every direction, making what is practically an internal investment. When handling small fillings the pliers and cavity may be advantageously kept wet up to the time of insertion, to prevent the filling from being dropped and lost. To place a tiny filling on the operating case in the same relative position that it will take in the tooth prevents mistakes as to which side should go in first.

There are three classes of furnaces that can be used for fusing porcelains—gas, gasoline, and electric. The gas and gasoline furnaces are noisy, odorous, and dirty, and are seldom used where electricity is available. On the other hand, the electric furnace is clean, silent, and beautiful. The best electric furnace for

porcelain, in the author's opinion, is the Hammond crown furnace (Fig. 97). It is so constructed that if a muffle burns out it can be at once replaced by a new one, and the work continued with a loss of not more than fifteen minutes. The various gages for telling when the porcelain is fused are a needless expense. The porcelain worker should learn to fuse porcelain by experience and his eye, not by mechanical appliances, since no mechanical appliance will be able to accurately differentiate the relative time required to fuse a small filling, a crown or a bridge. Such

Fig. 97.—Hammond electric furnace.

appliances tend to dwarf the natural ability of the porcelain worker and through their complexity cause a great waste of valuable time.

The **gold inlay** has practically perfect edge strength, and therefore, on account of this advantage is sometimes to be preferred to the porcelain inlay. This is especially the case when the filling involves a large contour and is to be subjected to a great stress of mastication. It also has the great advantage over porcelain of being capable of serving as an abutment for a

cantilever bridge, but this will be gone into more particularly in the chapter on bridge work.

The gold inlay is easily made and its construction ought not to take over ten or fifteen minutes. This is mentioned because the casting methods and various intricate processes recommended tend to make it a long, tedious, uncertain procedure. These may take hours if not days, to do, with uncertain results, that which a simple method can accomplish in a few minutes. For instance, a simple gold inlay in the buccal surface of a molar ought not to take over five minutes, at most, to complete after the cavity is prepared along the lines previously stated, that is, cup shaped, with sloping sides and a flat bottom, as in Fig. 98.

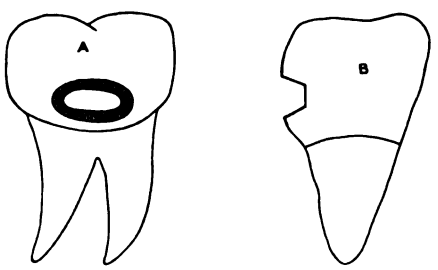

Fig. 98.—Simple cavity prepared for gold inlay: *A* represents external view; *B* represents cross-section.

Soft gold plate, about 0.003 inch in thickness, should be held immovable over the cavity with the fingers and burnished and swaged into position, forming the matrix. Extra immobility can be obtained by molding the gold to the grinding surface of the molar. Then moss fiber or sponge gold should be firmly packed into the gold matrix up to the edges of the cavity, with large pluggers. If the matrix gets wet during the process no harm results. The edges, however, should be kept free from the moss fiber or sponge gold. The filled matrix should then be removed and 22-karat solder flowed into it by adding a few grains of borax and squares of solder and holding it over a Bunsen burner with a pair of pliers. No investment is necessary. The filling should then be cut out of the gold plate, leaving a small margin at the edges. This margin is later polished off when the

filling is cemented into place. The filling and cavity can then be undercut, as previously described, and the filling cemented into place. As before stated, a simple cavity like the one just described would not now be filled with gold, but with silicious cement. The process has been described to show the simplicity

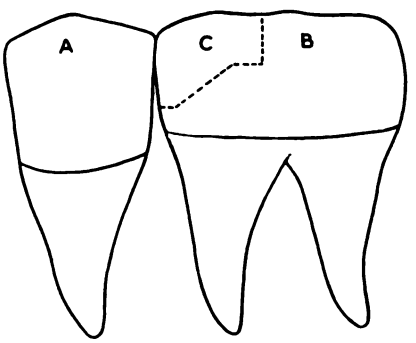

Fig. 99.—A, Lower bicuspid; *B*, lower molar; *C*, gold inlay to be constructed.

of the moss fiber gold matrix method in comparison with the more complicated, intricate casting methods. The place most suitable for a gold inlay is in the compound approximal cavity of a bicuspid or a molar, and as the method of making such a filling is so important, it will be given in detail.

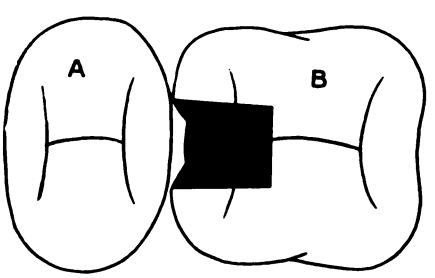

Fig. 100.—Occlusal view of Fig. 99.

Let us take, for example, an inlay for a large cavity in the anterior surface of a first lower molar, such as is shown in Figs. 99 and 100. In Fig. 99, *A* represents the bicuspid against which the contour of the filling is to be made. *B* represents the molar

with the cavity to be filled, and *C* the shape of the completed inlay in position. Figure 100 represents the occlusal aspect of the same cavity. In Fig. 101 the solid lines of *D* and *E* show side and three-quarter views of completed inlay. This is the type of inlay to be used where the pulp is alive, but where the pulp has been removed and the chamber can be utilized for purposes

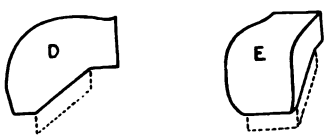

Fig. 101.—Solid lines show shape of inlay for Figs. 99, 100. Dotted lines show projection that may be added when the loss of pulp gives sufficient space, as in Fig. 102.

of retention, the inlay can be constructed according to Fig. 102, which is self-explanatory. The only point of interest is the projecting notch of the inlay that extends into the pulp chamber, which is further demonstrated by the dotted lines in Fig. 101.

The cavity being prepared as shown in Fig. 102, with sloping sides and sufficient space between it and the bicuspid to prevent

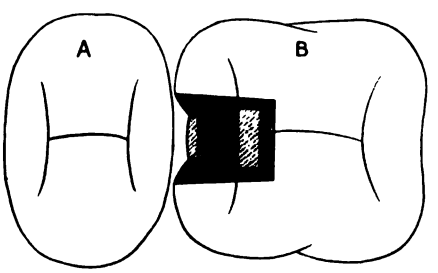

Fig. 102.—Similar to Fig. 100, except that there is an extra depression in the floor, permitting greater possibilities of retention for the inlay.

distortion of the matrix on its removal, soft gold 0.003 inch in thickness should be slipped in between the bicuspid and the molar so that it will project well beyond the lower margin of the cavity that lies next to the gum. Then wet bibulous paper should be packed in between the teeth, forcing the metal well into the

hollow of the cavity. This should be done before the gold foil is bent to the contour of the outside of the tooth. The matrix should then be removed, the gold thoroughly annealed again, when it should be replaced in the cavity and packed firmly with bibulous paper a second time. Then the gold plate should be folded over the side of the tooth and conformed to the top of the tooth so that it assumes the shape of a half-cap. The bibulous paper should then be removed and the gold burnished and spun into all parts of the cavity with a ball burnisher. There will be no difficulty in holding the gold immovable with the thumb and forefinger of the left hand while this is being accomplished. When the matrix is completed a mass of sponge gold should be molded somewhat into the shape of a wedge, having approximately the amount of gold necessary to make the filling. It should be slightly warmed over the Bunsen burner to make it adhesive, and then placed within the matrix while the matrix is in the cavity. Care should be taken to allow some of the sponge gold to rest and infringe upon the grinding surface of the adjacent bicuspid, against the side of which the contour of the inlay must rest. When this has been done the sponge gold must be firmly and rapidly condensed into place with large broad pluggers, care being taken to condense it thoroughly against the contact point of the bicuspid wall and to overlap it partly on the grinding surface of the bicuspid. More gold can be added if necessary, and in a short while a large gold filling can be molded into the proper bite and position. The gold foil and filled inlay can be teased out without destroying the shape of the inlay and the whole filling filled with 22-karat solder, as previously described, by soldering it over a Bunsen burner. If the gold has been well condensed against the adjacent wall of the bicuspid, and the solder is not placed upon the exact contact point, the entire inlay can be filled solidly with solder and then be slipped directly back into position, giving a perfect contact with the bicuspid and making an inlay that can be trimmed and polished in a few minutes. It is advisable to always place the solder on the grinding surface, as this surface will generally need to be ground in any case in order to obtain perfect articulation.

The great advantage of this method lies in the fact that it is so easy to learn, and has such innumerable possibilities in the ease of construction of half crowns, three-quarter crowns, complete crowns with facings, and cantilever bridges; but all of these will be discussed under their respective headings. I was once showing a graduate class the method of making the filling, just described, on a model. After I had shown them once or twice how to make the inlay (it never took over five minutes) one of the students said, "That is all very well with a skilful man, but how about the average dentist?" I answered, "Give me one of your average students." One of the students came forward, and I said to him, "Now, do just as I say, and don't think how you can improve my method before you learn it." And so, under instruction, he also made an inlay in less than five minutes. This is spoken of to show that the method is easy of accomplishment if one will take the trouble to seriously attempt it.

Before closing the subject of gold inlays it might be said that small tears at the bottom of the matrix are of little consequence, as the gold will fill them completely, and it is advisable in filling the matrix with gold not to let the gold extend over the matrix margins. If the edges are kept clean, the filling will be more quickly finished and inserted. It should be especially remembered in undercutting the filling that the grooves should come as nearly as possible opposite the grooves in the tooth cavity, so that the inlay will be keyed into place with good, strong, rigid cement dowels.

Plastic Fillings.—The cement question has been so much discussed in connection with inlays that it might be of value to discuss briefly the relative merits of the phosphate of zinc cements and the silicious cements.

Phosphate of zinc cement is valuable inasmuch as it appears to be more adhesive than silicious cement. It is therefore useful in cementing on attachments to the teeth, such as bands for orthodontia appliances, crowns and bridges. Its adhesive, tenacious quality makes it most valuable as a seal for the retention of antiseptic dressings, but on account of its solubility it has pal-

pably had its day as a filling designed to permanently restore a spot of decay. Of the phosphate of zinc cements, the Harvard cement and the new S. S. White slow-setting cement are the easiest to work and, on account of being more slow in setting, give the best results.

The silicious cements, as before stated, are capable of being mixed to absolutely match the tooth structure to be replaced; they are quickly inserted and are insoluble. Without doubt they represent the greatest single advance the mechanics of dentistry has ever known. The author has had excellent results with both the Ames silicious cement and the synthetic cement. Where the cement powder is coarse, as is the case with the synthetic cement, a very thin cement line can be obtained by cementing the inlay into place with the cement mixed to the consistency of soft dough, and then placing dry powder on the excess that has exuded from the margins of the cavity. When this is done the heavier granules are compressed within the cavity and the more liquid portions are squeezed out, and the addition of the dry powder insures a perfect cement bond on the edge. There are times, however, when a crown or inlay must largely depend upon the adhesion of the cement for its retention, and under these conditions a combination of phosphate of zinc and silicious cements may be advantageously used as a retaining bond. The method is as follows: When the cavity is prepared and dried, the silicious cement should be mixed ready for use. The creamy Harvard cement should then be rapidly prepared and inserted as a cavity lining, and the silicious cement immediately placed on the inlay or crown and pushed into position, forcing out all excess phosphate cement.

Amalgam.—Before the cements reached their present strength and beauty amalgam was sometimes used as a bond for retaining inlays in place. In respect to strength and insolubility it was most trustworthy, but its color tended to cause a shadow in the inlay, that it was almost impossible to counteract, and the dark edge was most unsightly. However, since we are dealing with the possible bonds for inlays it might seem advisable to go into

the methods necessary for the insertion of amalgam, either as a cement or as a filling material.

Let us first examine the philosophy of inserting the amalgam filling. It must set hard, be free from excess mercury, and must have a bacteria-tight margin. A *bacteria-tight margin*, not a water-tight margin, for a water-tight margin around a non-adhesive filling in a moisture-soaked tooth is as much of an impossibility as such a margin would be in a wet sponge. Therefore, what one desires to obtain is a bacteria-tight filling, and with amalgam it makes no difference whether the cavity is wet or dry if only it be kept free from bacteria. On general principles it is better to have a dry cavity than a wet one, but the main thing with the insertion of amalgam is clean, firm, aseptic edges. Then if a cavity whose edges extend under the gums is flooded with alcohol or some other appropriate antiseptic, and this antiseptic is immediately pushed out by the doughy amalgam, which amalgam is dried of its excess mercury by wafered amalgam or, better still, sponge gold, the final results will be just as effective as though the gums had been jammed away from the root by rubber-dam or a matrix and the cavity dried with hot air prior to the insertion of the filling. Since amalgam is not in the least adhesive the cavity must be well undercut in order that there may be good dowel retention. The old method of mixing amalgam powder with a pestle and mortar is quite obsolete. The best method, in the author's opinion, is to put the desired amount of mercury and alloy in a small-sized test-tube. The finger or thumb should then be placed firmly over the end and the contents shaken vigorously for a minute, at the end of which time the resulting mixture should be emptied into the hand, where it can be easily kneaded with a few rubs of the thumb, and the material will be ready for insertion. The formulæ recommended by Black and Flagg for amalgam have given continued satisfaction in the author's practice. The wafering is accomplished by taking some of the excess soft amalgam and squeezing it in a muslin napkin with a pair of pliers until all excess mercury is forced out. The resulting wafer is then added to the soft amalgam filling by means of a spatula moderately heated. The mercury

in the filling will be sucked out into the substance of the wafer, which will become correspondingly soft. The softened wafer can then be shaved off and another wafer used, or the excess mercury in the first wafer can be squeezed out and the wafer applied again and again, until there appears to be no excess mercury in the filling. After this it is well to tamp the filling into the cavity with a large plugger to be sure that all the space formerly occupied by the extracted mercury has been fully replaced by the denser amalgam. This should be accomplished by a tapping motion not unlike the motion used for setting porcelain paste. Amalgam in its pasty condition, before it sets, is similar in consistency to a mixture of sand and water, so if it is merely pushed into position the larger particles will jamb on each other and large unfilled spaces will result. But if, like the porcelain paste, the filling is tapped and jostled, the large particles will float in the liquid mercury and come in closer approximation, while the mercury will rise to the surface, as the water rises to the surface of the porcelain dough when it is similarly jarred for the purpose of condensation. When the last tamping has been accomplished, and enough of the wafer added to ensure perfect contours and edges, sponge gold, slightly warmed to drive off any free moisture, should be pressed upon the surface of the filling until it sticks. The patient is then dismissed. If the gold adheres until he returns it can be polished off; if it does not adhere, it means that there was no excess mercury. In either case the result is a dense filling inserted quickly and painlessly. It is a source of wonder that many dentists still work amalgam in the dry state, when equal if not better results are obtained by using it as a plastic.

The author is aware that the use of a piece of sponge gold that costs from twenty-five cents to a dollar, for the hardening of an amalgam filling, will seem a monstrous extravagance to many dentists who would rather work half an hour or even an hour longer to avoid such "wilful waste," even though they are working over a sensitive, suffering patient.

Amalgam as a Cement.—When an anchorage for a bridge is to be made in an amalgam filling, the pin or gold inlay should

be inserted into the mushy amalgam that has been placed in the cavity. The pin or inlay should then be tapped into position until it settles to its proper level, care being taken that vents have been made on the edges of the inlay sufficiently large to allow the amalgam grains to flow, out or to permit of tamping with a plugger after the application of amalgam wafers or sponge gold has drawn out the excess mercury. Amalgam has also been successfully used to attach facings that have broken away from bicuspid and molar bridges. The technic is as follows: The porcelain is thoroughly undercut with a carborundum or diamond disk, the gold is undercut with fissure and wheel burs, and the soft mushy amalgam is pressed on the porcelain facing, and the facing is pressed into place. The excess amalgam is allowed to squeeze out around the sides, and a piece of sponge gold is plas-

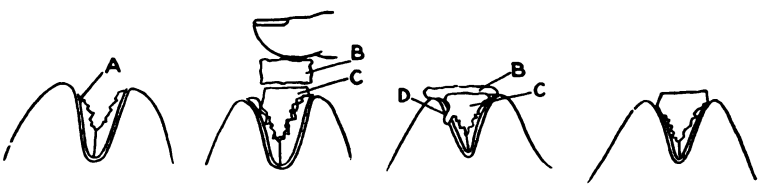

Fig. 103. Fig. 104. Fig. 105. Fig. 106.

Figs. 103–106.—Steps in the sponge-gold process of restoring a broken-down root with amalgam so that it may readily be crowned.

tered over the outside of the amalgam and the facing, and held there until the excess mercury is absorbed. The patient can then be sent away with the gold in position, care being taken to see that it will not interfere with the bite. When the patient returns on the following day the gold can be polished off and the amalgam joint will be found hard and firm. This method is especially valuable in replacing facings for bicuspids and molars where teeth with all-porcelain grinding surfaces are used.

Repair of Broken Roots.—By using the sponge-gold method of extracting the mercury from soft amalgam, roots fractured beneath the gum can be quickly and easily restored so as to form effective abutments for bridges; or in back teeth they can be readily and easily built up to a complete masticating contour. The method is as follows: Figure 103 represents a cross-section

of a broken bicuspid root that has been fractured beneath the gum margin, *A*. The irregular lines represent the cavity prepared inside for the retention of the amalgam that is to restore the gum margin and make the root a suitable, wholesome abutment for a crown or bridge. Amalgam should be prepared as previously described, then the head of the root and gum should be wiped off with 4 per cent. formalin or pure carbolic acid, and the soft amalgam inserted into the cavity of the root and tamped well into all interstices. Wafering, as described, should be done until the amalgam has a stiff, doughy consistency. There should be a final tamping and the amalgam should be smoothed and shaped as in Fig. 104—*B* representing the sponge gold and *C* the amalgam. Then the sponge gold should be pressed down firmly with the thumb, when it will result in a condition as shown

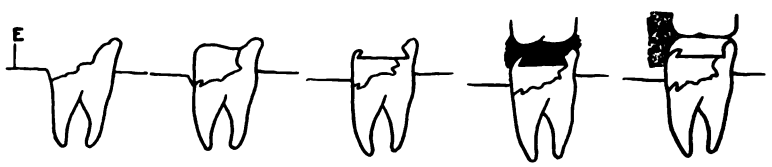

Fig. 107. Fig. 108. Fig. 109. Fig. 110. Fig. 111.

Figs. 107-111.—Same principles can be applied to the restoration of a crown of a tooth.

in Fig. 105. *D* represents the excess amalgam that extends beyond the edge of the root, and must be removed later. The patient may then be sent away, and on the following day the restored root head can be carved with fissure burs and filed to resemble Fig. 106, when a band crown can be made so as not in any way to infringe on the gum.

If a complete amalgam restoration of the crown is desired, as is sometimes the case in back teeth, the following method can be used: Figure 107 represents a molar tooth broken on one side beneath the gum line, as shown by *E*. Figure 108 represents a partial restoration made after the manner of Figs. 103-106. This should be made and finished absolutely free from masticating contact with the occluding tooth before the occlusal surface is formed. Then the amalgam and tooth should be cut to

form a cup (Fig. 109) to receive the second installment of amalgam that should be inserted in a soft condition and tamped into position. The amalgam should be roughly molded to the shape desired and the occluding tooth bitten into it so as to form a perfect occlusion (Fig. 110). It should be carved to shape so that the swing of the jaws will not disturb it, and it must be sufficiently plastic to be molded without breaking. When it is of the proper shape the teeth should be closed and warmed sponge gold pressed firmly on the side, as is shown in Fig. 111. The patient should wait some five minutes with the jaws still. After that he may be sent away with the gold still adherent; if it loosens, it is of little consequence. He should be warned not to bite on the tooth until the following day, when the filling can be trimmed and carved as desired. The necessity for making the filling in two sections arises from the fact that unless the amalgam is supported during the process of crystallization it is easily broken, and therefore it is wise to make the first part entirely free from any possibility of being reached by the occlusal stress of the opposing tooth until it has become absolutely hard. After this has been accomplished the final occlusal surface can be quickly and safely added.

The method of making an amalgam filling with a perfect contour against the adjacent tooth, as is shown in Fig. 112, is easy and simple. *A* represents the sound tooth and *B* the tooth with the cavity to be filled. Care should be taken to prepare the cavity so that there will be good strong margins at the cervical border, and also that there will be ample separation between the decayed tooth and the one against which the contour is to be made. The dotted lines represent the diagrammatic outline of the cavity within the tooth. After the cavity is prepared with suitable undercuts, and dried or flooded with an antiseptic, as may be most feasible, soft amalgam is pressed into the cavity and tamped into all the recesses. If there is an occlusion with the opposing tooth, the teeth should be shut upon the amalgam and the filling carved to the desired shape with a fine lancet or any suitable plastic instrument. It will then resemble the filling *C* in Fig. 112. Then sponge gold can

be pressed upon it, or it can be hardened by wafering, so that all excess mercury is extracted until the filling becomes about as hard as chalk. If the edges of the tooth project slightly above the filling after this has been done, some of the excess amalgam of the filling can be wafered, rolled, and ironed into position with a hot ball burnisher. The patient should be sent away, with instructions not to bite upon the filling for twenty-four hours. When the patient returns, the filling can be polished with fissure burs, sharp lancets, or scrapers, and, finally, by sand-paper disks, but care must be taken not to polish or cut away the actual point of contact between the filling and the adjacent

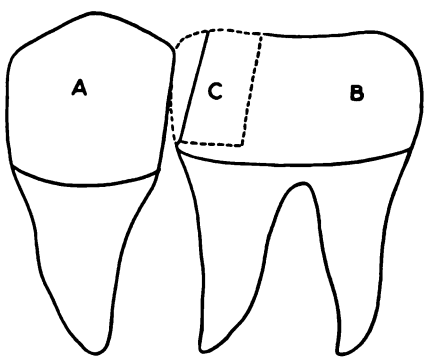

Fig. 112.—Method of building an amalgam contour filling against an adjacent tooth.

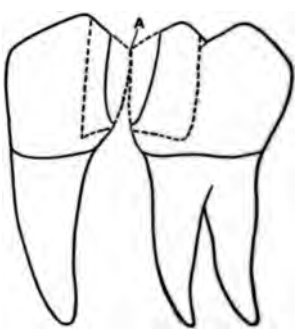

Fig. 113.—Method of building two contour amalgam fillings against each other without aid of matrix.

tooth. Ordinarily the filling can be carved and polished without separation, by careful carving up to the contact point, for the contact point is polished by being forced against the polished enamel of the adjacent tooth. Finally, all rough or sharp edges can be eliminated by passing a fine band-saw between the filling and the tooth, which will push them apart and reduce all edges, so that floss-silk will jam sharply as it is passed over the contact point, but will otherwise have free passage for its daily duty of cleansing the interdental space.

If two cavities oppose each other, as in Fig. 113, one may be built up to the proper contour, as previously described, and

polished at some future sitting, when the second can be inserted, or they can both be filled at once as a common filling. The wafer or sponge gold should be used until the amalgam has become chalk-like, then the two fillings can be carved to have a common contact point. A fine steel band-saw should be passed through the contact point *A* and the fillings entirely separated. Then the mouth should be rinsed with water. After this the two fillings should be ironed into absolute contact at the contact point with a hot ball burnisher. They will not join, as the water will act as a bar against their union. After this the patient can be dismissed, and the fillings polished and finished at the next sitting.

Gutta-percha has been used as a bond for inlays, crowns, and bridges, and therefore, in order to finish the discussion of various cements and also the various filling materials, gutta-percha will next be considered. When used as a cement for an inlay, a little hard gutta-percha should be placed in the dried undercuts of the cavity and spread with a hot instrument evenly over the entire surface as a lining. Then it should be wet, and the inlay, without undercuts, should be pressed upon it with a hot instrument until the gutta-percha flows out of the margins to a considerable extent. Then the inlay should be removed and the excess gutta-percha should be ironed off by the sharp edge of a hot plastic instrument, care being taken to always iron it toward the edge. The inlay should be inserted a second time and the process repeated until the inlay is almost in position. Then it should be removed and the undercuts made. The surface of the gutta-percha should be dried and the inlay inserted and sent home with a hot instrument, all excess gutta-percha being removed with a sharp knife and a pellet of cotton soaked in a gutta-percha solvent, such as oil of cajuput, oil of eucalyptus, or chloroform.

This use of gutta-percha, however, in the light of our present cements is obsolete, and it is now seldom used except for temporary attachments or for crowns or bridges where there is a possibility that they may need to be removed in case of re-infection due to lack of cleanliness or to low bacterial resistance. When a crown is to be set in gutta-percha the cavity in the root should be

beveled and kept moist so that the gutta-percha can be easily removed during the process of fitting. The base of the crown and the pin, if it has one, are then undercut and thoroughly dried. They are then slightly moistened with oil of cajuput or eucalyptus and white base-plate gutta-percha placed on the pin or within the band. The crown is heated and pressed into position as far as possible on the root, which should be wet. When the gutta-percha is cold the crown should be removed, which is easily accomplished, and the excess gutta-percha trimmed off and the process repeated until the crown goes absolutely into position. Then it is removed, the gutta-percha dried, the root dried, slightly roughened and moistened with oil of cajuput, and the crown heated and pressed into position. It should be held firmly in place for a minute or two and then the patient dismissed, being told not to bite upon it for an hour or two. After that time it will be firm, but at any time heat from a hot instrument applied to the outside will make its removal easy. The same principle applies to the insertion of bridges with gutta-percha, although, as a matter of fact, the author has not used this method of retention oftener than once or twice a year during the past ten years of practice.

Gutta-percha is a most valuable filling for cavities where decay is progressing rapidly and it is difficult to determine just how much can be saved and just how much should be cut away. If the tooth is soaked in carbolic acid or formalin and filled with gutta-percha, at the end of about a month a permanent filling can be inserted with much greater chance of success than if the temporary gutta-percha had not been used. The fact that the temporary filling gives us an opportunity for repeated sterilization is, of course, a great advantage. In addition to its permitting of resterilization, gutta-percha is particularly valuable as a packing in between teeth where the teeth are too close together and inflamed gum has worked into the cavity. In such cases if the gutta-percha is inserted after a moderate excavation the force of mastication will cause it to spread the teeth and force the gum out of the cavity, so that ample room can be obtained for a good interdental space. This separation ordinarily takes

about three months after the filling has been inserted and causes no pain.

Gutta-percha has a wonderful property of becoming very hard and adhesive. It would seem that a sort of vulcanizing takes place, making a filling that at times seems not unlike cement. The great disadvantage about gutta-percha lies in the fact that in time it will disintegrate and discolor. This process is very slow, but nevertheless steady, and therefore the other filling materials under ordinary circumstances are to be preferred where durability is to be desired.

CHAPTER VIII

CHILDREN'S TEETH

The Theory of Gum Lancing in Infants. Care of the Teeth and Gums After the Eruption of the Temporary Second Molars.

Gum Lancing.—"Teething is a natural process and assistance by lancing is unnecessary." This is the stock objection raised by the opponents of this time-honored procedure, but it should be remembered that the same objection would hold with the same force against assisting nature with forceps during parturition. Many physicians maintain that retarded dentition is seldom, if ever, a cause of the bowel complaints and the general nervous condition and malnutrition that are so common among children during their first and second summers. It is claimed that lancing forms scar-tissue in the gums that retards the eruption of the teeth. And it is also claimed that many a child suffering from colic, scurvy, and a hundred and one of the ordinary infantile ailments has been uselessly lacerated with a lancet, and the little sufferer's pain, far from being stilled, was actually increased.

There is no doubt a child suffering with incipient measles, small-pox, scarlet fever, or even a misplaced pin would not be benefited by having its gums lanced, but when the child during its dentition period suffers from malnutrition, bowel disorders, restlessness and fretfulness, or shrieks without apparent cause, it is a rash physician who would be absolutely sure that dentition is not one of the underlying causes of these distressing symptoms, even though the gums may appear perfectly normal. It should be remembered that the pain of teething does not arise from the pressure of the tooth upon the gum, but that the pressure of the gum upon the tooth causes the pain by creating pressure upon the underlying nerve. A single retarded wisdom tooth in an

adult may cause such pain and nervous shock that the bowels will be violently disturbed and there will be high fever, all of which symptoms will disappear when the entire grinding surface of the offending molar is freed from its overhanging tooth capsule. The pressure of the tooth capsule on the posterior cusp alone may cause these symptoms, all the other cusps being free.

The same condition has been noted in children of six or twelve years during the eruption of the sixth- and twelfth-year molars. The restraint of the posterior cusp alone by a tough gum may in these cases cause profound nervous excitability with its concomitant physical disturbances. These disturbances are easily diagnosed because the patient is intelligent enough to explain. Therefore, in the case of a screaming, colicky, feverish infant who cannot explain, and who possibly has not only one but eight teeth pressing on the dental pulps, how unfair it is to the child to ignore the fact that difficult dentition may be the underlying cause of all the trouble.

Since we know that one single cusp of an unerupted sixth-year molar often causes distressing systemic symptoms that can be instantly removed by lancing, the failure frequently encountered by physicians in obtaining relief after lancing is no doubt often due to imperfect technic in lancing. Unless the dental capsule covering the cusps of an erupting tooth is dissected absolutely clear of it, so as to relieve all back pressure on the nerve by the gum, lancing may cause no relief whatever. With wisdom teeth covered by a large mass of gum it is sometimes necessary after the gum has been dissected to burn the capsule away with trichloracetic acid. When this is done, even though the gum still overlies the tooth, relief is at once obtained. Many physicians fail to appreciate that the only value in lancing lies in completely dissecting the tooth free from the dental capsule. The complete lancing of incisors and canines of teething infants, to the expert, presents few difficulties, as the lancet can readily be passed all around the cutting edge of the tooth beneath the gum, but in the case of a deep-seated molar the overlying block of gum must be completely removed and the capsule absolutely cleared if the physician is to be assured that that particular

tooth may not continue to be a cause of reflex systemic disturbance. And where, as is often the case, four molars may be under suspicion at the same time, and the teeth are far under the gum, it is a nice question to decide how much surgery is justified. It has been the author's experience that lancing of even four molars at a time not only causes no shock to the child but results in almost immediate relief. However, the full history of the child must be taken into consideration, and all infantile disturbances should not be attributed in bulk to faulty dentition.

The question of scar-tissue formed by lancing has not been seriously discussed, as ordinarily the tooth erupts long before scar-tissue sufficiently dense to interfere can be formed; and if scar-tissue does form the great relief obtained by judicious lancing more than compensates for the possible necessity of a second or even a third lancing.

Care of Children's Teeth and Gums.—Unless the child has been very badly nourished during gestation, or within the first few years of childhood suffers either from malnutrition or some disease such as measles or scarlet fever, the first and even the second teeth, the wisdom teeth excepted, are likely to erupt sound and normal. The formation period of the enamel of all but the wisdom teeth lies within these few years, and if the enamel is well formed prior to its emergence from the gum, the tooth will have every opportunity for perfect development as the roots and dentin go on forming after it is erupted. But with the enamel this is not so, for when the tooth emerges from the gum the enamel organ dies and no more enamel can be formed. The formed enamel can harden or soften according to its nature, as shown in Chapter III, but with the emergence of the tooth from the gum growth in the enamel ceases forever. The enamel first forms at the tips of the cusps or cutting surfaces of the teeth, as in Fig. 114, the formed enamel being shown by the shaded portion, and it frequently happens that the permanent molars erupt before the pits or fissures in the grinding surfaces are completely closed, thus destroying the enamel organ before its work is completed. Sometimes although the bottom of the pits or fissures are covered with solid enamel, the fissure itself is partly filled

with a soft material that acts as a special lodgment for infection. Therefore, the first thing a dentist should do when a child is brought to him is to carefully examine all the pits and fissures with a fine, sharp piano-wire explorer. The wire is not hard enough to penetrate into normal enamel, and so, when jammed into each suspected place, if it sticks on being withdrawn, the dentist can be assured that there is a soft spot which should be polished out with a stone or bur until the explorer no longer sticks. Normal mastication of food will keep the bottom polished and will absolutely prevent decay. The fissure must be made self-cleansing, and if the enamel is penetrated entirely the softened structure must be entirely removed and a cement filling inserted. This procedure will not weary the child and will enable the tooth to safely mature, when it can be filled in a more permanent manner. In any case it is not a bad procedure to flow a thin layer of



Fig. 114.—Showing diagrammatically formation of enamel at upper surface of the dental capsule, the white portion being yet soft and gelatinous.

phosphate of zinc cement into the grooves after the polishing is completed. This makes the tooth smooth to the action of the tongue and gives an excellent opportunity for the cut enamel to gradually harden as the cement dissolves. I speak of the enamel hardening, for the results of my experiments, as given in Chapter III, indicate that enamel is harder on the surface than underneath, and when it is cut the exposed surface becomes hard also—a sort of case-hardening process that renders it resistant to attrition and yet not liable to fracture. At least, whatever the explanation may be, the above-mentioned procedure gives excellent results, and when the cement is worn or washed away by the saliva the tooth performs its functions satisfactorily without further filling.

If this has been done carefully as soon as the teeth erupted and the teeth are not deformed, and if floss-silk and tooth-brush are used as described in Chapter II, the teeth and gums should



Fig. 115.—Carborundum stones used for polishing grooves and softened enamel in children's teeth.

always be free from decay and infection. But, as a matter of fact. the floss-silk and tooth-brush will seldom be used as recommended. Parents should not only tell the children to brush the teeth and to use floss-silk, but should see that the children do it properly.

Otherwise the bacteria will collect against the enamel and remain undisturbed indefinitely, and finally cavities of decay will appear in the temporary teeth. When the spots of decay are small and have not infected the pulps they can be made comparatively harmless, since they can be cut out and filled with amalgam, gutta-percha, or cement. Then if the parents take heed, and see that the teeth are properly cleansed with floss-silk and tooth-brush, the child may grow to maturity and have a perfectly healthy set of teeth. But if a pulp in a temporary tooth becomes infected so that the pulp has to be removed, we are face to face with one of the most serious and difficult problems in dentistry. And the worst part of the whole miserable dilemma lies in the fact that it is so easily preventable by proper cleansing. Any mother who brushes a child's teeth properly and uses floss-silk carefully three minutes a day is giving the child years of health and vigorous maturity. The only proviso is that she must do it, or see that it is done, *every day*, not every other day or once a week. Nor does it assist matters when decay has penetrated to the pulp to hear her exclaim, "Well, I told him to brush his teeth!" To think that the poor dentist has to listen to such drivel day in and day out! Tell a child of seven, eight, or ten to brush his teeth! A child of eight or ten does not wish to brush his teeth, does not know how, and won't do it even if he is taught, unless he is coaxed and made to do it; and yet it is ordinarily during these years that the enamel becomes permanently infected and the foundation for firmly intrenched mouth infection is laid. The fundamental cause of mouth infection is, first, ignorance on the part of the parents, and after that laziness or overwork; for it is quite conceivable that a mother of six young children may readily prefer to send the children to the dentist twice a year, and put the responsibility on him, than to go through with the great ordeal of seeing that over one hundred teeth are carefully flossed and brushed each day. And yet if she really knew the good she would do them and the money she would save, I am sure the ordinary mother would gladly see that her children's teeth were kept clean.

However, let us suppose the evil is done, and the child is

brought to us, when seven or eight years old, with cavities in the temporary teeth that have extended until the pulp is exposed, and well-defined spots of decay have started in the sixth-year molars and the central incisors. The child's gums are usually inflamed and the teeth coated with white masses of bacterial deposits. The first essential is to gain the confidence of the child. It is well to merely cleanse the child's teeth at the first visit, and show him how to use the tooth-brush. The tooth-brush should be small and of the size and design shown in Fig. 7, and, above all, should be dipped in hot water and allowed to cool prior to its first use on the sensitive gums. This will prevent too great irritation and will not discourage the child from coming again. The movements to be used in brushing the teeth are given in Chapter II. The child should also be taught to use floss-silk, as previously stated, in order that the bacterial masses may be removed from between the teeth once at least, if not twice, daily. The silk should be held in the manner described in Chapter II. *This is most important.* The taut part should be pressed down between the tooth surfaces of each interdental space, sweeping one side going in, traversing firmly across the gum, and then sweeping the side of the adjacent tooth going out. This is not a simple operation; it requires instruction and patience if it is to be mastered, and nothing but careful training on the part of the dentist and parents will make the child have either the knowledge or the will to do it properly. The next thing is to remove the green stain that is usually found on the teeth by first flowing a little tincture of iodin on them and then polishing with brush and pumice. Never, if it can possibly be avoided, should a child be hurt on his first visit, and at no time should a child be taxed beyond the easy limit of his endurance. Of course, if a child comes to a dentist with an abscessed tooth, the opening of it may hurt, but no more pain should be inflicted than is absolutely necessary to give relief. On the second visit a small cavity of decay may be filled. This should be accomplished by carefully yet rapidly cutting out the decay with a swift sweep of a rapidly revolving sharp bur. It should never take over a few seconds to accomplish this, and if the child is permitted

to hold the napkin around the tooth with his fingers while the work is being done, it is astonishing how readily and even cheerfully he will bear the necessary pain. The mere fact that the child is assisting by holding the napkin distracts his attention. It is astonishing how quickly a child responds to the sympathy of the dentist who really loves children and desires to assist them. Those who are not capable of feeling this sympathy laugh and scoff at such a claim, but it has been my experience that children treated lovingly and honestly, skilfully and quickly, are the best patients a dentist can have, and when their confidence is gained they will bear with fortitude pain that would make an older person wince. The main essentials in dealing with children is never to deceive them, never to overtax their power of resistance, and never to fail to let them see that you care for them personally, but with it all to make them feel that they must obey. If a thing has to be done, persuade and coax the child if necessary, but see that it is done before he leaves the chair. And it will be a great proof of a dentist's discretion to plan for any one visit an efficient course of procedure that will not overtax the child's power of endurance.

When the cavity of decay in a temporary tooth has been excavated, the tooth should be filled so that it will last four or five years, or until it comes out to make room for its successor. In such a case the putting on of rubber-dam or jamming the gum with clamps is folly. The amalgam, cement, or gutta-percha should be prepared for use according to the material to be used, and then the napkin should be applied and the child told to hold it in position. Then the cavity should be quickly wiped out with a pellet of cotton moistened with carbolic acid or nitrate of silver, and the filling at once inserted. If amalgam is used the antiseptic will do good, and if the cement or gutta-percha are deemed desirable the small amount of moisture due to the antiseptic film will be only a theoretic objection, especially if the cavity contains judicious undercuts. The same procedure applies to filling the permanent teeth of a child. Gutta-percha and cements can certainly tide the child over the formative period of the dental roots and pulps, and then operations of

greater length, if necessary, can be performed. It will be noted that this gentleness and firmness applies to mature patients as well as children, but it is especially essential in the control of children. A doctor who is not a thorough humanitarian has no right to call himself a doctor. A doctor was once talking to a bright woman about the doctor's life, and after the late hours, loss of sleep, and constant worry had been gone over, the woman said, "Well, medicine is certainly a very poor business." "Quite true, madam," was the response, "but it is a very fine profession." And so the dentist who perpetrates mechanical operations of unnecessarily tedious length is not a surgeon, but a mechanic, and should confine his efforts to the workbench, not to the sensitive human tissues.

Exposed Pulp in Temporary Teeth.—When the dentist finds a temporary tooth, usually one of the molars, with a cavity that has involved the pulp he is confronted with a problem that will tax his ability to its utmost. It is difficult to treat and fill the canals of a permanent molar, but with the temporary molar the canals not only have to be treated and filled, but they have to be filled with a root filling that will absorb as the roots absorb, when the permanent tooth beneath begins to emerge to take its place. If the pulp is alive it should be anesthetized by means of the novocain pressure method, as described in Chapter VI, and should then be thoroughly removed from the canals by Beutelrock drills and the piano-wire broaches. Then Buckley's mixture of formalin and tricresol should be sealed in with cement and the little patient dismissed. It is wise to wait a full month in order to be sure that the irritation of the root tips has entirely subsided. When the patient returns the napkin or cotton roll can be applied either with the clamp or held by the child, and the filling and dressing removed by a swiftly revolving drill. The same treatment should again be repeated, and within a week the root canals should be permanently filled in the following manner: The filling and dressing should be removed as before, hot air should be applied, and the canals quickly dried. Then a paste of oil of cloves and oxid of zinc should be flowed and lightly tamped into the canals. Any excess

oil of cloves should be absorbed by a suitable amount of oxid of zinc added to the pulp chamber. All excess can be wiped or scraped from the pulp chamber, and the tooth can be filled with any suitable material, such as amalgam, cement, or gutta-percha. Of course, chloro-percha and gutta-percha can be used in the root canal, but the oil of cloves seems to give the best results and has the property of being absorbed with the rest of the root as the permanent tooth underneath erupts. The best way, however, is to prevent the decay of the tooth before it starts by seeing that its entire surface is kept clean with floss-silk and the tooth-brush.

Fractured Teeth.—One of the most distressing accidents that can happen to children's teeth is the fracture of a newly erupted permanent tooth that exposes the pulp long before it has completed its task of forming the tip of the root. It is almost invariably one or both of the upper central incisors that is fractured. Sometimes the fracture is almost enough to expose the pulp, but not quite. The pink of the pulp vessels may be just visible through the fractured surface, and yet the pulp may not be exposed. Under such conditions the fractured surface should be wiped off with pure carbolic acid, thoroughly dried, and a film of thin cement flowed over it and allowed to harden. This may protect the pulp so that it will continue its life for three or four years or until the root is fully formed, when the tooth can be restored to its normal color and contour by a skilfully applied porcelain filling. In the meantime, if desired, the tooth may be temporarily restored with cement. But when the pulp is exposed so that its death is imperative, it is wise to apply novocain and remove the pulp at once. When this has been accomplished and the soft parts have been thoroughly removed, it is frequently found that the entire tooth is composed of little more than enamel and cementum, the dentin being almost entirely missing. The pulp chamber instead of being minute, as it would have been if the tooth had matured, is a large canal with its diameter varying from 0.125 inch at the fractured edge to 0.0625 inch at the root tip. And what is of more serious consequence, the tip of the root is so imperfectly developed and so full of organic material that in

the course of time it is sure to be partly absorbed, and therefore if it is thoroughly filled to the end, such absorption will leave a projecting root-canal filling. On the other hand, if the foramen is not filled to the end the force of mastication will drive the sharp edges of the partly formed apical foramen into the tissues, making an irritation that is almost certain to cause an infection which will result in a chronic alveolar abscess. Under such conditions the tooth and root should be carefully studied with the *x*-ray, a hard tube being used for the differentiation of the hard calcic portions of the tooth and a soft tube being used to bring out the soft tissues, as represented by inflammatory or alveolar degeneration. This will be of incalculable value in determining the depth of the root-canal filling. The pulp chamber should be thoroughly sterilized with applications of pure carbolic acid, followed by a 4 per cent. aqueous formaldehyd solution, which should be sealed in with phosphate cement. If an abscess has formed at the tip it is advisable to squeeze into it a drop or two of pure carbolic acid by filling the canal full and then making pressure on the external opening with a ball of soft, unvulcanized rubber. After this has been accomplished a cotton dressing should be inserted and the tooth sealed up with cement for about a week. When the child returns, careful measurements of the root outline should be made on the *x*-ray plate, and these should be compared with similar measurements made on the tooth, so that the exact size and length of the pulp canal from the broken edge to the apical foramen can be ascertained. Then the upper part of the canal should be filled with a plug of gutta-percha, care being taken that it accurately fits the apical foramen. This is a very nice procedure, as is shown by the illustration (Fig. 116). *A* represents the broken tooth; *B* and *C*, the normal adjacent teeth. The dotted lines show the outline of the pulp

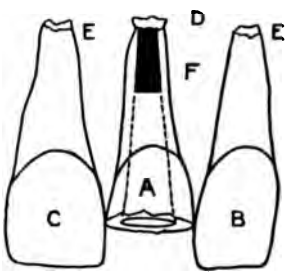

Fig. 116.—Diagrammatic illustration of a child's broken central incisor with the adjacent teeth.

chamber and apical foramen. *D* represents the area of softened inflamed tissue at the end of root. *E* represents the uncalcified portions of the normal tips of the adjacent teeth. The black area, *F*, represents the position the gutta-percha should take. If a small short cone of gutta-percha is thrust into the canal on the end of a probe it will go completely through the tip into the tissues, making an added source of irritation, and if a large bulky piece of gutta-percha is jammed into the canal the chances are that it will not reach the foramen at all. The only practical way out of such a dilemma is to see that the root canal is absolutely conical to the tip. This can be accomplished by a suitable reamer. Then, while the canal is allowed to remain wet with a 2 per cent. formaldehyd solution, a piece of gutta-percha is molded into a cone approximately the correct size, heated slightly, and pushed with a large probe as far into the canal as it will go. It should then be allowed to cool. Then it should be withdrawn on the end of the probe, slightly heated again, and pushed in again and once more allowed to cool. So long as the canal is wet the removal of the cone will be easy. This should be tried again and again until the measurements show that the solid cone of gutta-percha has passed the end of the conical root canal and has sealed it perfectly. Then the cone should be once more withdrawn, a scratch having been first made on the probe opposite the broken edge of the tooth. Then a careful measurement of the exact distance of the foramen from the broken edge of the tooth should be made with another probe having a hooked tip. The depth should be compared with that of the *x*-ray plate and the exact distance should be marked off on the gutta-percha from the scratch on the probe and the excess gutta-percha cut off. When that has been done the cone on the probe should be allowed to cool and the root canal thoroughly dried with hot air and moistened with oil of eucalyptus on a shred of cotton. Then the gutta-percha cone and the probe should be inserted into the tooth firmly up to the mark on the probe, which ought to bring the gutta-percha exactly to the end of the root canal. The gutta-percha probe can then be left in position for a minute or two in order that the oil of eucalyptus may make a

firm union between the gutta-percha and the tooth. Then a hot instrument should be placed against the probe within the tooth cavity. This will heat the metal so that it can readily be withdrawn, leaving the gutta-percha cone in position. After the probe has been withdrawn the hole in the gutta-percha can be filled up by tamping the gutta-percha into position with a hot instrument, leaving the tip of the root evenly sealed. On the following day another *x*-ray can be taken, and if the gutta-percha is not absolutely in position it can be pushed a little further with hot instruments, for it is better that it should extend from the orifice very slightly than to allow the undeveloped foramen to be unfilled. The tooth can then be bleached as described in Chapter VI, and a porcelain tip made to restore the tooth to its normal length.

The ideal surgical treatment of the tip, of course, would be to go through the alveolar process with a bone drill and amputate the end of the root, leaving the gutta-percha smooth and even; but at the age of seven, eight, or nine the mouth is too full of the underlying permanent teeth, and the jaw-bone is too small in its development to safely attempt such a procedure. It is better to coax such a broken tooth along, soothing any inflammatory outbreaks with iodin and other quieting treatment until the jaw is more fully developed. Then at the age of fourteen, if the tip is not in a healthy condition, root amputation with novocain can be undertaken with every possibility of permanent good results.

ORTHODONTIA FOR THE GENERAL PRACTITIONER OF DENTISTRY

The straightening of children's teeth has undergone a great revolution during the last twenty years, and has developed from a haphazard, hit-or-miss procedure, that frequently resulted in more harm than good, into a precise science that produces permanent results. And strange to say, the originator of the fundamental principles underlying the modern method was a Frenchman who lived some two hundred years ago—Pierre Fauchard, the father of professionalism in dentistry. He scorned

that human suffering should be made a field for selfish commercial exploitation, and therefore freely told of his discoveries to all who would listen, when each fellow-worker was guarding his secret as personal property. Among Pierre Fauchard's many discoveries was the expansion arch which is now generally accepted as the best means of straightening crooked teeth. His plan was to attach to the teeth an arch of spring wire of the shape that the human arch ought to assume, and then, by ligatures, to draw the teeth into position and hold them there, letting the arch act also as a retention appliance. But, like most great ideas, his plan was too simple and direct to be understood or accepted. After his death the expansion arch was neglected and forgotten. Later, practitioners in straightening one tooth frequently made another crooked with appliances of great complexity and size. These appliances frequently injured the gums and teeth permanently because it was impossible to keep them clean. Moreover, the later dentists almost invariably started to straighten by casually extracting a few, which made facial distortions and malocclusions that were ten times worse than if the patient had never seen a dentist.

But about twenty years ago Angle, of St. Louis, Baker, of Boston, and Case, of Chicago, all awoke to the advantages of the expansion arch, and it was shortly afterward that the Angle School of Orthodontia was started. Angle made appliances that were of almost universal application, and he classified the various procedures, by which crooked teeth could be straightened with quickness and precision. A conscientious old dentist of the old school once said at a dental meeting that he had been paid thousands of dollars for straightening children's teeth, and he regretted to say that the teeth had never remained straight, and that untold harm had resulted from the regulating appliances, and therefore the money paid had been more than wasted. Naturally, he was opposed to straightening teeth. And in the light of the work he had done this old gentleman was quite correct. But the work started by Fauchard and carried on by Angle was a work that converted chaos into order, hideousness and disease into beauty and health. The principles laid down by

Angle and his co-workers were that the teeth were created by a better intelligence than theirs, and if there were thirty-two permanent teeth it was better to utilize all of them and learn their design and proper relation than to extract some teeth and then plan what should be done with the rest. Angle formulated the theory that the teeth did not grow to fit the face, but the face grew to fit the teeth. It was discovered that if the teeth could be made to assume their true, normal arch the rest of the face would develop to corresponding symmetry and beauty. Also that the arch of the teeth was the keystone on which the development of the upper bones of the face and forehead depended. If the arch was constricted, the openings in the nose were lessened or even closed, preventing proper breathing. The passage of the air through the nose being cut off, air pressure was not exerted in the various sinuses of the face, and therefore this important stimulant to facial development was weakened or entirely missing. And so the new school of orthodontia started out with the endeavor to understand nature's plan and to cooperate with it.

Thirty years ago it was the invariable rule never to start to straighten teeth until the permanent canines had fully erupted. Now, in the light of Angle's work, every dentist knows or ought to know that when the canines have emerged from the gum it is almost too late to do effective work. At least it will take four or five times the amount of work and consequent pain and suffering, to accomplish a harmonious result, that it would have taken if the teeth had been placed in their true positions before the canines erupted. This is so because the canines are now known to lock the arches into their permanent positions. Formerly, the dentist pulled and yanked the teeth hither and yon in a vain hope that with the help of Providence and a little luck they would come straight. The aim of even the most advanced practitioners was to get the teeth of a child into the position they should assume in an adult, and to hold them rigidly in place until the child grew up. Thus all expansion and development of the facial bones was hampered, and it is not surprising that they began to revert to their former irregularity as soon as the

appliances were removed. The great advance made by Angle and his followers lay in the fundamental idea that the teeth should be made to develop along normal lines, and in the formulation of a fundamental law that governed such development. Nature's shifting of the permanent teeth into the positions of the temporary teeth during the development of a child is a stupendous engineering feat not surpassed by that of a railroad that changes all its tracks and grades without interrupting traffic. The wonder lies not in the fact that the second teeth should occasionally come in crooked when they replace the first teeth, but that they would ever be able to replace them at all with perfect occluding arches. When it is appreciated that before the child is seven years old, all of the full-sized crowns of the permanent teeth, the wisdom teeth excepted, are packed away in the small face, and that without disturbing mastication or nutrition the roots of the first teeth must be absorbed, and the replacing large second teeth must emerge into graceful lines from their crowded position as the face develops, the wonder of it is beyond comprehension. Such a magnificent engineering feat is worthy of the Master Mind.

Having grasped the idea that the process of dentition is the result of a wonderful engineering plan, it can then be appreciated that a little hardening of the bone by inflammation, or a little extra resistance of the capsule in eruption, or a little retardation of bone development by lack of nutrition or disease may readily result in producing discord. Therefore, it is not for the dentist to attempt to pull or push the teeth into adult position, but merely to assist the great plan of nature when accident is obviously retarding or defeating it. A tooth pulled or wrenched from its fully developed socket into a new position in the bone will obviously tend to return to that socket; but if during the formative stage of the alveolar process, before the permanent socket is established, the tooth is guided into the normal position, the natural process of development and the focusing of the normal forces of mastication will obviously keep it in position. The dentist must not fight against nature's plan and supplant it with a new one, but he must study the underlying controlling

factors of dentition and supplement them where necessary. The underlying principles governing successful dentition are comparatively simple if assistance is given before the teeth are fully erupted and their bony alveoli are in the formative stage. The fundamental law is that the full normal width of the arch from sixth-year molar to sixth-year molar must be maintained and that the cusps or planes of the upper teeth should always bite exterior to the respective cusps or planes of the lower teeth; that the anterior cusp of the lower first molar should occlude

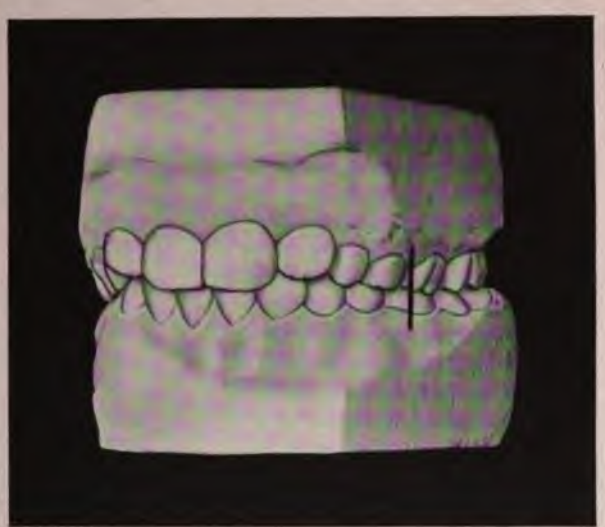

Fig. 117.—Left side of normal arch of a boy of seven years.

anterior to the upper first molar, and the lower four incisors should always come inside of the upper incisors and be made to evenly assume the full width of the line of the arch. If this is accomplished and this position maintained until the permanent lower canines come in unrotated at the extreme ends of the erupted lower incisors, the teeth will be locked in a normal position and will mold the upper teeth accordingly.

Case No. 1 (Figs. 117–119) represents the arches of a boy of seven whose teeth fulfil the law. The formulation of this law has completely revolutionized the science of straightening teeth.

The teeth of young growing children should only be disturbed when they do not conform to the tenets of this law. Teeth that are apparently out of place, but developing along the true plan of dentition should be left undisturbed because they will event-

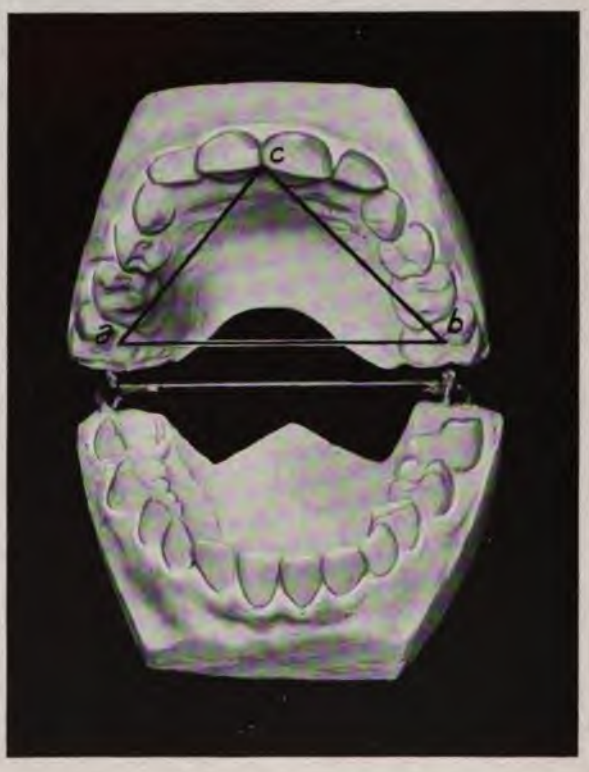

Fig. 118.—Normal open arches of a boy of seven years. Triangle *a–b–c* is a valuable guide in determining whether the dental arch is sufficiently wide to insure satisfactory future development. It should be measured either on cast or on the actual arches with a pair of dividers. Base line *a–b*, extending from the anterior sulci of first permanent upper molars, should exceed by 15 to 20 per cent. either line *a–c* or *b–c*, which meet at the median line of the central incisors.

ually straighten themselves, but if the cutting edge of an upper molar starts to slip inside the lower arch, or the anterior cusp of the upper first molar starts to slip anterior to the anterior cusp of the lower first molar, or the line of the lower four in-

cisors is not even and true and inside the upper incisors, then it becomes the duty of the dentist in charge to correct these deformities at once. He must not wait until the canines emerge, nor must he wait until there is a convenient time to accomplish the work; he must remedy the tendency at once in order that normal dentition may go on undisturbed. In addition to violations of the law just set forth, there may be pathologic bone complications or inhibition of bone development, there may be mouth-breathing and adenoids, and various unknown factors

Fig. 119.—Right side of a normal arch of a boy of seven years.

of faulty dentition, but in 90 per cent. of the cases of malocclusion the sole cause of serious deformity arises because the correct relations of the few teeth essential in the law just quoted are not maintained.

And so, while it is wise and just that the child who is far advanced in malocclusion should go to the orthodontist who makes a specialty of this branch of dentistry, the prevention of malocclusion should rest with the general practitioner of dentistry, who, watching the child between the ages of four and twelve, should see to it that the first upper permanent

molars bite buccally and posteriorly to the lower first permanent molars, that the lower permanent incisors erupt in and maintain an unbroken arch, and that no upper tooth is ever allowed to erupt lingually to a lower tooth, and that the lower canines erupt unrotated at the extreme ends of the perfect line of the lower incisors. Since it is the main responsibility of the general practitioner of dentistry to see to it that this fundamental law is not allowed to be transgressed, it shall now be specifically pointed out just how these tendencies should be corrected, and the times that they usually appear.

It must not be forgotten that inflammation of the gums and decay of the temporary teeth have a marked influence on the forces governing accurate dentition. If the first teeth decay, and are thereby lessened in width or are lost, the space they should occupy is also lessened, and there is a corresponding tendency for the jaw to be constricted so that the space for the second teeth will be endangered. Also if the pulps of the temporary teeth are diseased or destroyed, the roots do not absorb normally at their appointed time, and thus the normal eruption of the permanent teeth is disturbed. These factors alone may cause malocclusion. Therefore the first and most important obligation of the dentist is to see that the temporary teeth are kept clean and free from decay. If they are in serious malocclusion, and it sometimes happens that they are, it may occasionally be necessary to start at the age of four or five to coax them into position, but ordinarily it is better to wait at least until the age of six or seven, when the first permanent molars and the permanent lower incisors have appeared through the gums. This is especially true because a perfectly occluding set of temporary teeth does not by any means insure a perfect occlusion of the permanent teeth, and, therefore, if there seems to be a fairly normal line occupied by the temporary teeth it is better to wait; but if the temporary teeth are badly cramped or the lower teeth are biting outside of the upper teeth, expansion of the arch and reduction of the deformity should be started at once. This is especially important, since the permanent teeth lie beneath the temporary teeth, and the adjustment of the tempo-

rary teeth, in many instances, will actually draw the permanent teeth into normal position. Often the case that appears very difficult, and, without doubt, would develop most unfortunately, with a little study can be remedied at once, or at least so modified that the child will remedy the baneful tendency by its own natural movements in biting.

Take, for instance, Case 2 (Fig. 120). It is the mouth of a little girl of five years who from thumb-sucking has forced out the upper incisors, and in so doing has pushed back the entire

Fig. 120.—Case 2, little girl of five years whose jaw has been forced back by thumb-sucking. The molars have the same relative positions on both sides of the jaw.

lower jaw, as can be seen by the position of the first molars. The extent of the malocclusion is shown by the lines indicating where the true occlusion should be. It looks like a very serious and difficult case, but it was remedied in a very simple, easy way. It was found that if the lower jaw was slipped forward, as in Fig. 121, the deformity instantly disappeared. Bands were fitted and cemented on the lower first molar with wire lugs on the side, and then bands were fitted on the upper molars with extensions that made it impossible for the little girl to close her mouth unless she kept her jaw forward in the right position. It hap-

pened that this little girl had a strong, persistent bite and usually kept her teeth together, so this simple device entirely remedied her trouble, and the permanent dentition progressed normally. If she had been a mouth-breather with her mouth constantly open, the assistance given by the tendency to keep the teeth together would have been lacking, and the Baker anchorage would have been necessary. This anchorage will be described later on. It was found of great advantage to grind the teeth with an engine stone so that there would be accurate articulation in their new position. This is frequently an essential procedure

Fig. 121.—Case 2 restored to normal occlusion.

in such cases, and as the teeth are to be lost later their deformity is of no consequence. When the upper deciduous centrals came out, as they did in a short time, the change to the new position had been easily accepted by the child's jaw and soon became the normal position.

Case No. 3 (Figs. 122–124), as can be seen, also showed a marked dropping back of the lower jaw with protrusion of the front teeth. In this instance, as the child was only a month or two over four years old, it was decided that it would be dangerous to allow the deformity to increase up to the age of seven. It was found that the lower jaw could be moved forward into proper

Fig. 122.—Case 3, little girl of four years whose lower jaw has slipped back into posterior occlusion. Right side.

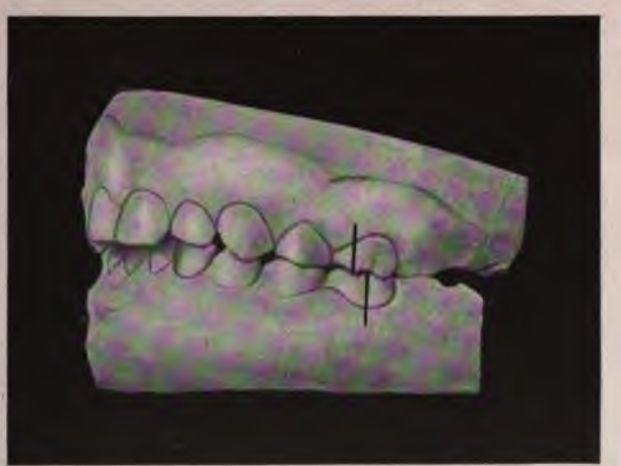

Fig. 123.—Case 3, little girl of four years whose lower jaw has slipped back into posterior occlusion. Left side.

position, as in Fig. 125. Therefore, thin caps of pure gold were adjusted to the upper canines, and projections were built on them on the lingual surface with sponge gold and solder so that the

Fig. 124.—Case 3.

Fig. 125.—Case 3 restored to normal occlusion by gold caps on the canines.

jaws could not go back without striking the projections. In fact, the only way the child could get her teeth together was by keeping the jaw forward in the normal position. This she did so successfully that when the permanent teeth came in there was hardly any further straightening to be done.

When, however, as in Case No. 4, the lower second molar on only one side of the jaw is posterior to its upper fellow, the other side being normal, it may be difficult or impossible for the

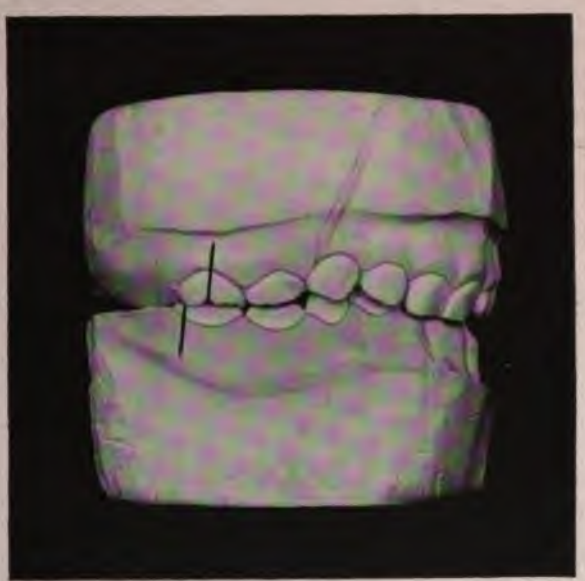

Fig. 126.—Case 4, little girl of five years with the second lower molar on only one side in posterior occlusion, the left side being normal.

child to shift the jaws so that the occlusal planes of both sides will engage normally (Figs. 126, 127). As the Baker anchorage is to be required in any event, it may be simpler to wait until the first permanent molars appear and get them also into position, because, as before stated, when the temporary molars are in normal position such a fact gives no guarantee that the permanent molars will likewise erupt in normal position. The only sure fact in these cases is that when the occlusion of the temporary

molars is abnormal the occlusion of the permanent molars will surely be abnormal.

The next case, No. 5, is typical of a great number, and is an exact reproduction at an older age of the conditions found in Case No. 3. If it is taken in hand properly the irregularity is capable of easy, permanent remedy; while if it is allowed to drift, it is impossible to foretell what deformity may result. Figures 128 and 129 show both sides with the lower molars in distal occlusion to the upper, while the individual arches in themselves are

Fig. 127.—Case 4, left side, showing normal occlusion.

normal in shape. Figure 130 shows the lower jaw extended so that the arches are in good occlusion. Therefore the only thing necessary is to train the jaws and coax the teeth into this position. As the patient had a tendency to keep the mouth open, the method used in Cases 2 and 3 was not available, so the Baker anchorage was used. Since this anchorage is of such importance, a minute description of it will now be undertaken.

Until about twenty years ago it was the writer's habit to make many curious appliances for remedying the defects of

Fig. 128.

Fig. 129.

Figs. 128, 129.—Case 5, child of eight years. Lower jaw in posterior occlusion to upper jaw.

irregularity, but since then he has accepted the principles and appliances advised by Angle, and therefore the Angle appliances

for accomplishing these results will be described. While, of course, necessary modifications have to be made in each individual case, they should be made according to the principles laid down by Angle. The Baker anchorage consists of appliances shown in Figs. 131 and 132—an expansion arch and the bands supplied with screw-thread and nut for attaching them to the teeth. The author finds it better to make a simple band that fits the molars to be moved and to solder the tubes on the side, thus making the appliance smoother to the tongue than if the tight-

Fig. 130.—Case 5, teeth in normal occlusion, cure being accomplished by the Baker anchorage.

ening screw and nut were used. This band can be cemented into position and the expansion arch adjusted, as shown in Fig. 132. Little hooks, like the one shown in Fig. 132, must be slipped on the upper arch and soft soldered, so that they will be situated just opposite the canines. A couple of ligatures of silk or brass wire should be passed around the arch and incisors so as to keep the arch from bending under the traction strain, and the rubber bands attached as in the illustration. I shall not go minutely into the description of how these Angle appliances are made and

adjusted, as Angle's works are universally known, and those who desire fuller details are referred to them.

Suffice it to say, then, that the Baker anchorage was applied, and in a few months the jaws and teeth permanently took the position shown in Fig. 130. Here all the requirements of the

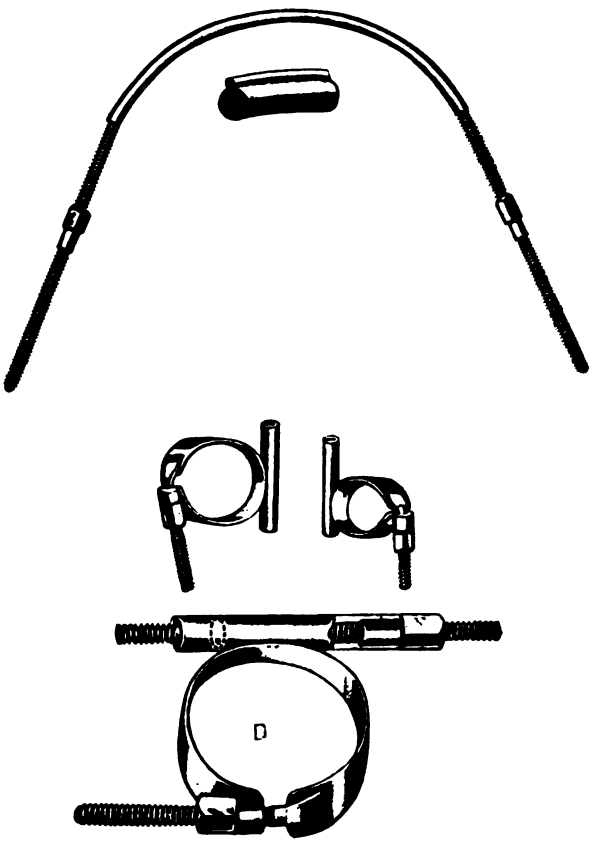

Fig. 131.—Expansion arch and retention bands devised by Angle.

fundamental law were fulfilled—the lower molars occluded anterior and lingually to the upper molars, the four lower front teeth in even, full arch occluded lingually to the upper teeth, and there was every reason to expect the permanent canines to come into proper position at the ends of the four lower incisors, which

they eventually did, and the case is now developing in good occlusion.

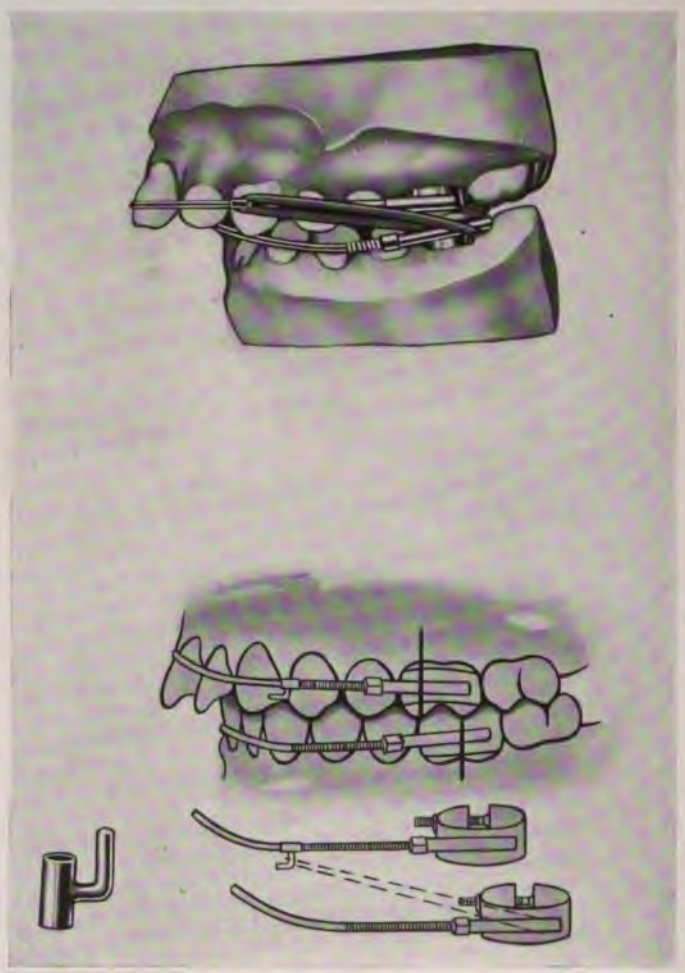

Fig. 132.—Baker anchorage.

Case No. 6 is similar to Case No. 5, except that the incisors have not scissored past each other, and it required the same appliance and treatment (Figs. 133–135). The molar occlusion on the left side was normal. When the lower teeth on

Fig. 133.—Case 6, right side only in posterior occlusion, necessitating Baker anchorage.

Fig. 134.—Case 6, showing normal occlusion on left side.

the right side were coaxed forward judiciously the central and lateral upper incisors dropped naturally and permanently into

their normal positions. It ought to be stated here that where the upper and lower incisors have scissored past each other beyond the limit of normal occlusion the molars should, if necessary, be built up with cement to permit of a normal occlusion of the front teeth.

Fig. 135.—Case 6, showing the curve of the arches of both upper and lower jaws.

Case No. 7, as seen in Figs. 136–138, is of the same type as Case No. 4, except that the arch of the upper incisors has been broken by the pressure of the upper lip. The same treatment as that of Cases No. 4 and 5 will suffice, except that the broken

Fig. 136.—Case 7, malocclusion arises in a great degree from irregularity of lower front teeth as well as from the posterior occlusion of left lower permanent molar.

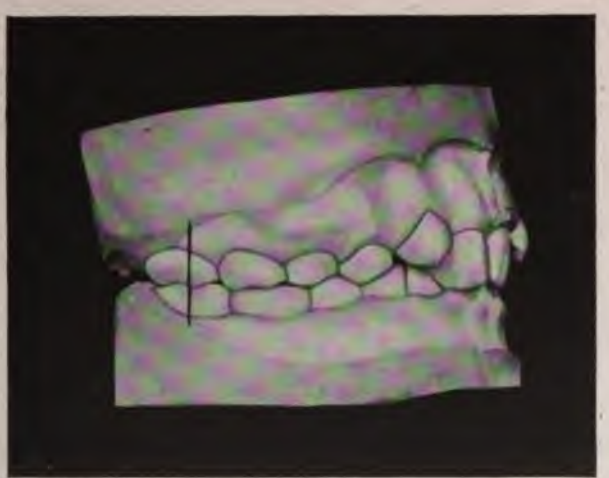

Fig. 137.—Case 7.

arch of the upper central and lateral incisors must be restored so that it will fit the lower arch.

Case No. 8 deals with complications caused by unevenness in the line of the lower permanent incisors. This sort of irregularity is, by all odds, the most common and requires the most careful watching on the part of the dentist. It appears between the ages of seven and eight. The permanent molars have erupted and on both sides are in normal occlusion; left side is shown in Fig. 139. It will be noted that where the molars are in proper

Fig. 138.—Case 7.

occlusion the loss of the right deciduous molar is a handicap, for the space must be maintained until the permanent bicuspid erupts, but the principal difficulty lies in the reconstruction of the lower arch. In this case expansion arches, as shown in Fig. 131, were adjusted on both upper and lower jaws, but the rubber loops were not used, as the permanent molars were in normal

occlusion. The space between the upper temporary canines was widened to permit the occlusion of the full, even arch of the lower incisors and lower temporary canines, which alignment was accomplished at the same time by simply making the arches the size and shape desired and drawing the teeth to them with loops of twisted silk or brass wire made for the purpose.

The beauty of such simple appliances is to be found in the fact that they can also be used for retention. Between the ages of six and ten no attempt at permanent retention is sensible, as it retards development. We simply get the teeth into the posi-

Fig. 139.—Case 8, principal factor of malocclusion is the unevenness of lower incisors.

tion demanded by the law and hold them until they lose their tendency to return to their old position, and then let them go, hoping that the development will proceed along normal lines. I seldom hold any child's teeth in a fixed position for over six months at a time. That is usually sufficient to give them the proper developmental push. The general practitioner of dentistry is like a riverman guiding a log down the river. He pushes the teeth, when they get jammed or stalled, out into the stream of natural development, and feels that he must constantly watch their progress along the shoals and eddies of childhood and pu-

berty until they reach the final jam and haven in the perfect arch. And in so doing his task is easier than that of the orthodontist. If the general practitioner of dentistry watches each stage of development his work is seldom if ever likely to involve any but the simplest problems, and will lead to perfect results; while the orthodontist, not ordinarily seeing the child until a

Fig. 140.—Case 8. Here again we have the triangle laid out showing by the base line *a–b* that the arch is sufficiently wide.

deformity is well established, has often titanic difficulties in a period when developmental forces are slackening, when the bony tissues are mostly formed, for better or for worse, and the demands of school, college, and society are wont to be considered by the parents of far more consequence than the advantages arising from straight arches. In Case 8 the child's appliances were kept

on for six months and the mother was instructed to see that they were kept clean—not "brush them," but see that they were kept clean by examining where the appliances and teeth were dirty and cleansing them with a small brush. At the end of that time the appliances were removed and the development was allowed to proceed, with every chance of the haven of normal occlusion being reached.

Contraction of the arch is a prominent cause of progressive irregularity both in the mouth and nose, and it should be noted

Fig. 141.—Case 9. Contracted arch.

and remedied at the earliest moment possible. A safe and practical test to show whether a child's arch should be expanded is to lay out such a triangle as is shown in the upper arch of Figs. 140 and 143. Figure 140 represents a normal width, while that of Fig. 143 is contracted. The base line extends between the fossæ *a–b* of the first permanent molars. The triangle sides are obtained by drawing the lines *a–c* and *b–c* to the median line at the cutting edge of the central incisors. If there is to be sufficient room for the normal alignment of the teeth in the arch the base line, *a–b*, should always be from 15 to 20 per cent. greater

than the length of either of the lines *a–c* or *b–c*. If the upper and lower arches are synchronously expanded by appliances a little too much it will cause no harm, for the erupting teeth will be forced into their proper relations by the pressure of the cheeks, but if the arch is contracted there will not be sufficient space for the unbroken curve of the front teeth. It will be noted that although Case No. 9 has a contracted arch its treatment is practically similar to that of Case No. 8.

Let us now take up Case No. 9 (Figs. 141–143). Here we have a condition similar to Case No. 8 except, in addition to the irregu-

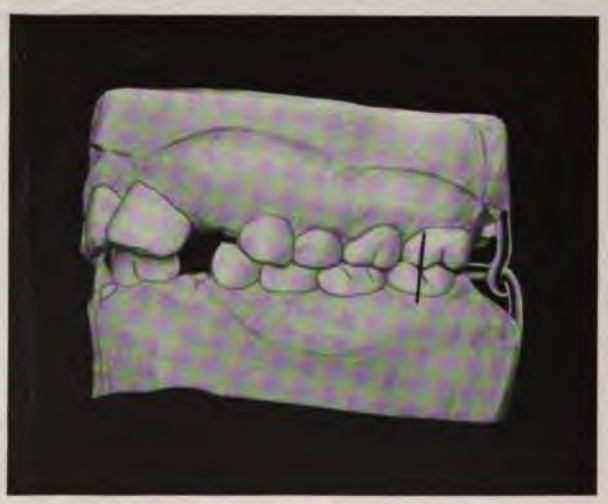

Fig. 142.—Case 9.

larity of the teeth, we have the contracted arch just mentioned. The wire expansion arches were bent so as to give the desired width *a–b* from molar to molar, and then were put on in the ordinary way; then, while the upper and lower deciduous canines were being rotated and pulled into position by means of twisted silk tied to the expansion arch, the natural arches were being spread at the same time by the slow steady spring of the expansion arch. If a supplementary spring within the arch is needed in these cases, it can be used. It will be noted that the procedures in all these cases were simple and ordinarily easy of performance

because the regulating was undertaken during the formative period. But had the teeth been allowed to develop along abnormal lines it is hard to imagine the extent of the irregularities that might have resulted. In all of these cases only one type of

Fig. 143.—Case 9. Here the base line of the triangle *a–b* is hardly longer than either of the other two sides, and the arches must be widened 15 or 20 per cent.

appliance was necessary, namely, the expansion arch, originated by Fauchard and perfected by Angle and Baker.

Case No. 10, as shown in Figs. 144 and 145, presents a problem almost identical with that of Case No. 8, except that the right lower first permanent molar is in slightly distal occlusion to its upper fellow, as shown in Fig. 144. On the left side, which is not shown,

Fig. 144.

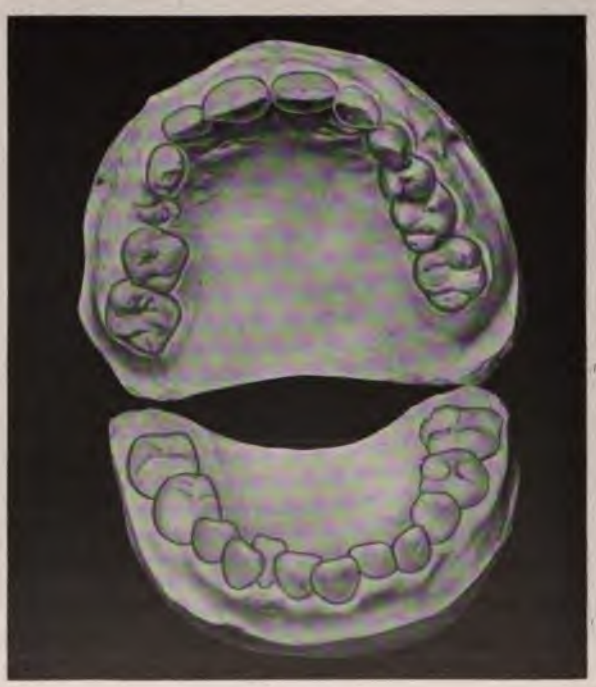

Fig. 145.

Figs. 144, 145.—Case 10. Malocclusion largely caused by unevenness of lower incisors and the premature loss of right upper first molar.

Fig. 146.—Case 11, abnormality caused by irregularity of lower incisors.

Fig. 147.—Case 11.

the occlusion is normal. As will be seen in Fig. 145, the arch of the upper incisors is good, while the lower incisors are jammed

into a broken line, as was the case with Case No. 8. While it took only three months to permanently remedy the defects of Case No. 8, it took a year and a half to coax the teeth of Case No. 10 into normal occlusion. The difference lay, first, in the fact that the permanent molars of Case No. 8 were in perfect occlusion,

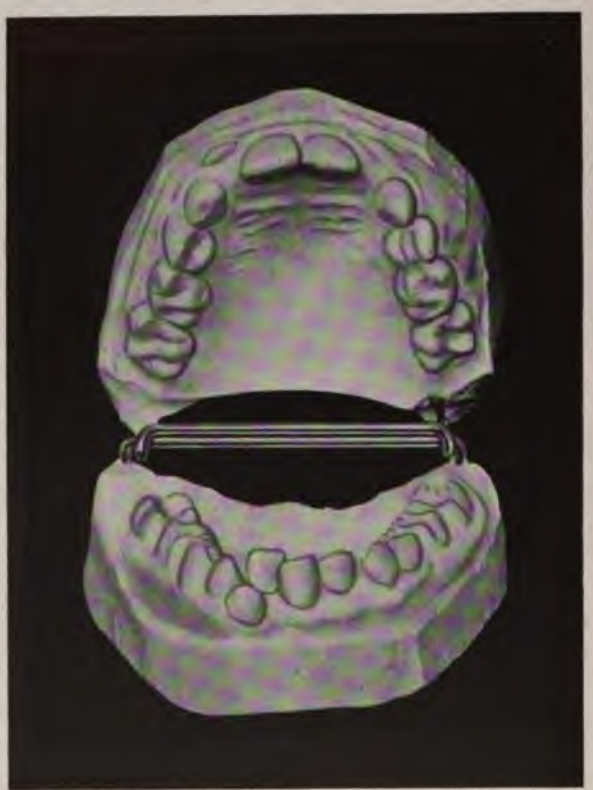

Fig. 148.—Case 11.

while the right permanent molars of Case No. 10 were in abnormal occlusion. Also the tissues of the child of No. 8 were healthy and showed progressive development, while in the case of No. 10 development of the tissues was slow, so that progress in pulling the teeth into shape had to be gradual and tedious. The right lower temporary canine of Case No. 10 was lost too soon from

the strain of moving, necessitating constant care and watching so that the space could be maintained until the permanent canine came into position, and last, but of special consequence, was the fact that the first child in every way possible gave sympathetic assistance, while the second child apparently lay awake nights thinking how she could devise fancy bites that would break the rubber bands and loosen the apparatus. Needless to say progress was very slow until one day the child was caught delib-

Fig. 149.—Case 12, irregularity caused by protrusion of the frenum of lip between upper central incisors and also a slipping of left upper teeth inside of left lower teeth.

erately biting the rubber band that had just been adjusted. It was with difficulty that the indulgent mother was made to realize that the secret antagonism of the child was the chief cause of the slow progress. But when this was realized and remedied, the case was finished without undue delay, and it is strongly recommended that all dentists be on their guard against such idiosyncrasies.

Case No. 11 (Figs. 146–148) is similar to No. 8. The occlusion of the first permanent molars was normal. The expansion arches

were adjusted, the distance between the canines slowly increased to give room to the lower teeth, and the lower four incisors were moved to a normal, even curve, with the deciduous canines at the ends in their normal positions.

The irregularity of Case No. 12 is due to two factors: First, as is shown in Figs. 149–151, the upper left temporary teeth from

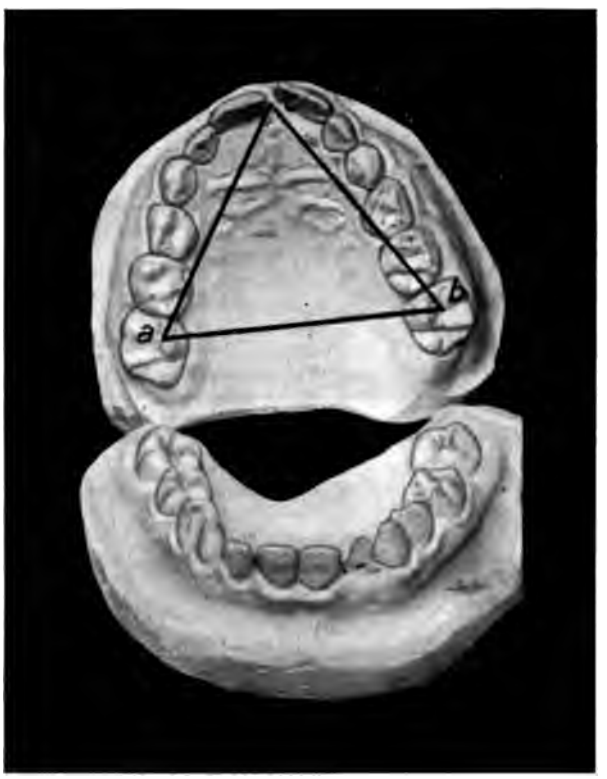

Fig. 150.—Case 12

the canines back are biting inside the lower left temporary teeth; this causes a narrowing of the upper arch, as can be seen by the relatively short line *a–b* (Fig. 150). This condition can be remedied by upper and lower expansion bars. The second factor in this case is a cause of distortion that has not been mentioned before, and that will, if left undisturbed, constantly defeat our

best efforts. This factor is the extension of the frenum of the lip between the upper central incisors in between the two superior maxillary bones, causing a constantly increasing space between the upper central incisors and a tendency for them to rotate. Again we must thank Dr. Angle for the discovery of the cause of this deformity and for the remedy. This frenum must be extirpated, for otherwise the movement of the lip pulling on the spongy tissue between the front teeth will always tend to

Fig. 151.—Case 12.

distort them, no matter how often we bring the teeth together and no matter how long we hold them in normal position.

Extirpation of the Frenum.—Novocain and suprarenin are injected into the frenum, and also deep in between the superior maxillary bones, until the adjacent region is white and insensitive. Then the frenum is dissected up to the junction of the gum and lip. After that is done a fissure bur, No. 17 B. & S. gage, is plunged into the articulation of the superior maxillary bones and brought down along the median line until the interdental space between the upper central incisors has been completely

bored out and the membranous junction between the bones has been completely severed and drilled away. It is most important that the point at which the bur enters should be high up in the median line. After the bleeding has stopped a drop or two of trichloracetic acid can be flowed into the wound to completely cauterize the remaining shreds. After the wound has healed we can then complete the case with the expansion arch, as pre-

Fig. 152.—Case 12 completed.

viously described. It will be noted from the size of the triangle base that the arch is slightly contracted. Figure 152 represents the case four years later, showing the permanency of the operation.

Case No. 13, as is shown in Figs. 153–155, and Case No. 14, Figs. 156, 157, are complicated by the frenum growing between the upper central incisors. When this is removed, as just described, there will be no difficulty in making the teeth permanently assume their normal occlusion.

Fig. 153.—Case 13, irregularity caused by frenum of lip growing between upper central incisors.

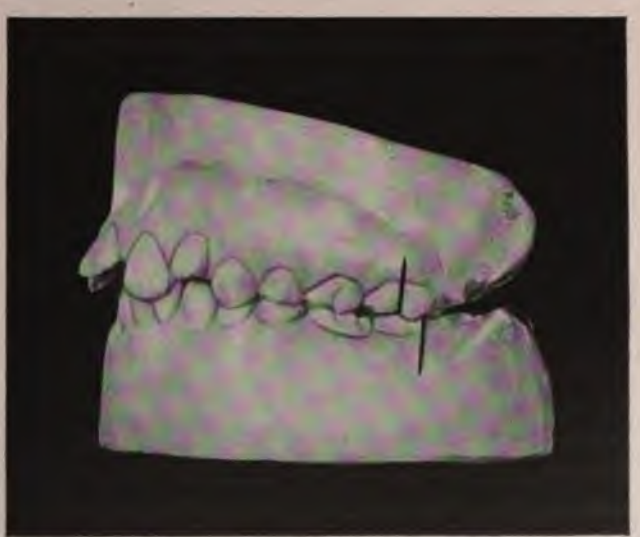

Fig. 154.—Case 13.

Impaction of Teeth.—We now come to the discussion of irregularities complicated or caused by the impactions of permanent teeth, as is shown in Case No. 15, Figs. 158–160. This is a very interesting case, and at first glance seems normal. The molars, upper and lower, are in proper occlusion and the teeth appear to be within the influences of their respective planes. But a closer inspection will show that the temporary

Fig. 155.—Case 13.

upper canines are still in position, with great widening of the spaces between the upper lateral and central incisors. An *x*-ray showed that the permanent canines had been diverted lingually by the ends of the roots of temporary canines that, unfortunately, were not absorbing normally. The permanent canines, therefore, were forced within the arch and were being held there by the thick, rigid palatal process of the superior maxillary bones. Figure 158 shows two slight elevations, marked with rings, beneath

Fig. 156.—Case 14, complicated by frenum of lip penetrating between upper incisors.

Fig. 157.—Case 14.

which the impacted teeth lie. The patient was a girl of fourteen years. The temporary canines were extracted and the gums and bone over the impacted canines were cut and burred away and the tips of the impacted teeth exposed. This operation was performed under nitrous oxid gas and oxygen, but the author now prefers local anesthesia, as previously described. Trichloracetic acid was applied immediately after the operation, and in two

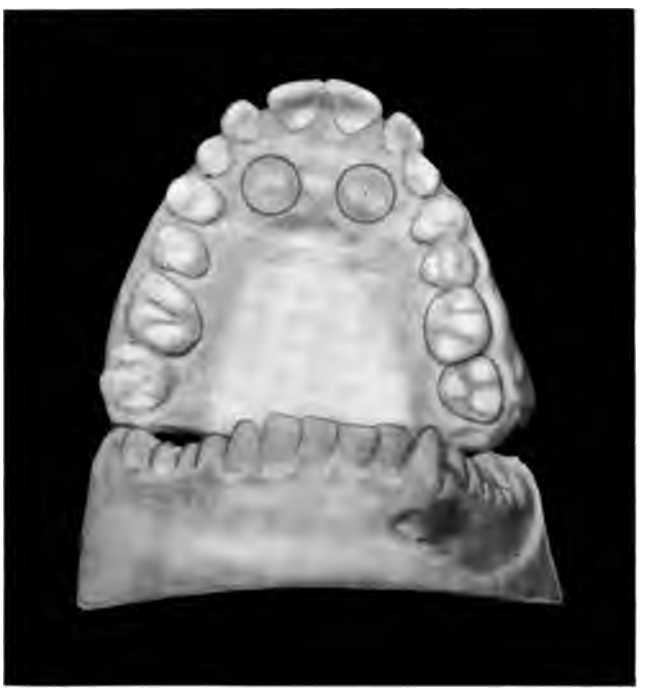

Fig. 158.—Case 15, deformity caused by impacted canines.

days the gum and membrane over the tips of the impacted canines had completely cleared away and the enamel of the canines was in plain view. An expansion arch was then placed on the upper teeth and from it rubber loops were judiciously attached to the laterals, pulling mesially, and also to the first bicuspids, pulling distally toward the molars, and by these rubber ligatures the full space required for the passage of the canines

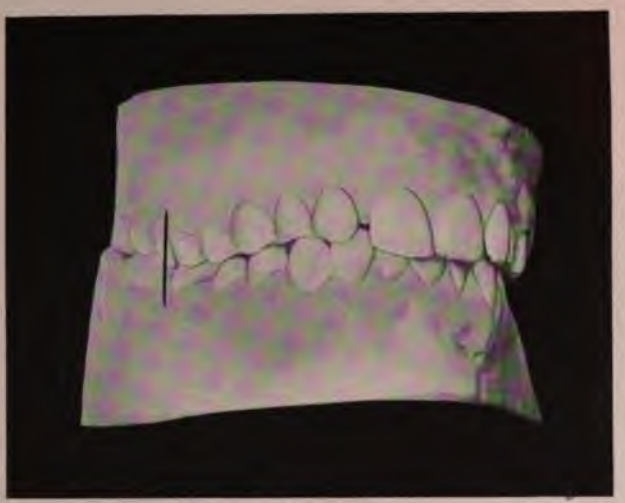

Fig. 159.—Case 15.

Fig. 160.—Case 15.

from the interior to the exterior of the arch was obtained in due time. Then a How screw was inserted in the lingual plane of each canine near the tip, and rubber loops fastened to the screws

Fig. 161.—Angle device for causing eruption of an unerupted misplaced canine.

Fig. 162.—Case 16, girl of ten years. Malocclusion caused principally by early loss of temporary teeth, resulting in impaction of upper right canine marked by circle (*A*) and lower first bicuspid marked by circle (*B*).

and carried around the expansion bar and back to the screw. In this way the canines were pulled down and through the space formerly occupied by the deciduous canines that had been ex-

tracted. When the canines were brought into a position external to the arch the bands were removed and the teeth came into normal occlusion by their own propulsive force. If they had not come properly, the ingenious device of Dr. Angle shown in

Fig. 163.—Case 16.

Fig. 161 would have been necessary. When the teeth were erupted the screws were removed and the cavities filled.

Case No. 16 represents a serious deformity in a little girl of ten years arising primarily from the lack of development caused by measles during infancy, and scarlet fever at the age of four. The marks of these diseases can readily be seen by examining

the incisors and canines in Figs. 162–164. In addition to injury done to the unerupted teeth by the skin diseases, it will be noted that irregularity arises primarily from the premature loss of the temporary upper canine on the right side and of the temporary first lower molar on the left side. The loss of these two teeth caused the permanent lateral incisor on the right side to fall toward the first molar, impacting the permanent canine, which is located by the circle *A*, Figs. 162–164. The loss of the lower left first temporary molar caused a contraction of the arch which

Fig. 164.—Case 16.

resulted in the impaction of the first lower bicuspid, as located by the circle *B*, Figs. 162, 163. The lesson to be learned from this case is twofold: First, if the temporary teeth had been preserved there would have been no malposition; second, if the patient had come for treatment before the age of eight the deformity could have been remedied in months, whereas it took years to bring the teeth permanently into proper position. It will be noted in Figs. 162 and 164 that the first molars are in normal occlusion and in Fig. 163 that the arches are not con-

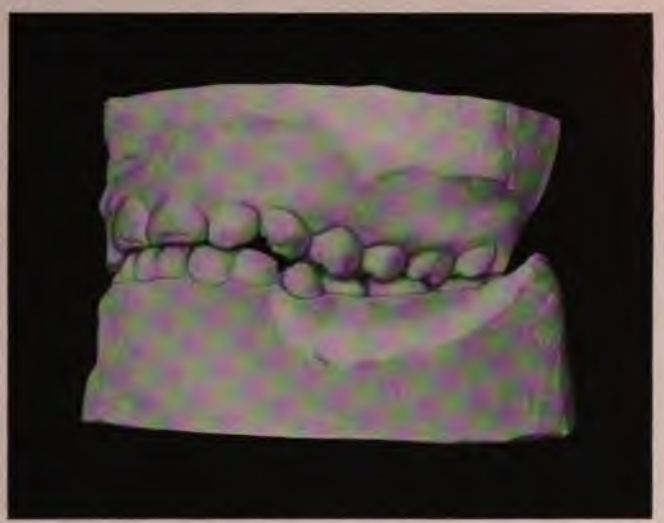

Fig. 165.—Case 16.

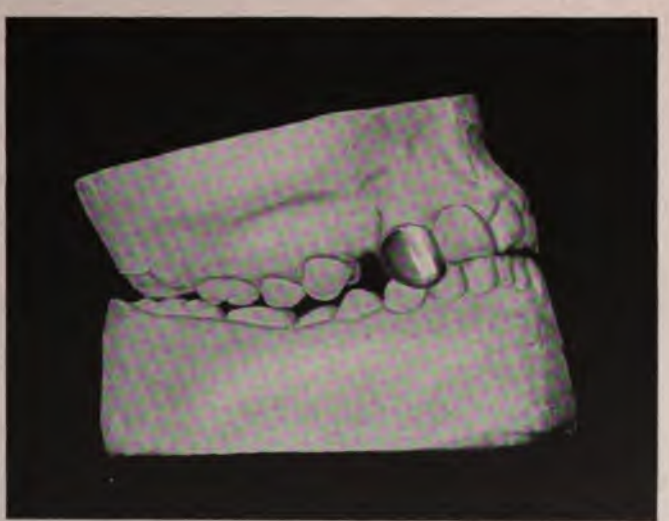

Fig. 166.—Case 16, at the age of twelve.

stricted. The expansion bands were put on and the arches slowly and carefully expanded into normal shape in a period of a

year and a half. During that time the impacted teeth came through the gum by their own force, as in Case No. 15, and took the desired positions (Figs. 165–167). In Fig. 166 it will be noted that a platinum cap has been placed upon the right upper lateral incisor, so as to enable it to maintain itself in the arch by a safe

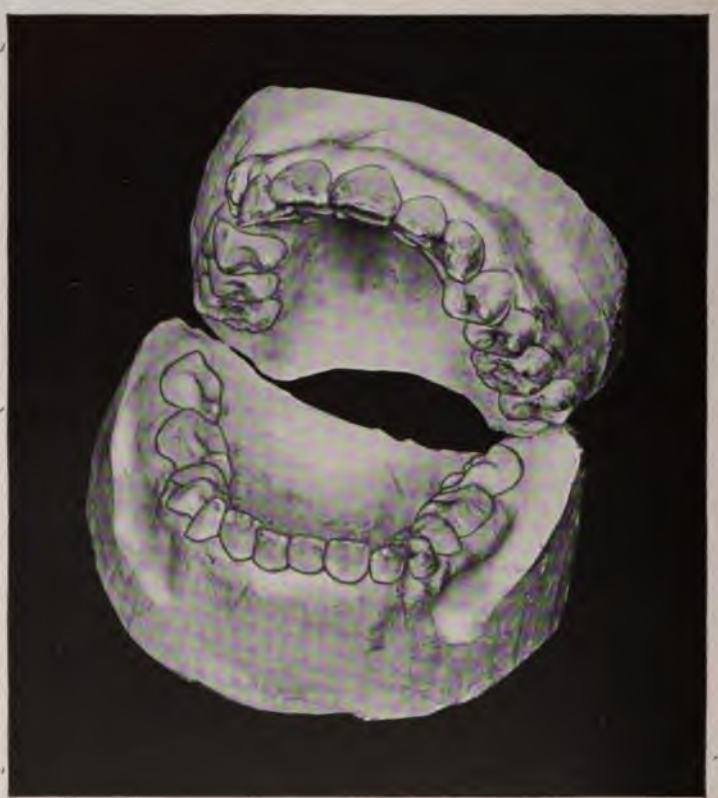

Fig. 167.—Case 16.

occlusion with the lower teeth. Nothing was done except to expand the arches and to make space where the temporary teeth had been prematurely lost. Later on the tips of the incisor and canines were restored by porcelain so that perfect occlusion was obtained as in Figs. 168–170. These casts were taken some years after the case was completed.

Fig. 168.—Case 16, ten years later.

Fig. 169.—Case 16.

Fig. 170.—Case 16.

Fig. 171.—Case 17, irregularity caused by genera malnutrition which resulted in a lack of bone development.

Malnutrition.—Case No. 17 (Figs. 171–173) shows a case of faulty occlusion and lack of development due to malnutrition in the upper jaw. It required three years to expand the upper

jaw to symmetry with the lower jaw, which was fairly normal. The malnutrition was caused by measles at the age of four, from the effects of which the child did not recover for years. The child was eight years old when the case was undertaken. Expansion arches were used and the growth of the upper arch stimulated by slow expansion for a period of six months; then the appliance was removed and the bone allowed to develop as it would for another six months. This procedure was repeated

Fig. 172.—Case 17.

at six-month intervals for three years, during which time care was taken that the child was properly nourished and given judicious exercise. At the end of this time the jaw was quite normal, and the teeth in good occlusion. This is a striking illustration of the fact that there need be no such thing as a permanently small jaw, from which teeth have to be extracted, if the irregularity is discovered in early childhood. This case proves the fundamental law that the face develops to the teeth,

not the teeth to the face; and if the teeth are placed in perfect occluding arches during the developmental period there will be a

Fig. 173.—Case 17.

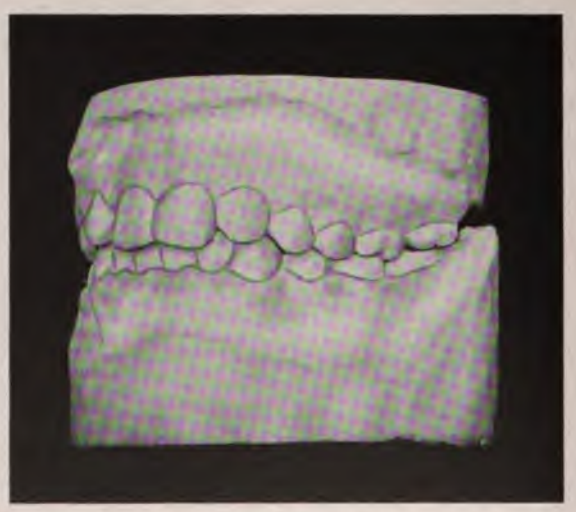

Fig. 174.—Case 18, finished case of orthodontia where upper lateral incisors are missing.

corresponding development in the formation of the profile and face generally.

Case No. 18 presents a very interesting complication (Figs. 174–176). When the patient was seven years old she was so poorly developed that there was no possibility of the upper jaw ever developing to meet the demands of the dental arch. The lower jaw was fairly normal. In addition to the poor development, the right upper permanent lateral incisor was missing and the left was a mere peg. The restoration of the permanent lateral

Fig. 175.—Case 18.

incisors by bridgework was impossible at that age. So the rudimentary upper lateral incisor was extracted. This necessitated a corresponding contraction of the lower jaw. The lower first bicuspids were, therefore, extracted. If the lower lateral incisors had been extracted the resulting arch would have been V shaped and would have consequently destroyed the contour of the cheeks. By thus extracting the bicuspids the lower normal arch from

canine to canine was maintained and was the means of making the upper arch appear normal. The upper canines were allowed to come in next to the upper central incisors, and the lower canines and incisors were drawn back until the space formerly occupied by the incisors was filled. Care was taken that the normal curve of the incisors and canines was maintained. The sharp points were taken off the upper canines so as to make them look somewhat like laterals, and the first bicuspids gave the appearance of very presentable canines. Figures 174–176 show the very satisfactory result. In addition to the adjusting of

Fig. 176.—Case 18.

the teeth the child was given a diet containing large amounts of fat and cream, and the necessity of outdoor exercise was emphasized.

This chapter will be concluded with the reiteration of the fact that the dentist should acquaint himself with the law governing the correct occlusion of children's teeth, and then he should see to it that after the age of seven especially the teeth are made to conform to the law. The distance from fossa to fossa of the first upper permanent molars should be 15 to 20 per cent. more than the distance from the fossa to the median line of the central

incisors. The upper teeth must always bite exteriorly to the lower teeth. The first lower molars must occlude anteriorly with the upper first molars, and the lower incisors must occupy an unbroken even curve in the arch, so that the canines will erupt at the ends of the incisor line, occupying their full width in the arch. And if the incisors scissor past each other, judicious fillings or caps should be placed on the molars, so that the teeth will have space to be brought into proper occlusion. The ingrowing frenum must be eradicated when it appears and the upper teeth coaxed into position if necessary.

And it is of greatest importance that the child's teeth are kept clean and consequently free from decay, so that the full space occupied by the temporary teeth will be maintained, and so that the roots of the deciduous teeth, instead of becoming infected and necrotic, will remain healthy and admit of normal absorption.

CHAPTER IX

CROWNS

Pin Crowns, Band Crowns, Gold and Porcelain Inlay Crowns. Advantages and Disadvantages of Each

THE artificial crown has been a great blessing and a great curse to mankind. Properly made it is the means by which a broken or decayed tooth is efficiently and artistically restored to symmetry and usefulness. But if it defies the law of cleanliness and there is not exact gum marginal adjustment, it may be the direct cause of innumerable serious organic diseases.

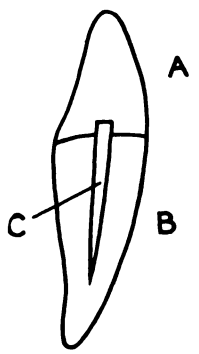

Fig. 177.—Pin crown.

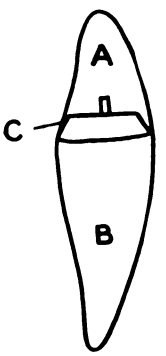

Fig. 178.—Band crown.

Crowns are divided into three classes: the pin crown, the band crown, and the inlay crown. The pin crown is one that depends upon a pin or dowel for attachment to the root, as in Fig. 177. *A* represents the crown, *B* the root, *C* the pin or dowel. The band crown is one that depends for its stability on a band attached to the crown that hugs the head of the root like a ferrule, as in Fig. 178. *A* represents the crown, *B* the root, *C* the band, which in this instance is attached to the porcelain crown by a pin.

The inlay crown is one that is attached to the root by means of an inlay as in Fig. 179. *A* represents the crown, *B* the molar

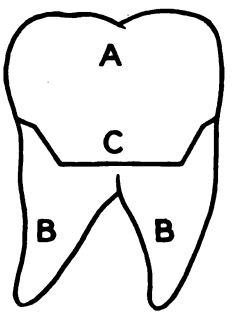

Fig. 179.—Inlay crown.

roots, *C* the inlay that is attached to the crown and enters into the upper body of the root, giving anchorage after the manner

Fig. 180.—Pin-band crown.

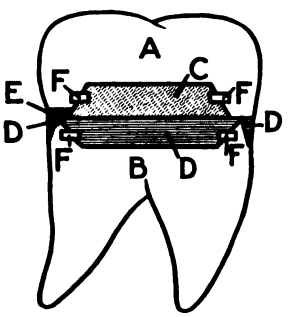

Fig. 181.—Inlay-band crown: *A* represents porcelain crown; *B*, root with cavity prepared for inlay and gum margin sloped properly for reception of band; *C*, gold inlay made in hollow porcelain crown; *D*, band and gold inlay that is to make attachment to root; *E*, orifice filled in with solder by which upper and lower inlays are soldered together; *F*, grooves for reception of cement by which fixture is finally secured into position. This method makes it possible to attach porcelain without subjecting it to heat.

of inlays. Of course, these three methods of attachment are capable of being used separately or in various combinations, but we designate the type of crown according to whichever

attachment predominates. In addition to the simple pin, band, and inlay crowns, the band and pin can be used in combination (Fig. 180); or the inlay and band (Fig. 181); or the inlay and pin (Fig. 182).

The Pin Crown.—The pin crown and the inlay crown conform to the exact contour of the tooth at the gum, and therefore are to be preferred wherever the root is sufficiently strong and large to insure an anchorage that will not compel too great sacrifice of root structure. The band crown, holding as it does from without, will support a weak root against external stress to a remarkable degree, but it has a serious disadvantage in that there is great possibility of its impinging on the gum (Fig. 183), leaving sharp knife edges that lacerate the tissues every time the tooth moves in its elastic peridental membrane under the

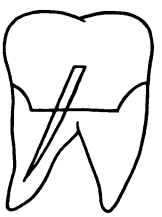

Fig. 182.—Pin-inlay crown.

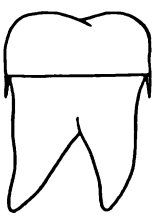

Fig. 183.—Band crown with improperly constructed band.

shock of mastication. This, of course, need not be so, as will be presently pointed out, but it is a danger against which the best mechanic must always be on his guard, and it is the condition that actually occurs in the vast majority of cases. Theoretically, the band that projects below the gum at the neck of a tooth can, by careful shaping of the root, be made perfectly smooth with the contour of the tooth, but practically this is not so. The root projects from the gum as in Fig. 184. It is therefore impossible to fit a band to it that will not project into the soft tissues, as in Fig. 185, unless the sides of the head of the root have been carved and trimmed as in Fig. 186, and even then it is always a question whether the band does not project too far, causing the edge to penetrate the surrounding gum and bony tissues. The most expert dentist cannot trim a root and fit a

band under the gum and be sure that the sharp edge of metal does not project enough to cause irritation and consequent infection every time the tooth springs under the impact of mastication. If this is true in the work of the most expert, how surely must it be so with the average operator! Let each dentist remember the ill-fitting bands he has deprecatingly observed on the crowns made by another dentist; let him remember the crowns made by himself that at the time he thought were beautifully fitted, but which subsequent events and the forceps permitted him to examine out of the mouth, to his mortification and chagrin.

The fitting of a band to the neck of the root under the gum can be likened to the well-known game of drawing a pig on paper with the eyes closed. The general outlines of the pig can be

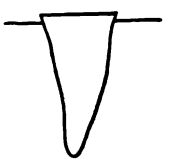

Fig. 184.

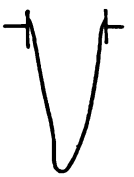

Fig. 185.

Fig. 186.

drawn with a fair degree of accuracy, but the characteristic details are just as hard to get as are the minute indentations and curves of the root. Yet, in spite of these serious objections, no experienced operator will say that the band crown should never be used. In bridge work or in fractured or badly decayed roots it fills a want at times that can hardly be supplied by any other device. But when we use it let us recognize its dangers and avoid them; let us admit that the best fitting band crown forms a ledge at the gum margin, and the seriousness of this danger will depend entirely upon how thoroughly the patient cleanses the mouth and how prone the oral tissues are to accept contamination. The best way to avoid this danger is to trim the root head to a smooth, slightly sloping cone (Fig. 187), having first built up the root where necessary with amalgam so that it projects above the gum. By this expedient the band can be brought to the gum and not

below it. And thus, by lifting the free margins of the gum, the edge of the crown can be examined after it is actually cemented into place, and any projection or roughness can be carefully polished away because it can be actually seen. But this procedure will be mentioned later when the methods of making band crowns will be discussed more specifically. If, then, the band crown ordinarily has such potentialities for infection, it is incumbent upon us to avoid its use in all crowns whenever sufficient anchorage can be obtained to obviate the danger either of loosening the cement or fracturing the root.

The anchorage for the simple pin crown can be obtained in every instance where the root is solid and undecayed below the

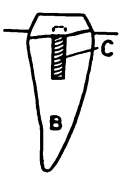

Fig. 187.—Decayed or fractured root restored with screw pin and amalgam.

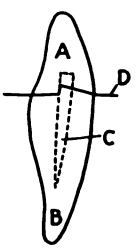

Fig. 188.—Pin crown with notch to fit head of root.

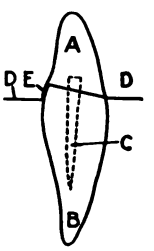

Fig. 189.—Pin crown supported by gold ledge on lingual side of head of root.

edge of the gum. With the upper central and lateral incisors and canines the face of the root should be formed into a notched wedge, with the notch on the lingual aspect, so that the head of the root will support the front wall against fractures from mastication (Fig. 188). *A* represents finished crown, *B* the carved root, *C* the outline of the pin, *D* the gum line. For with the upper incisors and canines the force of mastication is ordinarily applied to the pin crown so as to drive the pin against the front wall of the excavated root, and fractures are frequently the result of such a combination. But if the stress is supported by the notch, as described, or by a ledge (Fig. 189) in the lingual aspect of the root, the danger of dislodgment through a splitting of the root is entirely eliminated. *A* represents the crown, *B* the carved

root, *C* outline of pin, *D* gum line, *E* gold support or ledge on back of root.

The method of making these crowns is as follows: The root is reamed to fit the pin, which should be made of iridioplatinum wire or platinized gold wire, and the head of the root ground, as shown in Fig. 190. Then the pin should be adjusted to the reamed-out root canal and a countersunk crown adjusted and ground so as to closely fit the labial margin of the root, but on the back or lingual aspect a space should be left as shown in Fig. 191. Then the porcelain crown should be removed from the pin to which it is finally to be cemented, and the pin should be removed from the root and barbed with a knife. Then platinum foil, 0.001 inch,

Fig. 190.—Root notched lingually to receive labial stress of pin crown.

Fig. 191.—Pin crown in position preparatory to packing in moss fiber gold.

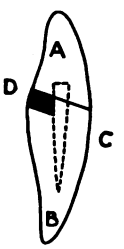

Fig. 192.—Pin crown in position with moss fiber gold packed in position, as shown by *D*.

or pure gold foil, 0.003 inch, should be burnished to the head of the root and the pin punched through it into the root canal. The pin and foil should then be removed together and soldered. The pin, cap, and porcelain crown should be placed in position, and while the crown is firmly held by the left hand or by an assistant, sponge gold should be firmly packed into the space remaining between the crown and the foil resting in the head of the root, as in Fig. 192. *A* represents the crown, *B* the root, *C* the platinum pin shown by the dotted lines, and *D* represents the sponge gold packed into the aperture between the head of the root covered by the platinum foil and the crown. The porcelain crown is then removed from the pin, and the pin, foil, and condensed sponge gold, appearing as in Fig. 193, are carefully re-

moved by a pair of pliers. A little borax is then placed upon the lingual aspect of the sponge gold, as designated by the arrow, and pieces of 22-karat gold solder flowed into the sponge gold that is to go next to the porcelain, otherwise the porcelain when replaced upon it will not fit. The solder should fill the interstices, not encroach upon the outside of the sponge gold except on the lingual aspect, where the small pieces of solder are first laid for fusing. If the sponge gold has been thoroughly packed, as described, there will be no difficulty in removing the pin, platinum foil, and sponge gold all in one undisturbed piece, and the soldering can be readily done in the Bunsen burner. When the soldering is completed the tooth can be cemented to it (Fig. 194). The gold back can then be polished and the crown ce-

Fig. 193.—Pin and gold support against labial stress.

Fig. 194.—Pin and gold support and porcelain crown cemented together.

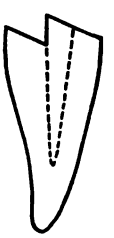

Fig. 195.—Root ready to receive crown.

mented to the root with Harvard or silicious cement, as desired. Before finally cementing it into its position on the root it is wise to remove the platinum from the labial portion of the crown so that it may not cause a discoloration after the cement has set. In such a case as this it is well to fill the root canal with Harvard cement and place silicious cement on the face of the porcelain and platinum around the pin. Thus, when the crown is shoved home, we have the adhesiveness of the Harvard cement in the root canal and the insolubility and beauty of the silicious cement to act as an invisible, permanent bond between the root and the cap. Sometimes in making the pin crown it is advisable to make

a stiff shoulder of gold at the lingual edge of the root, instead of a notch in the middle, as in Fig. 196. By this means the entire side thrust of the lower teeth is sustained evenly by the pin and shoulder, making a fracture of the front wall of the root practically impossible. When the root is perfectly strong, and the force of mastication is such as not to make too great a lateral

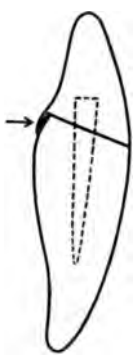

Fig. 196.—Pin crown with gold half cap or band on lingual side of root.

Fig. 197.—Pin crown with direct occlusion that makes a strong fixture.

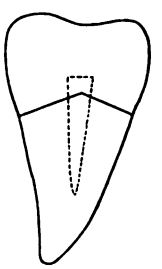

Fig. 198.—Wedge-shaped head of root with adjusted pin crown.

strain, as in Fig. 197, a simple porcelain crown with a pin is usually a satisfactory and permanent operation. In such procedures it is wise wherever possible to shape the head of the root in the form of a wedge or with a notch toward the side of the root on which the lateral strain of mastication is to be expected (Fig. 198). For instance, if the occlusion is as shown in Fig. 199,

the force of mastication will obviously have a lateral stress in the direction of the arrow, and the notch should, therefore, be as indicated, so that it will counteract the stress. If the stress should come on the other side the notch obviously should be trimmed the other way. The pin being separate from the crown is a great advantage in adjusting the porcelain to the head of the root, and with the aid of the modern silicious cements the head of the root and the crown do not have to be so perfectly adapted as formerly. For instance, a crown and root can be

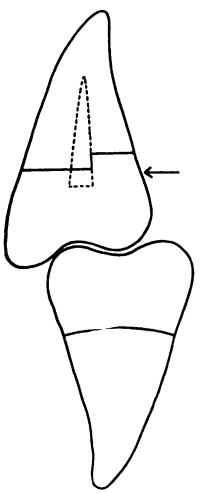

Fig. 199.—Root notched so as to minimize the danger of fracture from side pressure.

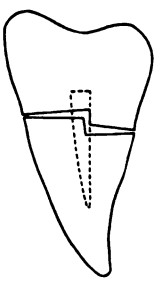

Fig. 200.—Root and crown roughly notched to increase stability.

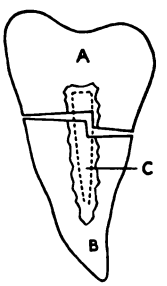

Fig. 201.—Method of cementing a crown and root so that an insoluble cement may be at the crown and root margins, while the more adhesive phosphate of zinc cement may hold the pin in position to the root.

shaped approximately as in Fig. 200, and the pin cemented into the porcelain in its proper relation to the root. The silicious cement of the proper color should then be selected and mixed to a doughy consistency, and any good slow-setting phosphate of zinc cement should also be mixed to a creamy consistency and injected into the canal with a Jiffy tube. Then, before the cement can set, the silicious cement should be placed around the porcelain base of the crown and neck of the pin, and the crown should at once be shoved home, giving an adhesive cement

in the canal against the pin, and an insoluble, invisible cement as a joint where the porcelain and root join, as in Fig. 201. *A* represents porcelain crown ground to fit approximately the notched root *B*. *C* represents the platinum point that extends into the porcelain crown and the root. It should be remembered that real grooves, not scratches, should be made in the root canal and deep nicks in the pin so that the cement will act as a dowel as well as an adhesive. If the occlusion is exaggerated, so that a great side thrust is inevitable, it is sometimes possible and advisable to grind off the lower tooth so as to make the masticating force more end to end. In fact, this should always be done if the simple pin crown is to be used. If a great lateral thrust from mastication is to be expected, the retention shown in Figs. 193 and 196 should be used. This principle also applies to an entire gold pin crown with a porcelain facing, but as the method of making such a crown is so well known, further explanation is unnecessary.

Amalgam Crown with Porcelain Facing.—Where there is little or no lateral stress, as in the case of a bicuspid, a useful crown can be made not only easily and rapidly, but, above all, free from gum irritation at the joint of union with the root, even though the root is very frail and badly broken down. The root should be trimmed so that the labial edge is well below the gum. If there is sufficient root to permit the cutting of a wedge in the head, so much the better. The head of the root is first pitted with fine undercuts, and a countersunk pinless bicuspid is then ground so as to fit well under the gum and, at the same time, form a good articulation. Undercuts are then made in the cavity of the tooth with a diamond disk or small sharp carborundum stones. A How screw post is then inserted and cemented into the root and cut off just long enough to support the tooth in proper position. The tooth, pin, and crown are then joined as follows: The cavity of the tooth is filled with soft amalgam; the head of the root and pin are covered with a ball of soft amalgam; then the tooth is pressed down into position on the root and pin and held there with the left hand, while an instrument in the right hand smoothes the soft amalgam into partial shape. Then,

still holding the tooth firmly with the left hand, a piece of sponge gold should be pressed against the lingual surface of the crown and the two adjacent teeth in such a way as not to interfere with the articulation. The gold at once sucks out the excess mercury and becomes stiff and adherent to the amalgam. At the end of five minutes the patient can be sent away, being cautioned not to bite upon the crown for twenty-four hours. When he returns on a later visit the excess amalgam can be trimmed off with fissure burs, files, and sand-paper strips. This method is especially valuable for roots that have been badly broken down through decay, as the metallic salts of the amalgam filter through the weakened root material and seem to have a great preservative power. In such cases it is particularly essential that the occlusion of the opposing cusps should not exert excessive lateral stress.

Inlay Crowns.—This type of crown is particularly adapted to the restoration of molars, and may be used with or without a pin, according to the necessities of the case. The inlay crown reinforced by a pin will be described first. The roof of the pulp chamber of a molar into which the inlay is to project is usually just level with the gingival margin of the enamel. The head of the root should be ground smooth and flat. In this procedure, however, if the crown of the natural tooth has not decayed to the gum level it is rather an advantage that the tooth margins should extend above the gum, so that a greater tooth cup can be obtained for purposes of retention. The pulp chamber and the most available canal should be enlarged as deeply as possible in order to give ample room for the pin and inlay. It is wise to trim the edges of the cavity in the crown so that they will come to the margins, as in Fig. 202, not as in Fig. 203, as much greater stability and strength is obtained by avoiding the sharp angle that may allow the porcelain to chip under the stress of mastication. When the cavity and canal have been prepared according to the lines described, a platinum pin should be inserted into the root canal as far as possible. The pin should then be removed and platinum foil, 0.001 inch, should be swaged into position with bibulous paper and burnished with steel burnishers

until a perfect matrix of the pulp chamber has been obtained. Then, while the matrix is still in position, the pin should be punched through it well down into the canal. The pin and foil should then be fastened together with hard wax and should then be withdrawn and invested with a mixture of half plaster and fire clay. The investment should be very thin, not over $\frac{1}{8}$ inch in thickness. Then porcelain of the desired color should be mixed to the proper consistency, as described in Chapter VIII, and flowed into the matrix around the pin. The wax, of course, should previously have been picked out with a hot instrument or washed out with hot water. In applying the first portion of porcelain paste care should be taken to keep the edges of the

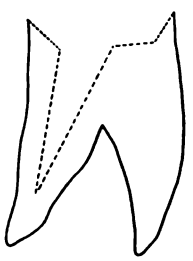

Fig. 202.—Proper way of sloping cavity wall in a root for an inlay crown.

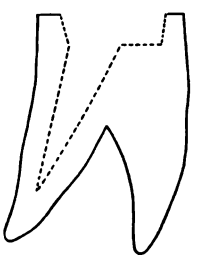

Fig. 203.—Improper way of trimming margins of cavity in root where an inlay crown is to be used.

platinum matrix free from the paste to allow of a further adaptation of the metal. When the first fusing has been accomplished by placing the invested pin and matrix in the furnace, a second application of porcelain may be necessary to completely fill the mold and fuse the pin firmly into position, on account of the shrinkage of the first supply of porcelain body. When the pin and matrix are thoroughly fused together in proper relationship by the porcelain, the investment should be broken away and cleansed from the pin and matrix, and the fixture placed again in position in the mouth, where the free edges of the matrix should be given an additional burnish to secure accurate adaptation. With the matrix in place an impression should be taken of the adjacent teeth. Wax should then be flowed over the pin

and under side of the matrix to permit of easy removal; and a model cast with the pin and matrix in place. When the model is obtained a slight amount of heat applied to the platinum matrix and pin will permit of easy removal. The pin can be cut off to the proper length and the crown built up according to the necessities of color and bite, using the model as a guide. Figures 204 and 205 show the finished crown and the outlines of the cavity in the prepared root. Carved crowns are frequently the most artistic when made by an expert porcelain worker, but ordinarily the dentist will get the best results by making use of a manufactured facing or tooth such as is designed for vulcanite work. The tooth can be selected both for color and size, and can be ground and fused into position with the porcelain

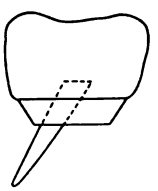

Fig. 204.—Inlay crown with pin.

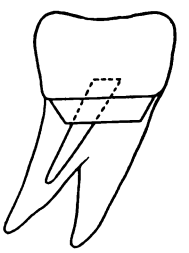

Fig. 205.—Inlay crown and pin in position on root.

as desired. Before the edges of the platinum matrix are covered by the last fusing it will frequently be advisable to burnish them finally in the mouth on the edges of the root to ensure perfect adaptation. Before the tooth is set the platinum matrix should be removed, the pin roughened and the cavity undercut, as previously stated. Above every other consideration, the dowel principle should be maintained by using genuine grooves in the tooth cavity that is to hold the crown. The method of using silicious cement on the edges and phosphate of zinc within is also advisable. It should not be forgotten that the chief support of this crown lies not in the pin, but in the inlay of porcelain that fills the enlarged pulp chamber. If two pins are deemed advisable, they can be used if they are not too long, and if the

pulpal openings of the canals are sufficiently enlarged to make it possible to overcome the divergence of the canals. If it is desired to make these molar crowns without the use of a model the following method can be employed, and, as a matter of fact, an experienced porcelain worker seldom uses a model. When the matrix and pin are stiffened with porcelain, as herein described, a countersunk tooth, such as is used for vulcanite work, of the proper size and color, may be roughly ground to fit the head of the root and bite. The pins of the tooth should be cut away and the countersunk portion filled with porcelain paste. The tooth can then be placed in its proper position on the platinum matrix and fused, care being taken, as before stated, to leave the platinum edges free for final burnishing and finishing. Instead of using a manufactured tooth, however, the experienced worker will usually build the tooth up with porcelain, molding it into shape where necessary, and carving it after the final fusing to give the proper bite and contour.

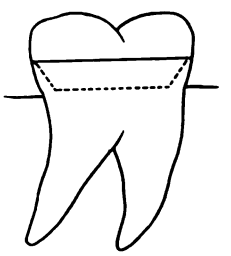

Fig. 206.—Simple inlay crown.

As before stated, with an inlay crown the mass of porcelain within the cavity is the chief source of retention, and, therefore, it is sometimes difficult to know whether one is inserting an inlay or crown. For instance, in a case such as is shown in Fig. 206, is it an inlay or a crown that is required? The broken tooth has left a little more than a third of the natural crown. The dotted line shows the size of the inlay and its outline. Before the days of insoluble, invisible silicious cements such a tooth would ordinarily have been cut down to the gum margins to conceal from the patient's eye, and perhaps the shrinking eye of the dentist, the unsightly edge that was sure to appear in the course of a year or two; but now, with the aid of these cements, no such fear need restrain us from putting our edges boldly above the gum, knowing that a moderate amount of skill, and an eye fairly exact in the selection of colors, will enable the operator to make a cleanly, inconspicuous operation. A porcelain filling

ought to be inconspicuous at the distance of 6 inches, and, as a bright girl once said, "If anyone gets closer than that he won't see it anyway." If the sides of the tooth are decayed well down to the gum on all sides, the pin is an advantage, but if the tooth is only partly gone, the porcelain crown or inlay, as just described, can be made without the pin, the deep, sloping cavity walls being a sufficient source of retention.

When there is unusual stress in mastication, and the color of the filling is not an objection, the gold inlay or crown can be quickly and readily made by a modification of the method just described. The cavity in the tooth is prepared as in Figs. 205 and 206, and gold, 0.003 inch, is used for the matrix instead of platinum. While the matrix is in position the pin is punched through it into the root canal and the cavity packed with sponge gold until the matrix and pin are firmly joined together. The matrix and pin should then be teased out by gently raising the sides of the matrix, first on one edge and then on the other. When it has been removed the pin can be seized with a pair of pliers and 22-karat solder can be flowed into the sponge gold. Then the filled matrix and pin can be replaced in position and the edges burnished, when more sponge gold can be added and more solder used until the complete gold crown has been made; or, if desired, a porcelain top can be adjusted in any one of the numerous ways known to the mechanical dentist.

The Band Crown.—We now come to the band crown—the malefactor— and yet in many instances the only resource. For, as before stated, when it extends below the gum its benefit is problematic, but when its edge is at or above the gum margins it is a tower of strength and stability. For instance, take the case of a superior upper incisor that has lost its pulp and has been so seriously discolored that its appearance is hopelessly ruined, while its intrinsic stability is so undermined by decay that a pin crown would be ill-advised. In such a case the band crown is called for (Fig. 207). The cementum is the healthiest structure of the whole tooth, and the only possible means of preserving the root is to fill it up boldly and then to band it. The first essential, of course, must be perfect sterilization and

cleansing of the root canal, followed by careful sealing of the tip with gutta-percha. When this has been accomplished, as described in Chapter VI, the entire interior of the root and tooth should be filled with amalgam. In cases where decay has progressed to a very extensive degree a How screw may be inserted in the canal and the amalgam packed around it and the excess mercury extracted with sponge gold. The amalgam is useful in arresting decay by the infiltration of its salts into the tooth substance, although it sometimes has also an unfortunate tendency to turn the root black, so that any portion of root appearing above the gum is conspicuous. When, therefore, the weakened tooth or root has been properly sterilized and filled, as just

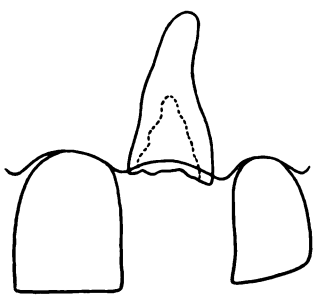

Fig. 207.—Broken-down central incisor root to be banded and crowned.

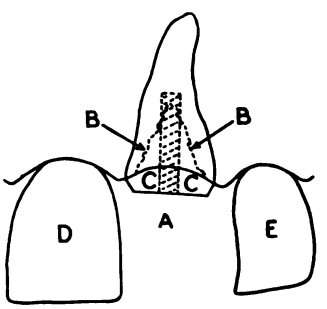

Fig. 208.—Broken-down incisor root built up with a screw and amalgam ready for banding.

described, it must be shaped at the gum margin with slightly conical sides, as shown in Fig. 208. A bevel edge 0.05 inch in extent is ample retention for a crown if the band fits accurately and is rigid enough to withstand the stretching force of mastication. When platinum or gold is used No. 30 B. & S. gage is strong enough for a band that averages $\frac{1}{5}$ inch in diameter. All bands exceeding that size should be No. 29 gage, which thickness will be strong enough to give stability to any crown. The great advantage of a simple crown band on a 0.05 inch bevel lies in the fact that if at any time the porcelain facing chips or splinters away and requires repairing, a strong pull away from the gum line with a heavy enamel scaler will easily dislodge it,

and make the repair simple for the dentist and of great ease for the patient. Where this procedure is not feasible, through a too great adherence of the cement, a small cut in the edge of the band will make its removal easy, and the cut in the band can be readily soldered before the tooth is finally repaired. The direct tension away from the root is never exerted in the act of mastication, and therefore such a possibility of easy removal does not mean that the band crown will not be amply able to withstand the stress of chewing without being dislodged. Unfortunately, however, there is no operation that has not its percentage of failures, but it can be safely said that if a band accurately fits a slightly conical head of a root, and is cemented on with proper regard for the dowel action of the cement and care as to dryness, there

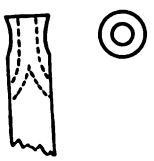

Fig. 209.—Head of instrument to receive wire loop for measuring circumference of root prepared for banding.

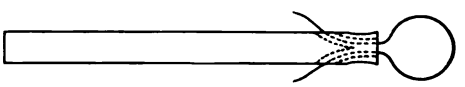

Fig. 210.—Instrument with wire loop inserted ready to be slipped around head of root.

is no reason why the crown should not remain firmly attached. The failures usually arise from the fact that the band does not quite fit, or that it is too thin and stretches, or that the cement is not properly mixed, or last, and most frequently, moisture creeps in between the root and cement while the crown is being set in position.

The first band crown that will be described is the crown consisting of a platinum band for a base, with a covering of porcelain built and baked upon it. The method of procedure is extremely simple when the art of mixing and baking porcelain is mastered. Take, for example, the construction of an upper incisor, as shown in Fig. 208. The figure represents the frontal aspect of a broken-down upper central incisor, where the root canal has been filled and the conical top of the root has been

prepared. *A* represents a screw which has been inserted into the root, *B* the amalgam which has been packed into root and around the screw, *C* the projecting stump composed of amalgam and root, *D* the adjacent upper central incisor, and *E* the adjacent upper lateral incisor. The measure of the base of the cone is taken with No. 30 brass wire as follows: Figure 210 represents

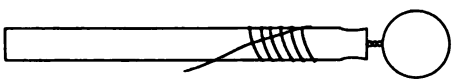

Fig. 211.—Wire loop drawn tight and removed from head of root.

a steel rod with two holes drilled from the opposite sides to a common orifice in the end (Fig. 209). The wire is passed through these holes, forming a loop. When this has been accomplished the loop is passed around the root near the gum, and the loose ends drawn upon it until the loop approximately encircles and fits the root. Then the rod is slowly revolved until a closely fitting wire ring fastened by a couple of twists is the result. The

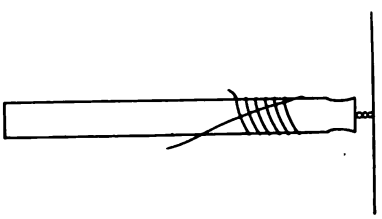

Fig. 212.—Loop split and straightened to show length metal should be cut to form band.

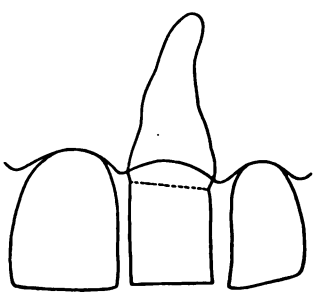

Fig. 213.—Platinum band fitted to root preparatory to making porcelain crown.

loop is then slipped off the root, cut with a pair of scissors and straightened out, so that it resembles Fig. 212 and gives the exact size of the circumference of the band to be used. The strip of platinum for the band should then be cut either of No. 30 or No. 29 gage, according to the size of the root, and of a width a little less than the entire length that the finished tooth is to possess.

The band should be made 0.02 inch shorter than the wire. The ends of the piece of cut platinum should now be brought together with a slight lap, soldered with pure gold and hammered so that the soldered ends will be even and level with the rest of the band. The band is now ready for adjustment to the root. The band should now be pressed upon the root, jamming and stretching it upon the cone until it fits the root evenly all around, and touches the gum but does not impinge or go under it. When the band is being fitted it should be cut away with an engine stone where it impinges so that it will finally fit without lacerating the tissues. At this point it resembles Fig. 213. The band should then be compressed near the cutting edge until it fills up the space the

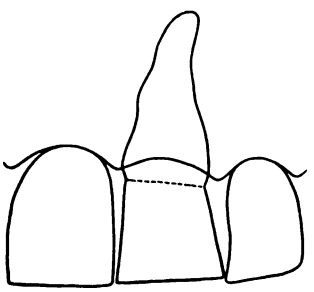

Fig. 214.—Band compressed at cutting edge to fill space between teeth.

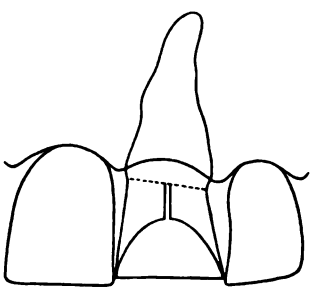

Fig. 215.—Platinum band trimmed labially preparatory to final shaping to receive porcelain finish.

finished tooth is to occupy, as in Fig. 214. Then a curved piece of platinum is cut out of the labial side, as in Fig. 215, and a cut made in the labial portion that is left, that will reach to the top of the root. When this has been done the platinum on the labial side should be boldly pressed down over the head of the root, and ground and molded so as to form a complete skeleton cap that will firmly fit the root and occluding bite, and yet will allow ample space for the porcelain that is now to be added, according to the color and size desired. The side view of the cap is now as seen in Fig. 216. The cap is now removed and is ready for the porcelain, that should be added as described in Chapter VII, until it resembles Fig. 217. The dotted lines *A*

show the porcelain that enters within the body of the cap for purposes of retention; *B* represents the porcelain face of the tooth when the process is completed. When the platinum cap has been made, its completion with the porcelain bodies is extremely simple and easy. The color in the shade guide should be chosen; the mixture made according to the formula, care being taken in this work to add a little extra yellow to counteract the blue of the underlying platinum. The first baking should be made from the tip down to the hollowed-out portion of the cap. The second and third bakings should cover the entire anterior surface of the completed tooth. In the last baking, where the slightest excess of baking would cause the platinum underneath to show

Fig. 216.—Cross-section side view of platinum cap ready to receive porcelain covering.

Fig. 217.—Porcelain central incisor with platinum base.

through and spoil the color, it is wise to bake very slowly and to stop while the final surface is still slightly granular. This can readily be gone over with a sand-paper disk, and the porcelain will take a beautiful polish, and yet will prevent the blue color of the platinum beneath from showing through. As before stated, care should be taken to see that the band crown is set with great care as to dryness and regard for the dowel effect of the cement. Sometimes if the band cannot readily reach the labial aspect of the gum, and the line of the band and root is disconcertingly evident, it is good practice to cut this line out with a fissure bur or inverted cone bur, and fill in the space with a well-chosen silicious cement that will completely conceal

the edge of the rim and make a smooth, even contour with the root and the crown.

In making a bicuspid or molar the same principle and procedure hold, with a few necessary, slight modifications. In either

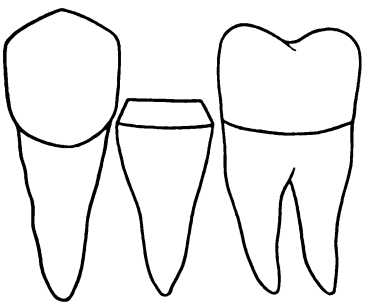

Fig. 218.—Bicuspid prepared to receive platinum band for porcelain crown.

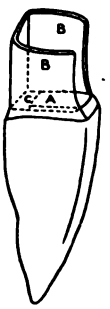

Fig. 219.—Side view of platinum shell and band for porcelain bicuspid.

case the head of the root should be trimmed to a cone, as previously described, care being taken not to allow the band to extend beyond the bevel of the root into the gum. The width of the band should not come up to the occluding tooth and should

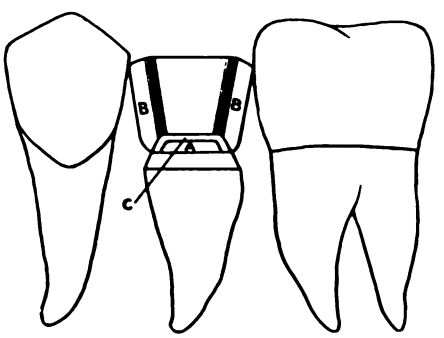

Fig. 220.—Platinum shell and band for porcelain crown in its relation to adjacent teeth.

be short enough to allow a generous covering of porcelain. The greater the body of porcelain, the less likelihood is there of fracture from mastication. For instance, Fig. 218 represents a bicuspid root that has been prepared for a platinum band filled with

porcelain. Figure 219 represents the three-quarter aspect showing the band in position. *A* shows flap of platinum bent over on the head of the root *C* to form a partial cup to receive the porcelain, *B* shows sides of the band. Figure 220 shows the buccal aspect of the same crown and band. *B* represents the upper part of the band with the edges spread so as to make good approximal contact with the adjacent tooth, *C* represents the exposed root, and *A* the flap turned in to make the cup for the porcelain. The method of procedure in applying the porcelain is exactly the same as with the central incisor, previously described. However, with the bicuspids and molars great care



Fig. 221.—Molar root trimmed for adjustment of gold crown with a porcelain face.

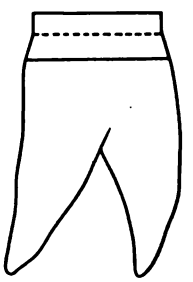

Fig. 222.—Gold band in position. Dotted line shows the head of the root. Band should be cut off at this line and a top adjusted.

must be taken with the grinding surface to reproduce the cusps and contours.

If it is desired to make a gold cap with a porcelain facing the procedure is obvious to those who know the ordinary processes of crown and bridge work. Yet it might not be out of place to briefly describe one of the simpler methods. Let us take, for example, a molar root that has been prepared for the crown, as in Fig. 221. The band is prepared of No. 29 gage gold plate composed of 22 parts gold, 1 of copper, and 1 of silver. The root with the band in position appears as in Fig. 222. The dotted line represents the position of the top of the root. The band is now ground level with the root top while it is in position; it is then removed and a piece of pure gold plate, No. 30, is sol-

dered on top with 22-karat solder, trimmed evenly, and polished. When the cap is replaced in position the pure gold can be burnished and worked with broad-faced pluggers until it absolutely fits the upper surface of the root. Then, as is shown in Fig. 223, a porcelain facing, *B*, with platinum pins is ground to fit the buccal edge of the cap *A*. The facing is backed with pure gold and fastened to the cap with hard wax, *C*. The bite is contoured in wax and reproduced in gold in any of the numerous ways commonly known. When a complete gold shell is desired, and the question of color is of no consequence, the making of a gold crown is a question of a few minutes from the time the root has been properly filled and prepared. Let Fig. 224 represent such

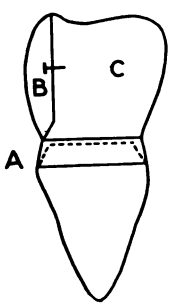

Fig. 223.—Ordinary porcelain-faced gold band crown properly adjusted to root.

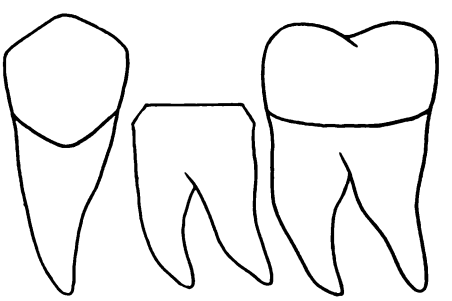

Fig. 224.—Root trimmed for adjustment of gold shell crown.

a molar root. The band should be made of No. 29 gage gold plate, as previously described. The proper measurement should be made with a brass wire and the band cut 0.02 inch short. The ends of the band should then be brought together with a slight lap, powdered borax placed upon the line of juncture, and the band held in a Bunsen burner until the two ends are sweated together. The joint should then be hammered even, and we have a seamless collar the right size for the work. This should then be pressed down upon the root and fitted to the gum, as just described. The occlusal edge should also be ground so as just to miss the opposing teeth, the sides also should be bulged and jammed out so that they make proper contact with the

adjacent teeth and protect the approximal space on each side. Then we have the band assuming a position such as is shown in Fig. 225. When this has been accomplished a suitable mold is chosen from a die plate containing inlay impressions of tooth cusps. A top for the crown is swaged of pure gold No. 30 B. & S. gage. This top is then fitted approximately to the band and tacked into position on four sides with 22-karat solder, care being taken that it is sufficiently high to reach the occluding tooth and that the solder used for tacking it into position does not get upon the gold cusps, rendering them stiff and rigid. When this has been done the crown is filled with soft wax and placed in position on the root. The patient is then told to sink his teeth into it and to swing the jaw so as to get a perfect plane of mastication. The soft gold yields to the pressure and perfectly occluding cusps are quickly formed. If the gold is driven down too far it must be raised in that particular spot by a broad-faced plugger. So far the crown consists of a well-fitting band and perfectly occluding cusps made in thin gold. It is taken off the root, the wax removed, and sponge gold packed into the inside of the crown next to the grinding surface, so that it makes the grinding surface at least $\frac{1}{32}$ inch in thickness. This can can readily be done without distorting the soft gold face. Powdered borax can now be sprinkled within the gold cap, pieces of 22-karat solder added, and the whole appliance held in a Bunsen burner until the interstices of the sponge gold are filled. This crown can then be polished and set in position in the usual way, care being taken not to polish the side so as to destroy the firm union of the crown with the contact points of the adjacent teeth.

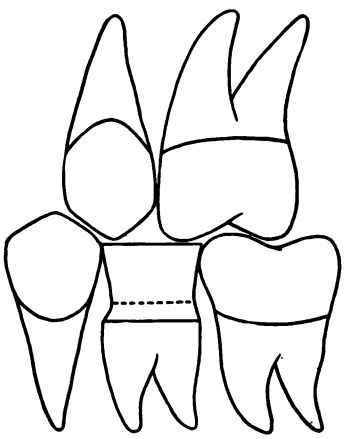

Fig. 225.—Gold band adjusted to root and adjacent teeth ready for soft gold top, into which the occluding teeth are to be bitten to make a perfect and easily adapted bite.

CHAPTER X

THE REPLACING OF LOST TEETH

The Attached Bridge. The Removable Bridge.

The Attached Bridge.—As has previously been stated, a bridge that cannot be kept clean should never be placed in the mouth. Many pieces of removable bridge work attached by telescope crowns are so bulky and badly constructed at the gum margin that although the bridge itself can be cleansed, nevertheless the inner crowns, by their impingement on the gum tissues, are a constant menace to the health of the mouth tissues and a possible source of general infection throughout the body. On general principles, therefore, the simplest appliances consistent with strength and durability are to be preferred.

The replacement of a single incisor or canine, where the teeth on both sides are normal and sound, has been considered the bête noire of dentistry. It has generally been associated with extensive banding and crowning of one or both adjacent teeth, and only too frequently the procedure has been followed by inflammation and infection of the gums around the abutments. As a matter of fact, there need be no difficulty in making a useful, permanent, natural, and cleanly fixture for the replacement of such a tooth. Take, for instance, the restoration of an upper central incisor where the other central and the adjacent lateral incisors are normal. The procedure is as follows: The pulp in one tooth is removed, the canal tip filled as described in Chapter VI. Then the canal is reamed out and a piece of iridioplatinum or platinized gold wire, No. 14 or 16 B. & S. gage, is inserted in the canal as far as possible. The wire is then bent at right angles across the space and the end fitted into a shallow groove that has been made in the lingual aspect of the other tooth.

The wire abutment must be set so as to avoid the bite of the occluding lower teeth. A porcelain dummy that fits the gum and has a suitable color is then soldered to the bar in the usual way, and the whole appliance is cemented into position, one side being attached and the other free. In this way it is possible for the floss-silk to be passed under the loose end of the bar, insuring perfect cleanliness. It is essential to carve the porcelain dummy so that it will conform to the characteristics of the adjacent teeth, as shape is even more important as a means of concealment than color. In cementing the appliance into place the lower portion of the canal should be filled with phosphate cement, and silicious cement should be placed around the pin

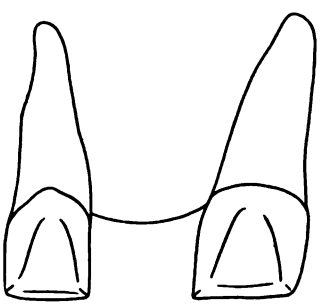

Fig. 226.—Missing upper central incisor. Ordinarily considered most difficult to replace.

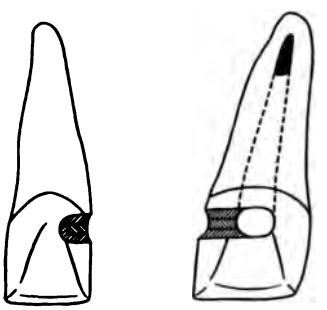

Fig. 227.—Preparation of teeth for replacement of missing upper central incisor.

where it emerges from the tooth. The appliance when set will thus have an adhesive cement holding the pin in the tooth, while the insoluble silicious cement will seal the orifice of the canal around the pin.

The procedure is shown as follows: Let Fig. 226 represent the lingual aspect of the case in question. Figure 227 represents the central incisor opened up, its pulp removed, and the pulp chamber sterilized and filled at the tip, and with a groove in the enamel running off the orifice of the pulp canal to receive the platinum bar as it spans the space between the two teeth. The end of the bar rests in the shallow groove shown in the lingual face of the lateral incisor. Figure 228 shows the bar in position,

and the facing ground and backed with pure gold ready to be fastened on the bar with hard wax, so that the appliance can be removed and soldered. Figure 229 represents the finished appliance ready for setting with cement. The curved lines represent the solder which gives the lingual contour and unites the bar firmly to the tooth. As the tendency of the bite of the lower teeth is to keep the loose end of the bar in its position in the groove, this appliance usually gives perfect satisfaction. And as the floss-silk can be passed between the pin and the lateral incisor, and under the fixture across the gum, there is no difficulty in keeping such an appliance as clean as a natural tooth. The groove in the lateral incisor that receives the bar usually does

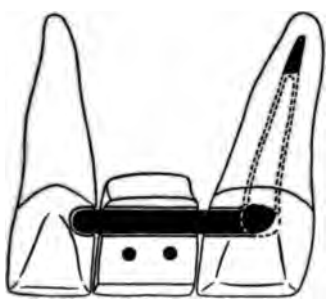

Fig. 228.—Lingual view of assembled bridge to replace lost upper central incisor.

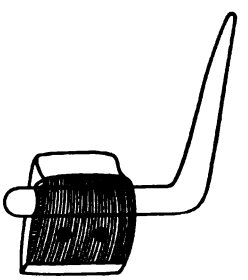

Fig. 229.—Bridge to replace lost upper central incisor.

not go completely through the enamel, but if it does, a shallow inlay of gold can be inserted containing a groove; or the cavity can be undercut and filled with insoluble silicious cement, in which the groove for the tip of the bar can be made. In any case there will be no tendency for decay to start under the bar if the surface is swept daily with floss-silk. In fact, enamel will not be decayed by any colony of bacteria that is less than a day old. Decay results because the colony is not removed daily, and usually remains undisturbed week in and week out. Decay is primarily the result of undisturbed filth, and if the refined members of society would be one-quarter as careful of the cleanliness of their mouths as they are of keeping their persons clean, decay of their teeth would soon be unknown.

The next bridge described will be the restoration of a missing bicuspid or molar by an immovably attached fixture, where the teeth on both sides are sound. This is the inlay cantilever bridge, that depends upon a gold inlay and pin inserted into the pulp chamber as a means of retention. Instead of demanding the removal of all the enamel from the abutment the construction demands the preservation of the enamel for its strengthening quality and its beauty of appearance. If the pulp has previously been destroyed and the canals filled aseptically, so much the better. Described in a few words, the bridge consists of a gold inlay through which a bar projects into the root canal of the abutment tooth, which bar also extends across the gap to a groove on the edge of the occlusal surface of the other abutment. The porcelain facing or dummy is soldered to this bar. In fact, this bridge is similar in principle to the incisor bridge just described, except that the broad masticating surface of the dummy gives a tipping tendency, which is overcome by making the gold inlay extend into and over the grinding surface of the stationary abutment. If there is a filling in the approximal grinding surface of the molar that is to act as an abutment so much the better; if not, a cavity should be cut out sufficiently large, but not large enough to let the gold obviously show when the bridge is cemented into position. The cavity should extend well toward the gum line if the tooth is perfectly sound; and if the enamel at the base of the cavity seems at all infected it is better to let the cavity extend to the cementum. Then, when the cavity has been prepared with straight, slightly sloping sides, No. 14 platinum wire should be filed to a suitable point and fitted as deeply as possible into the most available root canal of the molar, the canal having been previously prepared to receive it. Then the wire should be bent to extend across to the face of the first bicuspid, where a convenient groove has been prepared, such as has been previously described. For instance, Fig. 230 represents the side view of the molar with the outline of cavity shown in dotted lines, and with the platinum or gold bar extending across the space to be bridged. Figure 231 shows the full occlusal view, *A* showing the grinding surface of the bicuspid, *B* the grinding

surface of the molar, with outlined cavity containing the bar that projects across the space to be bridged, and rests in the groove on the occlusal surface of the bicuspid. This groove ordinarily should not be made deeper than one-half the thickness of the enamel.

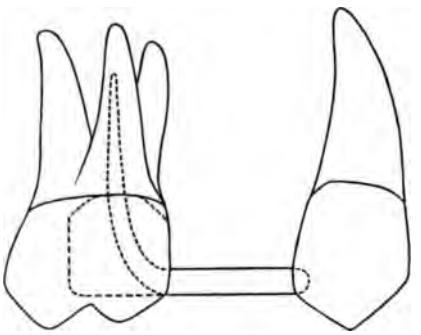

Fig. 230.—Pin and bar in position for attachment of a bicuspid dummy.

When the bar has been accurately adjusted and removed gold foil 0.003 inch in thickness should be burnished into the cavity of the molar until a perfect matrix is formed—if the bottom of the matrix is punched through it is of small consequence. When the matrix is completed and in position, the pointed platinum wire should be punched through the bottom of the

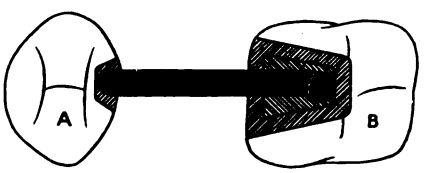

Fig. 231.—Occlusal view of bar in position running into lingual root of molar. Dummy with a porcelain face is to be soldered to the bar to replace lost bicuspid.

matrix into the root canal prepared for it, and the extension fitted accurately into position in the groove of the bicuspid. When this has been done, sponge gold should be firmly packed into the matrix around the bar, building it almost up to the matrix edges. If a little moisture gets into the matrix it does not, of necessity, interfere with the operation. When the gold is hard

and condensed the entire piece may be removed by grasping the cross-bar with a pair of pliers, and then the matrix, sponge gold, and bar can be readily soldered together with borax and 22-karat solder. This can easily be done, without investment, in an ordinary Bunsen burner, the only care required being that the solder should be placed upon the sponge gold and not allowed to flow upon the outside surface of the matrix, for such an accident will prevent the inlay from fitting accurately. When the piece is cold it should be replaced in the cavity and the entire matrix edges burnished to position, and the bar bent back into

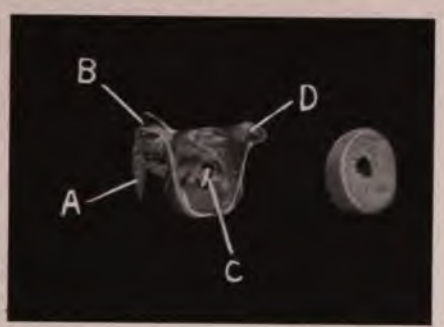

Fig. 232.—Cantilever bridge with porcelain side and grinding surface designed to replace lost bicuspid. Attachment is made to bicuspid by pin *A* and gold inlay *B*. A pin in gold cup *C* holds the porcelain tooth firmly when cemented into position, and the spud *D* rests upon the molar, giving firm support on the unfastened side of bridge. The figure on the right represents the under side of the porcelain tooth with the hole for the pin.

its proper place, if it has been slightly distorted during the first removal. More sponge gold and solder can now be added until the inlay has the proper occlusion. After the second soldering the inlay should be placed in position, and the porcelain dummy ground, adjusted, and waxed into position. The fixture can then be removed and the dummy soldered to the pin and inlay. The bridge is then ready to be cemented into place. If it is a lower molar that is to be used for an abutment, the posterior canal should be used to receive the pin. In such a case, in order to avoid a display of gold, a full-faced porcelain tooth should be used. It should be cemented into a gold cup which spans the

space between the inlay in the molar and the tooth on which the spud rests. The spud, of course, in this instance should be

Fig. 233.—

attached to the side of the gold cup into which the porcelain dummy is to be cemented. Figures 232–234 show the three aspects of such a bridge. Ordinarily the attachment would be

Fig. 234.—

made to the molar and the spud would rest on the bicuspid, but in this instance the attachment is made to the bicuspid and the

spud rests on the molar, as the pulp of the bicuspid had already been destroyed and sufficient anchorage was provided.

If the bridge is for an upper tooth and the patient is in a great hurry, a gold-backed porcelain facing can be waxed into position on the bar while the abutment is in the mouth, and the whole safely removed, invested, and soldered without the necessity of making a model or an occluding bite. As before stated, the great advantage of this bridge lies in the fact that, when it is set, floss-silk can be passed under the little spud which is resting on the tooth opposite the attachment, and the whole surface between the gold, dummy, and gum cleansed thoroughly.

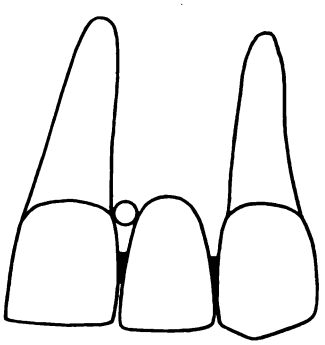

Fig. 235.

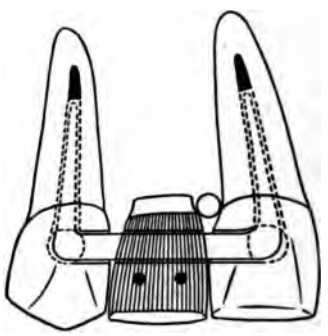

Fig. 236.

Figs. 235, 236.—Bridge fastened on both sides for greater rigidity. An opening should be made underneath as shown by circle, through which silk can be passed for purpose of cleansing gum and fixture.

To accomplish this the contact between the gum and tooth should be curved as little as possible. The dummy and projecting spud can obviously be attached to a gold crown as an abutment if desired. This principle can be applied to a span of one or two teeth, and it can be modified so that the ends may be securely fastened on each side, but this is ordinarily not to be preferred, as such a procedure takes away the individual mobility of each abutment under the stress of mastication. It also makes it necessary that a groove should be made next to the gum for the insertion of floss-silk in order that the daily cleansing may be accomplished. Figure 235 represents the labial aspect and Fig. 236 the lingual aspect. The circle represents the groove

made by the passage of a fissure bur along the margin of the gum and the abutment neck. The floss-silk can be threaded through the eye of a blunt needle, and this passed through the opening for the daily cleansing, but it is sometimes advisable to make a flexible needle for this purpose of brass or gold wire (see Fig. 27). Floss-silk can be threaded in the eye of such a needle and be passed under any fixture by the avenue of a properly constructed groove.

Removable Appliances.—When a greater span than two teeth is required the removable clasp bridge is to be preferred, and as this brings us to the final section of the chapter—the replacement of teeth by clasp fixtures—a short discussion of the subject of **gold clasps** is appropriate. Wherever clasps are to be made or movable bridge work is to be constructed, it is wise to run the model out in fusible metal. Such a metal, composed of 8 parts bismuth, 5 parts tin, and 3 parts lead, melted and added in the order given, will make a casting that is easy of construction and will withstand hammering and the wear of metal adjustment in a manner quite impossible with plaster. When the plaster impression has been taken, it should be dried for a few minutes, then built up with new plaster or moldine to form a cup, and the metal run in at once. A number of these models are shown in figures which follow.

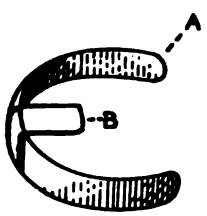

Fig. 237.—Correct type of clasp for bicuspid or molar.

The clasp should be composed of 20 parts gold, 1 of platinum, 2 of copper, and 1 of silver. It should be very stiff and springy, that is, it should be sufficiently rigid to withstand the force of mastication, and yet sufficiently springy to expand over the inequalities of the tooth it clasps and firmly grasp the enamel when it has reached its final position of rest. It should not be less than No. 22 B. and S. gage. Many failures are caused by having the clasp too thin to do its work. The great value of a clasp is in the spud, with which it should always be provided. For instance, in Fig. 237 *A* represents the clasp and *B* the spud that rests upon a groove made in the grinding surface of the tooth, so that the

force of mastication will not cause it to slip up and down under the strain of triturating the food. This spud was apparently first used by Dr. J. D. White some forty years ago, and later was recommended by Dr. Bonwill; but the great value of the spud on a clasp does not seem to have been generally grasped, since it is not ordinarily used. A clasp that moves under the stress of mastication cuts and corrodes the enamel. Although

Fig. 238.—Clasp in position supported by spud.

Fig. 239.—Tooth worn by clasp where no spud was used.

the enamel will soften under the first action of food fermentation, it hardens again as the food fermentation disappears through proper daily cleansing. If, therefore, the clasp is held immovable by the spud resting on the occlusal surface of the abutment, as in Fig. 238, the partly softened enamel will have a chance to re-harden without wear, but if no spud is used upon the clasp, erosion on the sides of the enamel of the tooth will most surely occur, as in Fig. 239. Thus it is essential that a clasp should

Fig. 240.—Missing bicuspid to be replaced by a removable bridge with spring clasps.

grasp the tooth firmly and adhere to it firmly under stress of mastication. The simplest form of clasp plate or bridge is shown in Figs. 240–242. Here the sides of the teeth are parallel, and if the clasps are attached to the plate so that they will clasp the largest part of the abutment, the procedure is simple in the extreme. But if the two abutments are divergent the method of adjusting the clasp becomes complicated, and calls for the greatest nicety of adjustment.

Divergent Abutments.—For instance, in Fig. 243 we have a first bicuspid elongated and divergent from the second molar. Except for the divergence of the axes of the teeth the case is

Fig. 241.—Gold dummy with gold clasps and spud suitable for filling space in Fig. 240.

Fig. 242.—Under surface of fixture shown in Fig. 241.

ideal for a clasp plate. But how to get the two clasps into position is the problem. The method of overcoming this difficulty is as follows: A plain, broad clasp with a spud attached is fitted

Fig. 243.—A difficult span to restore on account of divergence of the abutments.

to the molar, the sides of which should be ground parallel if necessary. A gold plate should be made to fit the gum and a clasp should be adjusted to the lingual side of the bicuspid, so

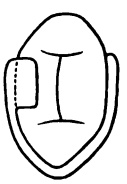

Fig. 244.

Fig. 245.

Figs. 244. 245.—Top and side view of gold clasp that can be slipped on at side of the tooth.

that the sides of the clasp will extend to or just a little beyond the greatest bulge of the tooth, and will not extend over the buccal surface at all (Figs. 244, 245). The clasps and plate should then be soldered together in the position they are to occupy

when finished. The details of such a procedure are so well known that it is taken for granted that the reader is acquainted with them. The problem now is to adjust the clasps so that they will be invisible from the outside of the mouth, and yet absolutely rigid when in final position. The bicuspid clasp should be kept lingually free from its tooth, while the molar clasp is slipped all the way down to its place on the molar, and then a simple rotation of the fixture buccally will push the prongs of the bicuspid clasp into position and complete stability will be obtained. In the same way when the fixture is to be removed, the buccal clasp should first be disengaged by pushing it lingually until the jaws of the clasp are entirely free from the tooth, when

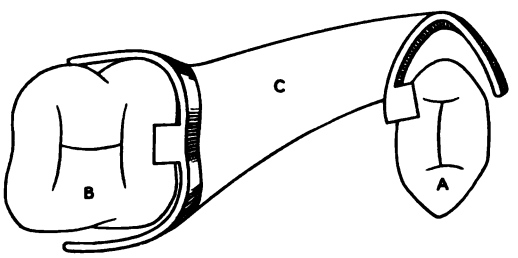

Fig. 246.—Clasp plate being slipped into position where axes of abutments diverge, as shown in Fig. 243. Clasp is slipped well down on molar B while the plate C is slightly rotated inward, then the clasp of the bicuspid A is forced sideways into place.

it will be a simple matter to slip off the molar clasp from its abutment. See Fig. 246. Of course, if an attempt is made to engage both clasps at once it will be impossible to get the fixture into position.

Figures 247, 248 represent a case in which all of the upper teeth except the canines and bicuspids have been lost. In this case a horseshoe plate carrying all of the missing teeth is fastened by clasps to the bicuspids, leaving the hard palate of the mouth uncovered. In the same way two canines or bicuspids can be made to support an entire upper denture. Two clasps properly adjusted to two molars on opposite sides of the mouth can readily support an entire single denture, and at a pinch two molars on the same side can be made to do it, but care must be

taken to trim the sides of each molar so that they will be parallel and give the maximum support to the fixture, even if the enamel has to be cut through. In such a case the teeth can be capped with gold caps with parallel sides that do not extend beneath the

Fig. 247.

Fig. 248.

Figs. 247, 248.—Upper denture supported by two canines.

gum; and if the teeth are sensitive to heat and cold, it is always good practice in any case to destroy the pulp and carefully fill the canals. The following illustrations show some interesting types of fixtures capable of being successfully fastened into posi-

tion by clasps. Figure 249 represents the two aspects of a finished plate. Figure 250 shows the gold plate before the teeth

Fig. 249.—Under and upper view of lower denture supported by two bicuspids and a molar.

are added, and the fusible metal model. Figure 251 represents an interesting illustration of an upper and lower restoration on the right side of the mouth. *A* represents the fusible metal

Fig. 250 .—Figure on the left represents the gold plate and clasps of Fig. 249 before the teeth are added. On the right is the fusible metal model.

models on an articulator, *B* represents the upper fixture, *C* the lower fixture, *D* and *E* represent the gold plates of these fixtures before the teeth are added, *F* and *G* represent respectively the

porcelain-faced gold-backed bicuspid. The problem was to make a bridge that would not show the gold clasp at the neck of *B*. A broad gold clasp was made for *A*. A pit and groove were made in the grinding surface of *B*, as is shown by the dotted

Fig. 254.—Labial aspect of bridge in position.

lines (Fig. 254). In Fig. 255 a bent bar and half clasp were adjusted, as is shown by *C* and *D*, the attachment to the bicuspid being obtained by grasping the inner cusp between the pin *D* and the half clasp *C*. Figures 254 and 255 show the labial and

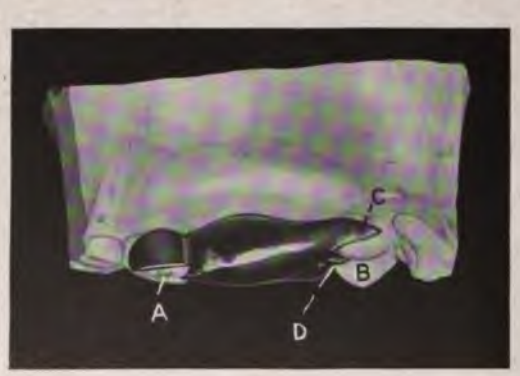

Fig. 255.—Buccal aspect of bridge in position.

buccal aspects of the bridge in position, while the bridge itself is shown in Fig. 253.

The Double Clasp Bridge.—There is one type of fixture, however, that deserves special mention, and that is the fixture

that replaces two molars or a molar and bicuspid and is attached on only one side by a double clasp or a clasp and elongation of the plate. A case of special interest is one showing the construction of an all-porcelain bridge attached to the abutment by a double gold clasp and spud (Figs. 256, 257). As observed, the teeth back of the second bicuspid are missing. *B* represents the gold clasp, No. 22 gage, fitted to the second bicuspid, to the ends of which clasp are added gold projections, *C*, which half embrace the first bicuspid near the gum line. A piece of pure gold, No. 35 B. & S., is soldered to the clasp at the posterior aspect of the second bicuspid and burnished into the occlusal groove prepared to receive it. When this is stiffened with half-

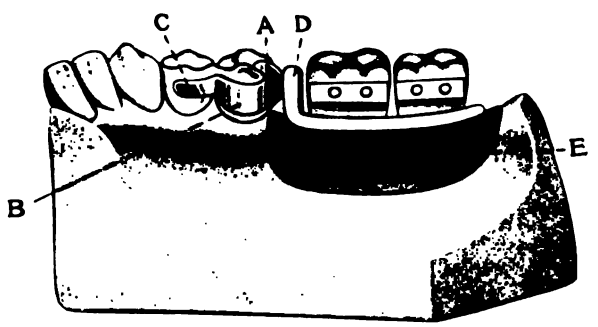

Fig. 256.—Lingual view of all-porcelain bridge with gold clasp in process of construction.

round platinized gold wire and solder it will form the spud *A* that will prevent the clasp from being driven into the gum by the force of mastication. If the occluding tooth should interfere with the spud, the tooth should be correspondingly shortened. The clasp and spud should now be polished to the lines desired, and a thin coating of borax flowed over them so as to expedite future soldering. They should then be placed upon the model and a right-angled piece of No. 14 iridio platinum wire, represented by *D*, should be adjusted to it at the gum line. *E* represents platinum foil, 0.001 inch thick, burnished and trimmed to fit the model. The angle wire, *D*, should be placed in position on it; continuous gum porcelain body placed on the angle wire;

and platinum foil and rubber teeth of suitable size and shade placed upon the body, just as in the preparation of the wax model of a rubber case. When the body has been carved to the proper lines of the gum, the platinum foil, angle, bar, teeth, and body should all be removed together, placed in the oven and given a thorough glaze. When the porcelain is cool the platinum foil should be stripped off and new foil burnished to the model. A thin layer of porcelain paste should then be placed on the platinum foil and the porcelain block pressed and tapped down upon it until the articulation is just a little high. This extra height is necessary in order that perfect occlusion may be obtained by grinding when the case is finally fitted in the mouth. The additional porcelain paste is necessary to make up for the contraction caused by the fusing of the porcelain piece in the first bake.

Fig. 257.—Buccal view of finished all-porcelain bridge with gold clasp for attachment.

When the porcelain has been carved a second time to a satisfactory line, it is removed again on the platinum foil and placed in the oven for another baking. After baking and after the platinum foil is removed, the porcelain block should accurately fit the model. If pink gum enamel is necessary there will have to be a third baking, but for this no platinum foil will be needed to preserve the contour, as the first body fuses at a higher point than the enamel. When the porcelain block is finished, we have a double clasp with a spud and a porcelain block with a platinum bar running through it. It now remains to join them together. The clasp is placed in position on the model; the end of the porcelain block that goes next to the clasp is ground until the platinum bar is clean and fresh enough to receive the solder. Then to the end of the ground porcelain a thin backing of pure gold should be burnished to make a tight joint with the porcelain,

and held in place with a little hard wax. The middle of this backing should be torn so as to expose the platinum and make it possible to solder together the clasp, gold backing, and platinum bar. The clasp and porcelain should then be placed on the cast and waxed into accurate position. They are then removed, invested, and soldered in the usual way. Figure 257 represents

Fig. 258.

Fig. 259.

Fig. 260.

Figs. 258–260.—Three aspects of a double clasp bridge with gold plate and vulcanite attachment.

the finished piece. It might be well to state that varnishing the gum enamel with gum shellac varnish prevents the investment from sticking to it during the process of soldering.

It is obvious that after the double clasp has been made as just described, instead of using porcelain, a gold plate can be swaged, fitted, and soldered to the clasp. Porcelain teeth can be

Fig. 261.

Fig. 262.

Fig. 263.

Fig. 264.

Figs. 261–264.—Double clasp bridge attached to natural teeth on one side only. Composed of gold plate and teeth cemented into suitably prepared gold box.

attached to this plate with vulcanite, as is shown in Figs. 258–260. In this instance the single clasp is used externally and the double support is given on the inside alone.

The All-gold and Porcelain Fixture.—Where it is desired to have teeth cemented into gold so that only the gold and porcelain will show, the procedure is simple and easy. The plate and clasp should be made as usual and the teeth adjusted and waxed into position (Fig. 261). Then a piece of No. 30 pure gold should be fitted and burnished around the buccal margins of the teeth and plate, as shown in Fig. 262. The teeth and supporting wax

Fig. 265.

Fig. 266.

Fig. 267

Figs. 265–267.—Removable gold and porcelain bridge attached to natural teeth on one side only. Teeth are set in gold cups built into position with sponge gold and finally filled full of 22-karat solder.

are then removed and the burnished gold, *A*, soldered to the plate. The teeth should then be replaced on the plate and another piece of gold, designated by *B*, adjusted on the palatal side (Fig. 263). The ends should lap behind the molar. The teeth are once more removed and the gold soldered to form a perfectly fitting gold box (Fig. 264), into which the teeth can be cemented with silicious cement.

Figures 265–267 show a method of fastening the teeth to the plate by means of gold cups, which gold cups are built up into position by sponge gold, which is later filled full of gold solder. Figure 265 shows the lingual side of the same type of plate with the molar and bicuspid in position. Gold cups made of 0.003 inch pure gold have been adjusted to the porcelain as is shown in the illustration. Then a thin film of hard wax is flowed over the base of the gold cups and the adjacent plate, and sponge gold is rapidly and firmly packed in around the teeth and between the teeth and plate (Fig. 266). If necessary a little hard wax can be flowed into the sponge gold to add to its adhesiveness. Then the teeth can be coaxed out of the cups, as shown in Fig.

Fig. 268.—Interesting type of removable denture composed of gold and porcelain only.

267, and the entire sponge gold mass filled with solder. An investment may be used, but usually it is unnecessary. When the teeth are cemented into the cups the porcelain and gold alone are visible.

Figures 268–271 represent a completed plate composed of gold and porcelain made on the principle of the gold cup method just described.

The cases might be multiplied indefinitely, but if the principles demonstrated are judiciously applied it will be found that any partial, movable denture can be readily made.

The method of making full upper and lower dentures supported by suction has not been discussed, as the procedure is

Fig. 269.—

Fig. 270.—

Fig. 271.—

well known, and success depends largely upon the adaptability of the mouth of the patient. But where a single tooth can be saved to act as a support for what would otherwise be a full upper or lower denture, the efficiency for mastication will ordinarily be increased 100 per cent. and the peace of mind of the patient will be assured by the certain knowledge that the plate will not suddenly become dislodged, to his mortification and annoyance. In such a case a well-fitting clasp will prove of invaluable assistance.

The normal tooth matches the undertone of the skin. Therefore, in full dentures where there are no teeth from which to obtain the color, the following expedient may be used: The skin of the patient should be pressed and the color noted before the blood returns to the capillaries. On a cold day this method will be particularly effective.

CHAPTER XI

EXPERIMENTS CONCERNING THE STRENGTH, SOLUBILITY, AND ADHESIVENESS OF VARIOUS CEMENTS

Silicious Cements.—Dr. Ames, the great authority on dental cements, says that "the silicious cements are really oxyphosphate of calcium, and should be considered as being so compounded that the cement-making phenomenon comes from the action of phosphoric acid on calcium oxid or basic calcium silicate, the action being retarded by the intimate blend with alumina and silica." The action on calcium oxid alone would be very violent. The alumina and silica act as diluents and give integrity to the resulting mass. The formulæ of the various cement powders are practically identical with that of calcium feldspar. Feldspar furnishes the chief ingredient of porcelain, and these cements, therefore, may reasonably be considered porcelain in which there is agglutination by chemical action instead of agglutination by heat.

The term "silicious cement" is more accurately descriptive than the term "silicate cement." Normal silicates do not afford cement-making properties. Silicious mixtures may.

Silicious cements will present no difficulties in manipulation if the setting process is considered as being practically that of the oxyphosphates. Mixing cements upon a slab of known temperature has become a habit with a large number of operators. This is accomplished by using the flat side of a bottle containing water of the temperature desired (Fig. 272), which temperature is ascertained by a thermometer inserted through the cork. Cold spigot-water ordinarily is sufficient to carry off the heat of the chemical reaction, but for those who wish to make the water colder, almost to the dew point, a wet and dry bulb hydrometer is a great convenience. The colder the slab is kept, without excess moisture being precipitated from the air, the greater length of time will there be for the manipulation of the cements.

When setting occurs in a judiciously constructed silicious cement the chemical balance is automatically established. As the warmth of the tooth is imparted to the cement, the proper amount of liquid and powder tend to combine, and the crystallization begins next to the tooth, continuing toward the center of the mass. If the liquid has been in excess in the mixture it will be left on the surface, and if there has been a shortage of liquid and an excess of powder, the final surface will have a honeycombed appearance. For these reasons it is wise to have sufficient liquid to make the surface slightly moist when the cement is being inserted, and any excess moisture may then be finally taken up by an application of powder. Sufficient time should always be allowed for the proper introduction of the cement into the cavity, as the structure of silicious cement is seriously injured if it is manipulated after the process of crystallization has actually begun.

Fig. 272.—The Ames cement slab—a flat-sided bottle filled with cold water, on which cement can be mixed.

When the cement is in position and has started to set it is sometimes good practice to flow hot paraffin upon it. This will cause a prompt setting, and will tend to save the time of the operator and prevent the dilution with saliva of the uncombined ingredients. It will also tend to remove any risk of the pulp being injured by the free acid. If such a risk exists, however, it can readily be obviated by lining the cavity with varnish prior to the insertion of the filling. Ordinarily such a precaution is not necessary, but where there is a near approach to the pulp it is always wise to use the cavity lining. In cases where the pulps are supposed to die from the action of the cement, there is always

a question whether the pulp died from the action of the cement ingredients, or whether it had not already been fatally attacked by infection before the filling was inserted.

The adhesion of silicious cements counteracts a possible tendency toward shrinkage because of the adhesion to the cavity wall. This adhesion, while the cement is soft, will cause a shrinkage toward the wall rather than away from it, since the cement in contact with the cavity wall is the first portion to set because of the heat imparted by the tooth.

Phosphate of Zinc Cements.—The following experiments were made some years ago with phosphate of zinc cements before the introduction of silicious cements; and although the silicious cements by their insolubility have made these tests on the solubility of phosphate cement films of less importance, nevertheless, since phosphate cement is still so universally used for the retention of crowns, bridges, and bands, these experiments are reported with the hope that not only the facts brought to light may prove of value, but also that the technic of the experimentation may be of use in aiding those who would like to extend the scope of these experiments.

Before the days of silicious cements the phosphate of zinc cement line arising from the removal of the matrix was always a subject of general criticism and discussion in porcelain inlay work. By some it was deemed a great advantage to use No. 30 gold foil for a matrix. This was so because No. 30 gold foil is one-third the thickness of the 0.001-inch platinum foil. Therefore, the gold was believed to make a finished filling that would leave a cement line one-third the thickness of the cement line of a filling where the platinum matrix was used.

These and other statements prompted me to undertake experiments for the purpose of solving the following questions:

A. (1) What is the minimum line of cement that can be obtained at the edges of an inlay? (2) Is maintained pressure until the cement sets or fineness of cement grit the more responsible for obtaining a fine cement line? (3) Is it of any practical value to maintain pressure for more than a minute while the cement is setting?

B. (1) Does a thick or thin line of cement give the greater strength of retention? (2) Is a fine grit or coarse grit cement the stronger?

C. (1) What is the adhesive strength of glazed porcelain cemented to smooth ivory? (2) What is the adhesive strength of etched porcelain cemented to smooth ivory? (3) What is the adhesive strength of etched porcelain cemented to undercut ivory? (4) What is the adhesive strength of undercut porcelain cemented to undercut ivory?

Tests on Cement Line.—To ascertain the minimum thickness of the cement line pieces of glass ¼-inch square were cemented to pieces of glass ½-inch square. These pieces of glass were so true as to permit atmospheric suction when pressed together in a dry state. To facilitate the removal of the cement film the surface was slightly oiled by rubbing on the skin. Pressures of 8, 25, 50, and 100 pounds were used with various grits of the Harvard cement, as well as with Ames' inlay cement, to see whether pressure or fineness of grit was the more responsible for the thin cement line. These pressures in half the number of instances were maintained for a minute only, and the further setting continued without external pressure. With the other half the pressure was maintained until the setting was complete. This was done to see if the maintaining of the pressure for more than one minute was of any practical value in reducing the cement line. The ¼-inch square film was chosen as a standard cement surface. This is larger than the average surface of a porcelain inlay, but as from 2 to 6 pounds was found from experiment to be the pressure ordinarily applied to the average fillings in the mouth, it was considered that definite conclusions could be obtained from 8, 25, 50, and 100 pounds pressure applied to films ¼-inch square, and that these films would be large enough to measure at several points and give an average thickness. The measurements for thickness were made with the Black amalgam micrometer, and those for pressure with the Black dynamometer.

All of the cement films were allowed to set in a dry state, and it was found that when they were dipped in water the glass pieces separated and the complete film was easily dislodged and

floated off. It was then picked up on a camel's-hair brush and attached to the face plate of the micrometer, when the various readings were obtained by moving the film of cement on the face plate under the measuring terminal. The film of water between the cement film and the face plate was found to be 0.0001 inch in thickness in the following way: A reading was taken while the wet film of cement was still adherent to one of the glass pieces. The cement film was then loosened so that a film of water could creep underneath and the reading again taken. By numerous such tests the water film was found to be 0.0001 inch. Thus 0.0001 inch will be deducted from every reading given in the tables of film measurements unless otherwise stated. The readings of the Black amalgam micrometer were controlled by the Brown & Sharpe micrometer, and while the Brown & Sharpe micrometer could not measure quite so minutely as the Black, in so far as they could be compared, the measurements for both instruments were the same. The pressure generally used in cementing fillings in the mouth was arrived at in the following manner: Porcelain inlays having a surface about $\frac{1}{8}$-inch square were made to fit cavities in a block of ivory. This block was then placed on scales and the fillings cemented into position. Without looking at the dial, pressures were used such as were felt to be ordinarily used in the mouth, while an assistant noted the readings. It was found that 2 pounds was the pressure used where there were frail edges, 3 to 4 pounds were safely applied to ordinary fillings, and 6 pounds seemed the maximum pressure that would ordinarily be applied to a filling with a surface $\frac{1}{8}$-inch square. This equals $\frac{1}{2}$ pound for frail fillings of $\frac{1}{16}$-inch square surface. These measurements on the force usually applied in the mouth make the tests of 8 and 25 pounds pressure the only ones of practical working value, but, as previously stated, films of cement were also made under 50 and 100 pounds pressure to determine the minimum cement line, and to determine whether the pressure under which the cement was set or the fineness of the grit was the more responsible for the minimum line.

Of the Harvard cement four different grits were used: (1)

Harvard coarse, such as was ordinarily used for making fillings and such as was for a long time ordinarily used for cementing inlays. (2) Harvard inlay cement, as prepared for Dr. Jenkins. (3) A finer grit Harvard which I had especially prepared and used up to the time of these tests. This I shall speak of as the Harvard special. (4) A Harvard cement pulverized in an agate mortar until the grit was almost imperceptible to the teeth, and which will be referred to as Harvard pulverized.

No use was made of a reduced grit of the Ames inlay cement, as it was found that any reduction of the powder so hastened the setting as to render it unavailable.

Using 8 pounds pressure for one minute the average thickness of the cement was found to be as follows:

Harvard coarse	.0024 inch
Harvard inlay	.0017 "
Harvard special	.0015 "
Harvard pulverized	.0003 "
Ames inlay	.0010 "

(See Tables 1–6, 13–15.)

The tests of 25, 50, and 100 pounds pressure were made only on the Harvard special and the Ames inlay cement. (See Tables 7 to 12, 16 to 21.) These were only of interest in showing that there was an inverse ratio between the pressure and the cement line. In other words, the greater the pressure, the finer the line obtained. The Harvard special at 100 pounds gave a line 0.0009 inch in thickness and the Ames at 100 pounds gave a line 0.0006 inch in thickness, while the Harvard pulverized at but 8 pounds gave a line less than 0.0003 inch. Therefore it seems that a finer grit is a much more important factor than pressure in obtaining a fine line.

Maintaining the pressure until setting was complete instead of maintaining it for one minute, was found to result in a difference of only 0.00005 inch, a difference less than the probable working error of the operator. The result was obtained by taking the general average of all the films made under maintained pressure and comparing it with the general average of all the films set under a pressure for one minute only. However, though this

is of little importance in reducing the cement line, it is possible that it is of great importance in increasing the adhesion. This will be discussed later.

In preparing each of the following tables five and occasionally six or seven measurements were taken on each of five similar films.

TABLE 1.—HARVARD COARSE W.

Harvard coarse W = Harvard coarse grit, pressure 8 pounds on one-quarter inch square glass for 1 minute.

Water film that floated cement on face plate measured 0.0001 inch. Therefore, 0.0001 inch should be subtracted from each result as an error due to measuring the water film with the cement film.

Inch	Inch	Inch	Inch	Inch		Average
.00275	.0026	.00255	.0027	.00265	=	.00250
.00245	.00265	.00270	.00250	.00260	=	.00258
.00242	.00215	.00225	.00250	.00236	=	.002526
.00242	.00260	.00280	.00265	.00265	=	.002624
.00220	.00266	.00230	.00220	.00225	=	.002442

General average, .002534 inch.
Corrected average, .002434 inch.

TABLE 2.—HARVARD COARSE W′

Harvard coarse W′ same as Harvard coarse W except that pressure is maintained until setting is complete.

Inch	Inch	Inch	Inch	Inch		Average
.00260	.00285	.00270	.00270	.00260	=	.00269
.00230	.00235	.00225	.00215	.00215	=	.00226
.00280	.00272	.00250	.00276	.00284	=	.002724
.00290	.00300	.00284	.00294	.00290	=	.002901
.00250	.00250	.00250	.00245	.00245	=	.002408

General average, .002596 inch.
Corrected average, .002496 inch.

TABLE 3.—HARVARD INLAY W

Harvard inlay W = Harvard inlay cement, one-quarter inch square glass, 8 pounds pressure for 1 minute and then released until setting occurs.

Inch	Inch	Inch	Inch	Inch		Average
.00175	.00180	.00180	.00185	.00180	=	.0018
.00165	.00182	.00186	.00186	.00165	=	.00179
.00180	.00175	.00165	.00176	.00180	=	.00173
.00170	.00180	.00192	.00185	.00180	=	.00181
.00178	.00185	.00184	.00175	.00175	=	.00179

General average, .00178 inch.
Corrected average, .00168 inch.

TABLE 4.—HARVARD INLAY W′

Harvard inlay W′ = Harvard inlay W, 8 pounds pressure maintained until complete setting occurs.

Water film that floated cement on face plate measured 0.0001 inch. Therefore, 0.0001 inch should be subtracted from each result as an error due to measuring the water film with the cement film.

Inch	Inch	Inch	Inch	Inch		Average
.00180	.00170	.00160	.00175	.00170	=	.00171
.00175	.00188	.00175	.00175	.00175	=	.00177
.00185	.00195	.00190	.00195	.00190	=	.00195
.00205	.00172	.00195	.00185	.00195	=	.00194
.00165	.00170	.00175	.00170	.00160	=	.00168

General average, .00181 inch.
Corrected average, .00171 inch.

TABLE 5.—HARVARD SPECIAL W

Harvard Special = Harvard cement especially prepared for Dr. Head and used by him before these tests were undertaken.

Harvard Special W = Harvard special, one-quarter inch glass, 8 pounds pressure for 1 minute and released = one-eighth inch glass under 2 pounds pressure.

Water film that floated cement on face plate measured 0.0001 inch. Therefore, 0.0001 inch should be subtracted from each result as an error due to measuring the water film with the cement film.

Inch	Inch	Inch	Inch	Inch		Average
.0015	.00145	.00155	.00155	.00155	=	.00152
.0017	.0018	.0019	.0017	.0019	=	.0018
.00195	.0015	.0018	.0017	.00195	=	.00176
.00155	.00155	.00165	.00165	.0016	=	.0016
.0015	.00155	.0016	.0017	.0018	=	.00163

General average, .00166.
Corrected average, .00156 inch.

TABLE 6.—HARVARD SPECIAL W′

Harvard Special W′ = same as Harvard Special W, only pressure is continued for 15 minutes or until set.

Inch	Inch	Inch	Inch	Inch		Average
.0015	.0016	.0015	.0017	.00175	=	.00161
.00145	.0015	.00165	.0016	.00145	=	.00153
.00195	.00175	.0018	.0017	.00195	=	.00171
.00145	.00155	.0016	.00175	.0018	=	.00163
.0016	.0018	.0017	.00145	.00195	=	.00164

General Average, .00162 inch.
Corrected average, .00152 inch.

TABLE 7.—HARVARD SPECIAL X

Harvard Special X = Harvard special, 25 pounds pressure for 1 minute and released.

Water film that floated cement on face plate measured 0.0001 inch. Therefore, 0.0001 inch should be subtracted from each result as an error due to measuring the water film with the cement film.

Inch	Inch	Inch	Inch	Inch		Average
.00145	.00155	.00155	.00155		=	.00152
.00155	.00142	.00145	.00148	.00134	=	.00155
.00145	.00130	.00148	.00160	.00145	=	.00145
.00160	.00152	.00144	.00164	.00155	=	.00155
.00150	.00172	.00161	.00162	.00152	=	.00159

General average, .00153 inch. Corrected average, .00143 inch.

TABLE 8.—HARVARD SPECIAL X′

Harvard special X′ = Harvard special, 25 pounds pressure until set, or about 30 minutes.

Inch	Inch	Inch	Inch	Inch	Inch		Average
.0016	.00135	.0013	.0016	.0013	.0014	=	.00145
.00125	.00115	.00120	.00120	.00135		=	.00145
.00132	.00125	.00134	.00125	.00130		=	.00129
.00132	.00132	.00125	.00130	.00130		=	.00130
.00110	.00122	.00110	.00110	.00108		=	.00129

General average, .00135 inch. Corrected average, .00125 inch.

TABLE 9.—HARVARD SPECIAL Y

Harvard special Y = Harvard special, under 50 pounds pressure, one-quarter inch glass, 1 minute and then released.

Inch	Inch	Inch	Inch	Inch		Average
.00120	.00125	.00145	.00125		=	.00129
.00105	.00120	.00085	.00098	.00080	=	.000976
.00120	.00145	.00145	.00135	.00135	=	.00136
.00090	.00100	.00095	.00100	.00085	=	.00094
.00160	.00140	.00150	.00135	.00135	=	.00124

General average, .00116 inch. Corrected average, .00106 inch.

TABLE 10.—HARVARD SPECIAL Y′

Harvard special Y′ = Harvard special, under 50 pounds pressure, one-quarter inch glass, until set.

Inch	Inch	Inch	Inch	Inch	Inch	Inch		Average
.00125	.0015	.00125	.0013	.0015	.00135	.0015	=	.00133
.00135	.00140	.00130	.00160	.00150			=	.00143
.00130	.00115	.00120					=	.00122
.00110	.00115	.00135	.00140	.00135	.00105		=	.001235
.00135	.00110	.00125	.00110	.00100			=	.00116

General average, .001275 inch. Corrected average, .001175 inch.

TABLE 11.—HARVARD SPECIAL Z

Harvard special Z = Harvard special, under 100 pounds pressure, one-quarter inch glass, 1 minute, released.

Inch	Inch	Inch	Inch	Inch		Average
.00140	.00125	.00155	.00120	.00150	=	.00138
.00120	.00125	.00125	.00110	.00125	=	.00121
.00110	.00115	.00095	.00120	.00120	=	.00112
.00110	.00110	.00125	.00130	.00120	=	.00121
.00130	.00120	.00130	.00135	.00125	=	.00128

General average, .00124 inch. Corrected average, .00114 inch.

TABLE 12.—HARVARD SPECIAL Z′

Harvard special Z′ = Harvard special, 100 pounds pressure until set, one-quarter inch glass.

Inch	Inch	Inch	Inch	Inch	Inch		Average
.00095	.00100	.00125	.00100	.00095	.001	=	.00102
.00085	.00100	.00070	.00090	.00115		=	.00092
.00110	.00110	.00098	.00105	.00080		=	.00101
.00110	.00085	.00100	.00105	.0090		=	.00098
.00110	.0090	.00100	.00105	.0090	.00110	=	.00101

General average, .00099 inch. Corrected average, .00089 inch.

TABLE 13.—HARVARD PULVERIZED W′

Harvard pulverized W′ = Harvard pulverized cement, pressure of 8 pounds maintained until setting occurred. Factor of error due to water film not present, as the measurements were made on adhesive films, the cement film being too thin to be removed.

Inch	Inch	Inch	Inch	Inch
.00015	.0003	.00015	.0002	.00035
.00035	.00025	.0002	.00035	.0003
.0003	.00025	.00025	.0003	.0003

General average, .00027 inch.

Tests of the Ames inlay cement to determine the thickness of the film under given surfaces, times, and pressures were as follows:

TABLE 14.—A-W

Ames-W = one-quarter inch square glass at 8 pounds pressure for 1 minute; one-eighth inch square glass at 2 pounds for 1 minute.

Water film that floated cement on face plate measured 0.0001 inch. Therefore, 0.0001 inch should be subtracted from each result as an error due to measuring the water film with the cement film.

Inch	Inch	Inch	Inch	Inch	Inch	Inch		Average
.00105	.0011	.00105	.0012	.001	.00105		=	.00107
.0014	.0012	.00115	.0013	.0015	.0011	.00125	=	.00127
.0012	.0012	.00115	.0013	.0012			=	.00121
.00115	.0012	.00115	.00105	.00105			=	.00112
.0012	.00125	.0015	.0013	.0012			=	.00129

General average, .00119 inch. Corrected average, .00109 inch.

TABLE 15.—A–W′

Ames–W′ = one-quarter inch square glass at 8 pounds pressure for 15 minutes or until complete setting = one-eighth inch square glass at 2 pounds for 15 minutes or until set.

Inch	Inch	Inch	Inch	Inch	Inch		Average
.001	.00095	.001	.001	.00105	.001	=	.001
.001	.0011	.00105	.001	.00105		=	.001+
.001	.001	.0011	.0012	.0012		=	.0011
.00105	.00105	.0011	.0011	.00112		=	.0011+
.00112	.00112	.00112	.00112	.00112		=	.00112

General average, .00106 inch.
Corrected average, .00096 inch.

TABLE 16.—A–X

Ames–X = one-quarter inch square glass, 25 pounds pressure for 1 minute, released, and allowed to harden.

Inch	Inch	Inch	Inch	Inch		Average
.001	.001	.001+	.001	.00105	=	.00101
.00105	.0085	.0009	.00095	.001	=	.00095
.00095	.001	.0011	.00095	.001	=	.001
.00085	.0009	.00105	.0011	.001	=	.00098
.00095	.001	.00105	.001	.00095	=	.00099

General average, .000986 inch.
Corrected average, .000886 inch.

TABLE 17.—A–X′

Ames–X′ = one-quarter inch square glass, 25 pounds continuous pressure until hard.

Inch	Inch	Inch	Inch	Inch	Inch		Average
.00085	.0009	.0009	.0009	.0009		=	.00089
.00085	.0009	.00105	.0011	.001		=	.00098
.0012	.001	.0014	.0012	.00095	.00103	=	.00113
.00095	.00082	.001	.0011	.00085		=	.00094
.0009	.001	.0009	.0011	.00095		=	.00097

General average, .000982 inch.
Corrected average, .000882 inch.

TABLE 18.—A–Y

Ames–Y = one-quarter inch square glass, 50 pounds pressure for 1 minute, released, and allowed to harden.

Inch	Inch	Inch	Inch	Inch		Average
.00075	.0008	.00085	.00075	.00085	=	.0008
.0008	.00095	.00085	.00085	.0009	=	.00085
.0009	.00085	.0008	.00088	.00085	=	.000856
.0008	.0008	.0009	.00095	.00085	=	.00086
.00065	.00075	.0008	.00075	.00085	=	.00076

General average, .000825 inch.
Corrected average, .000725 inch.

TABLE 19.—A–Y′

Ames–Y′ = one-quarter inch square glass, 50 pounds continuous pressure until hard.

Inch	Inch	Inch	Inch	Inch		Average
.0008	.00075	.00082	.00082	.00085	=	.000808
.0008	.00075	.00077	.00072	.00069	=	.000746
.00095	.00085	.0007	.0008	.0008	=	.00082
.001	.00085	.00075	.00085	.001	=	.00089
.0007	.00085	.0007	.0008	.0007	=	.00075

General average, .000802 inch.
Corrected average, .000702 inch.

TABLE 20.—A–Z

Ames–Z = one-quarter inch square glass, 100 pounds pressure for 1 minute, released, and allowed to harden.

Inch	Inch	Inch	Inch	Inch		Average
.00085	.00085	.00095	.0009	.00005	=	.00093
.00085	.0007	.00095	.0007	.00075	=	.00079
.00095	.00085	.0007	.0008	.0008	=	.00082
.001	.00085	.00075	.00085	.001	=	.00089
.0011	.001	.00095	.00095	.0011	=	.00102

General average, .00089 inch.
Corrected average, .00079 inch.

TABLE 21.—A–Z′

Ames–Z′ = one-quarter inch square glass, 100 pounds pressure until hard.

Inch	Inch	Inch	Inch	Inch	Inch		Average
.0008	.00082	.00075	.0007	.0008	.0007	=	.00076
.00065	.00075	.0007	.0006	.0008	.00085	=	.000725
.00075	.00065	.0008	.0007	.00065		=	.00071
.00061	.00073	.00061	.0006	.00062		=	.000634
.0006	.00065	.00065	.00085	.00075		=	.00007

General average, .000704 inch.
Corrected average, .000604 inch.

TABLE 22.—ASH W

Ash W = Ash common phosphate of zinc cement, 8 pounds pressure, one-quarter inch square glass, for 1 minute, and released.

Inch	Inch	Inch	Inch	Inch		Average
.0021	.00215	.00195	.00195	.00212	=	.00206
.0022	.0023	.0024	.00233	.00235	=	.00230
.00231	.00230	.00230	.00230	.00230	=	.00230
.00215	.0029	.00265	.00210	.00220	=	.0024
.00280	.0029	.00290	.00310	.00280	=	.0029

General average, .00239 inch.
Corrected average, .00229 inch.

Comparisons are given of corrected general averages of cement lines made under 8 pounds pressure. W = released after 1 minute. W′ = pressure maintained until setting is complete. Except in Harvard pulverized, which was measured adhering to glass, 0.0001 inch was subtracted from each as a factor of error.

Harvard coarse W	.00243 inch
Harvard coarse W′	.00249 inch
Harvard inlay W	.00168 inch
Harvard inlay W′	.00171 inch
Harvard special W	.00156 inch
Harvard special W′	.00152 inch
Harvard pulverized	.00027 inch
Ash W	.00229 inch
Ames–W	.00109 inch
Ames–W′	.00096 inch

X = 25 pounds pressure one-quarter inch square glass for 1 minute, then released.

X′ = 25 pounds pressure one-quarter inch square glass until complete setting occurs.

Y = 50 pounds pressure one-quarter inch square glass for 1 minute, then released.

Y′ = 50 pounds pressure one-quarter inch square glass until setting occurs.

Z = 100 pounds pressure one-quarter inch square glass for 1 minute, then released.

Z′ = 100 pounds pressure one-quarter inch square glass until setting occurs.

H = Dr. Head's special Harvard.

A = Ames Inlay Cement.

Comparison of corrected general averages between the Harvard special and the Ames cements:

H X	= .00143 inch	A X	= .000886 inch
H X′	= .00125 "	A X′	= .000882 "
H Y	= .00106 "	A Y	= .000725 "
H Y′	= .00118 "	A Y′	= .000702 "
H Z	= .00114 "	A Z	= .00079 "
H Z′	= .00089 "	A Z′	= .000604 "

Having discussed the fineness of cement lines and having arrived at the conclusion that the fine cement line is due to the fineness of the cement powder, rather than to the amount of pressure applied or to the length of time the pressure is maintained, let us take up the question of strength and adhesion. As before stated, the Harvard cements and the Ames inlay cement were the only ones investigated at length. Of Harvard, the coarse and the pulverized were used as two extremes to show which gave the most strength and the greatest adhesion.

Adhesion of Cement.—The first adhesion tests were made with the glass squares etched with hydrofluoric acid. Pieces ¼-inch square were cemented to pieces ½-inch square under 8 pounds pressure for fifteen minutes, and set in water over night. Two specimens of Harvard coarse, three of Harvard pulverized, and two of the Ames inlay were thus prepared. In the morning the glasses all fell apart. This result showed that the expansion and contraction of the glass was sufficient to tear it loose from the cement. At first it was thought the tests would have to be made in a culture oven at a temperature of 98° F., the normal temperature of the mouth; but tests with a clinical thermometer in the mouth after eating hot soup at 152° F. showed that the mouth could by this means be raised to a temperature of 108° F. This demonstrated that experiments made in an even temperature would not be fair, as it was apparent that a filling might be subjected to hot soup at a temperature of 152° F. and ice cream at a temperature of 32° F., a variation of 120 degrees. Therefore, for the adhesion tests glass was discarded and pieces of porcelain ¼-inch square and $\frac{1}{16}$-inch thick, perfectly flat, were cemented to a block of ivory that had been draw-filed flat and smooth. In all of these tests the porcelain and ivory were washed with alcohol and dried before they were cemented together. In the tests where the porcelain was only ground with a wheel the results were so discouraging that they will only be summarized. The porcelain pieces were carefully ground so as to be the same size in order that a just comparison could be obtained.

A number of tests were made under 8 pounds pressure and thumb pressure until setting was complete, and some under

thumb pressure for a minute, and then released. The Harvard cement was paraffined before being placed in water. The Ames cement was not paraffined, as the Ames cement set better when exposed to water. The following morning the pieces of ivory and porcelain were removed from the water, dried with a cloth, and the paraffin and cement carefully cleansed from the edges. The ivory block was then placed in a vise and the pieces of porcelain pulled off sideways with the hook of a spring balance scale. Before each test the face of the scale was blackened in a gas jet so that the indicator would mark the highest mark reached as the cement broke and the pointer flew back. These same spring scales were arranged with nails and board so that they could be used to maintain the required pressure on the cement films as they were setting. The results were so insignificant, there being practically no difference between the maintained pressure, the temporary pressure, the 8 pounds pressure, and the 4 pounds or thumb pressure, that for the plain, ground porcelain surfaces only those made under thumb pressure, released after one minute, and then set in water over night will be quoted. The tests made with the Harvard coarse gave a breaking strain of the following figures: 3, 5, 14, 19, 21, 13, 27, 28, 34, 42 ounces—an average of 20 ounces. Harvard pulverized gave the following figures: 10, 10, 16, 8, 31, 35, 11, 16, 54, 32 ounces—an average of 22 ounces. The Ames cement under similar conditions gave: 0, 0, 64, 20, 10, 6, 0, 0, 10, 32 ounces—an average of 14 ounces. These roughly show a slight superiority of adhesion for the pulverized Harvard, but the result is not sufficiently conclusive to be of great value. It certainly shows that the adhesion of cement to ground porcelain and to flat, smooth ivory is slight and unreliable. In these tests the cement film seemed to break away equally from the porcelain and ivory.

Having proved that draw-filed ivory and ground porcelain have very little adhesion to cement, the pieces of porcelain were etched for thirty seconds with hydrofluoric acid, washed thoroughly with water, dried, washed in alcohol, and dried again. The blocks of ivory were simply given the ordinary soaking in water to make them as much like the tooth structure as possible,

wiped dry with a cloth, the surfaces washed with alcohol, and dried with the air-blast. Because the etching with hydrofluoric acid had caused so little adhesion of the cement to the glass, I had doubts as to whether it would cause adhesion to a flat surface of porcelain. Roughening the surface of a deep porcelain filling would obviously act as small undercuts and cause the cement to retain the filling, but there was much doubt in my mind concerning the power of etching to cause adhesion of cement to a flat surface.

Six preliminary tests were made with the ¼-inch square of etched porcelain cemented to the ivory blocks under 8 pounds pressure for one minute and then released, two with Harvard coarse, two with Harvard pulverized, and two with the Ames inlay. Next morning the four Harvard cement films tore away from the ivory at about a 67-ounce pull, remaining firmly adherent to the porcelain, while the Ames cement dropped off the ivory with a pull too small to be measured. This seemed to give a maximum adhesion of the H arvard cement to a plain ivory ¼-inch square of a little over 4 pounds.

It was then seen that if the adhesion of cement to etched porcelain was to be measured, some way would have to be devised to make the cement stick more securely to the ivory. This was done by making deep undercuts in the ivory. These undercuts were filled with the cement and the pieces of etched porcelain pressed upon the overflowing cement, kept under 8 pounds pressure for one minute, and then released and treated in the usual way. Next morning, when these pieces of porcelain were pulled off, the two etched squares of porcelain broke loose from the Harvard coarse cement at 16 pounds and 22 pounds each. The Ames broke at 6 pounds and 3 pounds each. In each test there was clean tearing away of the porcelain from the cement. The next tests were identical with those just described, only the old cement in the undercuts was simply filed smooth, and the cleansed porcelain squares cemented under 8 pounds pressure for one minute to the old cement and the adjacent ivory that had simply been washed with alcohol and dried. Further tests proved that the fresh cement would stick to

the old cement more firmly than it would stick to the etched porcelain.

The following tables and their general averages tell their own story. Tests, as previously stated, were made under 8 pounds pressure for one minute. These same tests were duplicated with the 8 pounds pressure maintained until setting was complete. Harvard coarse, under 8 pounds pressure for one minute, released, paraffined, set in water over night and pulled off in the morning, showed that etched porcelain broke away from undercut ivory at 16, 22, 16, 12, 11, 13, 15, 20, 16, 11, 12, 14, 14, 14, 16, 12, 15, 10 pounds. General average 13 pounds, 2 ounces, to $\frac{1}{4}$-inch square surface. When the pressure was maintained until setting occurred, the breaking strain was found to give the following figures: 6, 16, 13, 10, 12, 18, 13, 4, 10, 8, 9 pounds, giving a general average of 11 pounds, 10 ounces. This shows that with Harvard coarse maintaining the pressure did not increase the adhesion. These same tests were made with Harvard pulverized. Where the 8 pound pressure was maintained for one minute only, we have the following figures: 12, 12, 13, 8, 9, 13, 18, 21 pounds, giving a general average of 13 pounds, 4 ounces. Where pressure was maintained until setting was complete, the following were the figures: 16, 12, 25, 24, 28, 17, 14, 13, giving a general average of 17 pounds, 7 ounces. With the Ames cement, where 8 pounds pressure was maintained for one minute, the following figures were obtained: 6, 3, 13, 13, 0, 17, 11, 3 pounds, giving a general average of 8 pounds, 4 ounces. Where the pressure was maintained until setting occurred the Ames cement gave the following figures: 6, 8, 6, 7, 14, 16, 12, 11, 11, 13, 12, 9, 8, 10, 7, 8, 7 pounds, giving a general average of 9 pounds, 9 ounces.

Summary.—General average for 8 pounds pressure for one minute only; ivory undercut, porcelain etched:

Harvard coarse, 13 lbs., 2 oz.
Harvard pulverized, 13 lbs., 4 oz.
Ames inlay, 8 lbs., 4 oz.
Average, 11 pounds, 8 ounces.

General average for 8 pounds pressure until setting is complete:

Harvard coarse, 11 lbs., 10 oz.
Harvard pulverized, 17 lbs., 7 oz.
Ames inlay, 9 lbs., 9 oz.
Average, 12 pounds, 14 ounces.

The fact that the Harvard coarse cement does not show greater stress-bearing power when the pressure was maintained until complete setting is possibly explained by the fact that with coarse powder sometimes a particle might be so large as to prevent general pressure. Certainly with the Harvard cement it is clear that the finer the powder, the stronger the adhesion and the finer and truer the film. These tests also show that new cement will stick firmly to old cement; that a thin film does not seem to be as strong as a thick film; that ground porcelain and roughened ivory have little adhesive power, while etched porcelain has great power of adhesion to cement. This seems at first an anomaly, since etching with hydrofluoric acid has no such power on glass, but a little thought will solve the difficulty. Glass is a homogeneous substance, and etches smoothly and homogeneously, but porcelain, being composed of quartz, feldspar, and flux, etches unevenly in pits and undercuts.

The fact that the old cement will adhere to the new cement more firmly than the new cement will adhere to the etched porcelain, makes it feasible to fill undercut cavities with cement until setting occurs, and then to cut out of the cement a simple cavity with clean enamel edges. Thus may a difficult filling be converted into a simple filling.

Numerous tests were made with the flat porcelain on which zinc oxid had been fused to see if such porcelain had greater adhesion to the cement than etched porcelain. When zinc oxid was given just the right fusion, $\frac{1}{4}$-inch square of porcelain with Harvard pulverized stood as high as 30 pounds pressure, but later fusions of zinc oxid to the porcelain, made with equal care, gave sometimes no adhesion at all, or only 2 or 3 pounds. Therefore, although at first it was thought that the principle of partially fusing zinc oxid to the porcelain filling for purposes of

adhesion might prove of value, its unreliability finally forced the conclusion that etching with hydrofluoric acid is more feasible and trustworthy.

In order to verify the accuracy of these data it was decided to insert a series of ten porcelain fillings of standard size in a piece of ivory, and after they had been cemented into position under various conditions with the Ames and Harvard pulverized cements respectively, to push the fillings out of the cavities with a plunger inserted from below and attached to a scale.

Fig. 273.—Machine for measuring force required to push out a cemented porcelain inlay: *A*, ivory block with inlay cemented into position as shown; *B*, ivory ring fitted with a plunger that is inserted into a hole beneath each filling. Pressure is applied and measured by spring balance.

The cavities were made and reamed to standard size—0.3125 inch in diameter at the top, 0.125-inch deep, and 0.187-inch in diameter at the bottom. Holes about 0.031-inch in diameter were carefully bored in the bottom of each cavity through the piece of ivory to make easy passage for the plunger. The porcelain fillings were made with the platinum matrices in the usual way, the holes in the bottom of the cavities being temporarily stopped with wooden plugs. The plunger was cemented into the inside of a celluloid ring attached to a spring balance. Thus, by inserting the plunger in the holes under the fillings, pressure against the fillings was obtained by a pull on the spring (Fig. 273). When the pressure tests were to be made the block of ivory containing the cemented inlays was placed upright in a vise. The ring containing the plunger was slipped over it and the plunger inserted in the hole beneath the filling to be tested; then the spring was steadily pulled and pressure made until

the filling was loosened. The exact pressure reached at the giving way of the fillings was measured by the needle marking a carbon film on the scale, as described previously in the other adhesion tests.

The first two tests were to obtain the adhesion of perfectly smooth ivory walls to smooth, glazed, closely fitting porcelain. These fillings were cemented into place with pulverized Harvard cement at thumb pressure for one minute and then allowed to set, care being taken to remove all superfluous cement in the holes under the fillings, so that there would be free movement and apposition of the plunger against the porcelain. The fillings were then paraffined and placed in water over night. In the morning not one of these fillings stood a pressure of 8 ounces, and most of them came out with very much less. The fillings and cavities were then carefully cleansed of cement with dilute sulphuric acid and washed in alcohol and dried. The fillings were then recemented into position with the Ames inlay cement with a similar result—no filling stood more than 8 ounces, and most came out with a pressure of 2 or 3 ounces. These tests proved that plain ivory surfaces in apposition with glazed porcelain with a thin film of cement did not make a satisfactory union.

The next two tests were made under exactly similar conditions, except that the fillings were etched with hydrofluoric acid for thirty seconds. The walls of the cavities were smooth and without undercuts. The following results were obtained: Harvard pulverized, 37, 28, 47, 96, 20, 30, 34, 66, 88 ounces respectively, average 3 pounds, 3 ounces. Ames inlay, 40, 40, 32, 57, 90, 64, 39, 33, 38, 37 ounces respectively, average, 2 pounds, 12 ounces.

In the next tests the cavities instead of being smooth, with sloping walls, were deeply undercut: Harvard pulverized, $8\frac{1}{2}$, 9, 11, $15\frac{3}{4}$, 7, 6, 13, 14 and 18 pounds respectively, average 11 pounds, 6 ounces. Ames inlay, 14, 10, $13\frac{1}{2}$, $7\frac{1}{2}$ 7, 17, 11, 13, and $17\frac{1}{2}$ pounds respectively, average, 12 pounds, 10 ounces.

In the final tests the fillings were deeply undercut, resembling small collar buttons, without the slightest attempt being made to fit the cavity except at the margin, and the cavities were more deeply undercut, to make as great a cement mass around the

filling as possible. The results were as follows: Harvard pulverized, 32, 25, 24, 23, 20, 18, 28, 30, and 27 pounds respectively, average, 25 pounds, 7 ounces. Ames inlay, 18, 20, 17½, 10½, 17½, 33, 26, and 21 pounds respectively, average, 19 pounds.

Conclusions on Cement as an Inlay Bond.—These tests and tables indicate: (1) Glazed or ground porcelain and smooth ivory have but little power of adhesion for cement. (2) A thin film of cement is not so strong a bond as a thick mass. (3) The edges of a filling should be in as close apposition as possible, but wherever feasible the cement that holds the filling in the cavity should have body and act as a dowel. (4) Etching of porcelain with hydrofluoric acid is a valuable means of obtaining adhesion where the filling is too shallow for undercuts; but undercuts are to be preferred where they can be obtained, and there is good reason to believe that the best results are gained by both undercutting and etching the filling. (5) Fusion of zinc oxid to the porcelain inlay for adhesion purposes is unreliable. (6) Fineness of grit in a cement is more responsible for a fine cement line than pressure. (7) Reduction of the cement grit adds to the strength and power of adhesion. This is a law that applies to all cements if they are not thereby made to set too quickly. (8) With Harvard pulverized cement, maintaining the pressure during the complete process of setting slightly diminishes the cement line and increases the adhesion 24 per cent. (9) Where the inlay and cavity are sufficiently deep to allow the final expansion characteristic of the Harvard cement during crystallization to be exerted on the filling and cavity, maintaining the pressure is only valuable for the sake of apposition, as more pressure is probably obtained by the crystallization of the cement than can be exerted by external pressure.

These tests were made ten years ago, and since that time Dr. Ames has done magnificent work in evolving cements that are of incalculable value to the profession, and that have now largely replaced the earlier cements.

Solubility of Cement Line.—When I started to put in inlays I believed that an accurately fitting inlay with a so-called perfect edge and microscopic line of phosphate of zinc cement would

preserve its integrity in any mouth where there was proper hygienic care. I believed that the mucin of the saliva acting as a plug in a fine line would stop osmosis of any neighboring solvent and prevent continued deterioration, and that a coarse line would not have any such preservative effect, as here the mucin would be constantly changed and washed away. I also held that the more perfectly the inlay fitted the cavity and the less room there was for cement, the greater would be the security against dislodgment. Since that time I have noticed that in some mouths a certain percentage of inlays with perfect adaptation will show undoubted signs of discoloration and disintegration at their margins, and that the little shallow labial cavities that allow only a thin cement film for retention are the inlays most likely to drop out.

I decided, therefore, to undertake experiments to determine the relative solubility of thick and thin lines of cement. In preparation for these tests pieces of plain glass were etched with hydrofluoric acid, then creamy cement was firmly pressed between them and allowed to set for fifteen minutes. These pieces of glass and cement were then placed in water and at the end of twenty-four hours the glasses fell apart, leaving free cement films. What was desired was glass so etched that it would permanently adhere to the cement, in order that the action of solvent fluids could be studied on a cement film protected as at the margins of an inlay. Finally, after many experiments it was found that the fumes of hydrofluoric acid would occasionally form an undercut etch on glass sufficient to cause wet cement to permanently adhere to the glass, and in such cases the glass was carefully preserved and cut up into ¼-inch squares. Agate etched with liquid hydrofluoric acid was found to give permanent hold to wet cement. Therefore, the ¼-inch squares of glass were cemented to the etched agate and the edges carefully cleaned. Thus the corroding action of the various solvents on the cement films could be noted, being discernible through the glass with the dark agate as a background.

Having solved the problem of making cement stick to glass when immersed in an aqueous solution, the next question was

to decide on the fluids with which to carry on the tests. Free films of cement and tooth enamel were placed in various solvents such as acetic, valeric, butyric, citric, and lactic acids and c. p. ammonium hydrate (28 per cent.), all of which reagents have been detected in a diluted form in the human saliva. Their effect was primarily tried on natural tooth enamel, because it was considered that fair tests on the solvency of protected cement could only be made with fluids that would not dissolve tooth enamel more rapidly than cement, nor, in fact, dissolve enamel at all, as only such solvents would approximate the conditions found around inlays in the mouth. Natural tooth enamel and thin unprotected pieces of Harvard cement were tested simultaneously in solutions of various strengths of the solvents just mentioned. For instance, a tooth and cement film when placed in 28 per cent. aqua ammonia showed rapid dissolution of the cement with practically no harm to the enamel. When, however, the ammonia was reduced to 2 or 1 per cent. it rendered the cement film only slightly defective in the course of some days, and when a film of cement protected on each side by glass and agate was placed in such an aqueous solution of ammonia, the power of osmosis seemed incapable of either weakening or dissolving the cement during a period of months. Therefore, ammonia in any strength that could possibly exist in the mouth was found to be harmless to the cement line. When, however, lactic, valeric, butyric, and acetic acids were tested, a conclusion was not so readily reached. Anhydrous c. p. lactic, valeric, and butyric acids had, as would be expected, no discernible effect on tooth enamel, and little, if any, on cement, except in the case of valeric acid, which made the free cement film defective. But when these acids, as well as acetic and citric acids, were tested in aqueous solutions of from 1 to 0.1 per cent., or even 0.05 per cent., the action on tooth enamel was terrific. For instance, 1 per cent. aqueous solutions of lactic, acetic, or citric acids would roughen enamel in three minutes; in ten minutes a chalky surface appeared, and in twenty-four hours all enamel was practically eaten away. Valeric and butyric acids in 1 per cent. solutions did not seem to materially hurt

enamel during twenty-four hours, but at the end of three months they had made deep holes in the dentin—a clean scoop with no leathery dentin remaining. These acids, it is true, affected cement films in various degrees, but by comparison with their action on enamel the cement was practically permanent, and it was apparent that if we could find a cement that would last in the mouth as much longer than the enamel, as the film of cement outlasted the enamel in these aqueous solutions, we would have a cement that would in ordinary circumstances last many times a man's lifetime. But these results were preposterous, since ordinarily in the mouth the enamel remained while the cement dissolved. Proceeding with the experiments with aqueous solutions and taking lactic acid as a basis, teeth were tested in 1 : 20,000 lactic acid and water and it was found in three days that the enamel was softened to the cut of a lancet, giving a cheesy, colloid shaving. And yet it must be understood that this amount of acid, powerful as it was, was so minute as to be hardly perceptible to any chemical tests. At last, after carrying on innumerable tests with solutions at blood temperature, it was found that the source of error lay in the use of aqueous solutions, and that saliva solutions should be used if results approximating those found in the mouth were to be obtained.

For instance, a solution 1 : 500 of lactic acid and one saliva tested, although it turned blue litmus-paper brilliantly red and had a sharp acid taste, preserved enamel for days or even weeks unharmed. At other times this same person's saliva in lactic acid solutions of from 1 : 800 to 1 : 1000 would not be able to protect enamel from decalcification for any length of time. It was also discovered that in saliva solutions the cement was less protected from acid disintegration than was the enamel; it was noted, too, that some salivas were much better protectives for cement than others. For instance, a 1 : 1000 solution of lactic acid and one saliva would steadily dissolve cement, while it would not dissolve enamel. A 1 : 500 lactic acid solution with another saliva would protect both enamel and cement; and as an interesting fact it might be mentioned that cement lasts extremely well in the mouth from which this latter saliva was

derived. So the problem of what fluids to use in these cement-dissolving tests was solved by using saliva solutions of lactic acid. Lactic acid was chosen not because acetic, citric, butyric, and valeric acids might not also attack the cement in the mouth, but because its action in these tests more nearly represented the kind of decalcification which the author had noted in the mouth. Valeric and butyric acids slightly attack cement, while acetic and citric acids attack it quite vigorously, and it is quite possible that these acids are responsible for the dark cement line that sometimes appears around inlays in the front teeth, these acids being the ones most commonly found in fruit into which the front teeth are apt to be sunk.

The procedure for testing the solubility of the cement films was as follows: The above-mentioned ¼-inch squares of etched glass and etched agate were carefully cleansed and dried. Then finely ground Harvard cement was mixed to a creamy consistence and squeezed between the pieces of glass and agate for about a minute, and the cement allowed to set for fifteen minutes in the air. At the end of that time the edges of the glass were cleansed of cement with a lancet and the protected films placed in a bottle containing the solutions in which they were to be tested. They were then placed in a culture oven where blood temperature was maintained, and observations taken at suitable intervals. The first action of any dissolution of the cement was noticed when the remnants of the cement film that adhered to the face of the etched agate after the glass had been cemented in place dissolved, leaving the surface of the agate absolutely clean. Any disintegration of the cement film between the glass and the agate was clearly visible through the glass. These tests made with saliva solutions were accompanied by control tests of aqueous solutions of the same strength.

The first test to be reported was made with a protected film in 1 : 1000 solution of lactic acid and saliva, and 1 : 1000 aqueous solution of lactic acid. To the saliva were always added a few drops of ether or chloroform to prevent fermentation. In one day there was a perceptible line of disintegration about the glass-covered film in the aqueous solution, which steadily in-

creased. The film in the saliva solution did not show disintegration until the third day. At the end of ten days the film in the aqueous solution had dissolved 0.035 inch all around the edge. It took the saliva solution thirty days to accomplish the same result, this test showing clearly that the saliva reduced the speed of the cement disintegration to one-third of what occurred in an aqueous solution. Moreover, lactic acid in this solution made a clean dissolution without causing the cement to become rotten and soft. For final observation the glasses were taken off the films, which were tightly adherent to the agate, and the cement beneath was examined. In each instance what remained was found to be hard and apparently unchanged to the cut of the knife. The films when measured were about 0.0015 inch in thickness, the extra thickness being due to the uneven etching of the glass and agate. Hereafter the ordinary thin film of cement will be considered to be about 0.0015 inch in thickness.

Tests were next made on cement films in solutions of saliva and lactic acid that would not cut enamel. Cement films, as above described, of about 0.0015 inch in thickness were placed in a saliva and lactic acid solution, 1 : 1000, and also in a 1 : 1000 aqueous solution of lactic acid. It might be interesting to note here that lactic acid and saliva, 1 : 1000 solution, has a decided acid taste. At the end of thirty days the film in the aqueous solution of 1 : 1000 lactic acid had dissolved to a distance of 0.0625 inch from the edge of the glass, while the film in the 1 : 1000 lactic acid and saliva solution showed no signs of dissolution at all. Covered films placed in 1 : 500 lactic acid and one person's saliva in thirty days showed slight but perceptible dissolution around the edge of the glass; while a similar test made with another saliva in a corresponding lactic acid solution showed no perceptible deterioration in the cement film. In fact, one of the cement films kept in a 1 : 500 lactic acid solution with the latter saliva for six months just began to show signs of deterioration at the glass edge at the end of that time. Thus, some salivas unquestionably are better able by far to preserve cement and enamel against acids of a certain strength than are others. Numerous tests with acid solutions made from the salivas of

various patients conclusively proved that salivas vary in their relative power of restraining acid decalcification both of tooth structure and cement.

Another test of interest was the following: A covered cement film had been left in a 1 : 1000 solution of lactic acid and saliva for two months in the summer, during which time the solution had fermented. The specimen was taken out and found to be apparently unharmed. The specimen was replaced in a fresh solution of lactic acid and saliva, 1 : 300. At the end of twenty-four hours the author was astonished to find the cement film dissolved 0.0625 inch from the edge of the glass. A further immersion in the 1 : 300 lactic acid and saliva solution made only the slow progress one would naturally expect. At the end of ten days the glass was pried off, and the remaining cement was very adherent and apparently unsoftened, as shown by the knife. This test seemed to show that during the summer, although the edge of the cement film had been rendered defective, the 1 : 1000 lactic acid and saliva could not entirely dissolve it, and that a solution of 1 : 300 lactic acid and saliva later readily dissolved the rotten portion in a few hours, while the gradual dissolution of the normal cement went on with the ordinary speed.

Tests were then made to show the relative speed with which a thick and a thin cement film would dissolve in a given solution. Covered films 0.0015 inch thick, as above described, were used for thin films and a thickness of about 0.004 inch for the thick films. The thick films were made by squeezing the cement between agate and glass held apart with several layers of platinum foil, 0.001 inch in thickness, folded together. The thin film, 0.0015 inch, dissolved twice as fast as the thick film. In fact, during a period of two months the thin film had dissolved 0.0625 inch from the edge, while the 0.004-inch film in the same time had dissolved 0.003 inch. The thick and thin films tried in 1 : 1000 lactic acid and saliva had not dissolved at all during the same time, not even a little film of exposed cement that had not been cleaned from the etched agate. This experiment, many times repeated, was a stumbling-block, as up to that time a very fine joint had been thought to be a protection against

disintegration of the cement around the edge of an inlay. Moss fiber gold was cemented with great pressure between the glass and agate slabs, and the edges trimmed clean and flush with a sharp lancet. This was done to get the finest possible adaptation and the thinnest film of cement, so that just as an inlay would be kept from its position by the largest grain of cement, so with the moss fiber gold the apposition might be said to be represented by the smallest cement layer possible, since the large grains of powder would be bedded in soft gold. But these tests only reaffirmed the fact that a thin layer of cement will dissolve more rapidly than a thick layer under similar conditions. And yet this phenomenon, when we come to think it over, is only natural—the less cement there is to be dissolved by a solvent, the more rapidly it will disappear.

And so, after all that has been said and done, the fine phosphate of zinc cement film of an inlay is no protection against disintegration; it only looks better, especially if the margins of the inlay tend to discolor. This explains why the old Bing gold inlay lasted so well, consisting as it did of a thin gold shell and a pin cemented into a cavity, both shell and cavity having been filled with cement. Badly fitting though the edges were, the author has seen Bing inlays last for years and does not remember ever having been able to pull one of them out.

These tests lead to the following conclusions: (1) In saliva solutions of acid, phosphate of zinc cement ordinarily dissolves more rapidly than enamel. (2) Some salivas are able to protect the cement from disintegration, and some salivas are not. (3) Where disintegration occurs as the only factor, a fine line of cement will dissolve more rapidly than a coarse line of cement; but where friction and jambing of the carbohydrates into a coarse line occurs by mastication, undoubtedly the cement in a coarse line will disappear more rapidly than in a fine line.

While the foregoing experiments concerning solubility have not the value that they had at the time they were made, due to the fortunate development of the insoluble silicious cements, they are still valuable for what they have shown concerning the protective action of saliva.

CHAPTER XII

STUDY OF THE ROOTS AND GUMS BY MEANS OF THE X-RAY

THE x-ray is most valuable as an aid to diagnosis, but, as previously stated, it is not always to be relied upon except as an important link in the chain of evidence on which a scientific diagnosis should be based.

Many dentists are using x-ray machines and are taking the skiagraphs themselves. This procedure is not ordinarily judicious, as an x-ray plate to be of any value must be taken by an expert of large experience. Moreover, medicine has had numerous x-ray martyrs who died or were hopelessly crippled in finding out the danger of using x-ray machines without adequate protection or instruction; and dentists in using such machines are not only subjecting themselves to a great risk, but they are also subjecting their patients to the danger of burns and permanent deformity. This risk no doubt will only be eliminated when a number of abnormally sensitive patients have been subjected to a too long exposure by the inexperienced practitioner, who does not take the now recognized precautionary measures either for himself or his patients. I do not wish to have it inferred that I object in principle to the dentist taking x-ray plates. I only mean to state that a dentist who takes x-ray plates should specialize in this field, obtaining his knowledge under the supervision of an expert rather than at the painful expense of his patients. In the early history of anesthesia deaths from nitrous oxid gas did not occur by the wholesale because at the approach of complete anesthetization the blue skin of asphyxiation warned the untrained dentist that death was hovering near, and so he was scared into a state of proper caution; but with the x-ray machine no such warning is given, and a burn may be administered by the inexperienced operator that may mar and injure the unsuspecting patient for life.

Whenever it is possible to have a preliminary study made of the mouth by a series of x-ray plates or films, it should be done, as by this means much valuable information concerning the condition of the roots, alveoli, and peridental membrane will unquestionably be obtained; but we should not forget that the x-ray plates cannot tell the whole story, as some of the following cuts will show, and conditions are pictured concerning pulp canals that appear sometimes worse and sometimes better than they really are. Complete knowledge can only come through the use of three valuable factors: the quality of the x-ray plate; scientific interpretation of the plate by the practitioner; and a careful control of the plate findings by judicious comparison with the clinical symptoms of the patient.

When the diagnosis has been arrived at by means of the factors just mentioned, every area of infection should be treated accordingly. But in interpreting the data it should not be forgotten that heretofore in dentistry there has been an overzealous tendency to magnify the necessity for the complete filling of root canals to the exact tips. This has been injudiciously claimed to be the only means by which infection at the tip could be absolutely avoided. This complete filling of the root canals, as has been shown in Chapter VI, is ordinarily quite impossible, since there are frequently three or even five separate openings at the ends of a root; and then the mere filling of a root canal to the tip cannot insure against the progressive increase of infection that may have already started in the bone outside of the tooth before the root canal was filled. The dentist's greatest care after a preliminary study of the x-ray plate should be first to see that the tooth is thoroughly sterilized before it is filled; not the root canal, but the entire internal structure of the tooth; second, to fill it as thoroughly as he reasonably can, with the aid of all the scientific data obtained; and third, to have more x-ray plates taken six months or a year later. At that time if it is found that the tips have healed aseptically, even though the root canals may not be filled to the tip, they can be safely left to take care of themselves. But if areas of infection still appear, even about the apices of perfectly filled roots, there

should be surgical interference; the tip should be amputated, the infected bone curetted, and the wound packed with antiseptic gauze until complete healing is obtained.

Interpretation of Plates.—The following *x*-ray plates are presented with a full appreciation that they have not, in places, the perfect outline and clear delineation found in many other books on this subject. Many of the pathologic conditions shown by the plates are only obscurely demonstrated, but as this is the difficulty that ordinarily confronts us in the interpretation of *x*-ray plates, the plates are presented without being touched up.

Case No. 1 (Fig. 274). Here is a case of an active woman, aged forty-five, who in her youth had tuberculosis, but recovered from it. A careful examination of the mouth disclosed no pockets of infection and only an abnormal red line around the necks of the teeth, and yet the *x*-ray plates seem to indicate that the lime salts are being absorbed from the bones around the teeth in a way characteristic of the beginning of infection. Blood taken from the infected gums shows the presence of Streptococcus viridans, hemolytic streptococcus, and Bacillus influenzæ. The patient also had osteophytes in the knee and in the lumbar vertebræ, and certainly needed treatment, systemic rather than local, since the local condition could be readily controlled by mouth scrubbing and local cleansing, as described in Chapter II. Vaccine treatment was given, the vaccine being made from the germs found in the blood from the gums.

Case No. 2 (Fig. 275). The next case is of a woman aged forty-three. The films show an apparently normal condition of the tips and the alveolar process, with the single exception of the anterior root of the left lower second molar, which has a spot of infection and indicates that the root canals will have to be opened and treated with Buckley's mixture; and if this is not successful the root must be excised from the rest of the tooth and extracted. However, the shadow upon the tip of the anterior root is accentuated by the fact that it lies in the line of the inferior dental canal, and therefore may not be so seriously involved as it appears to be. And yet a careful study of the bony structures

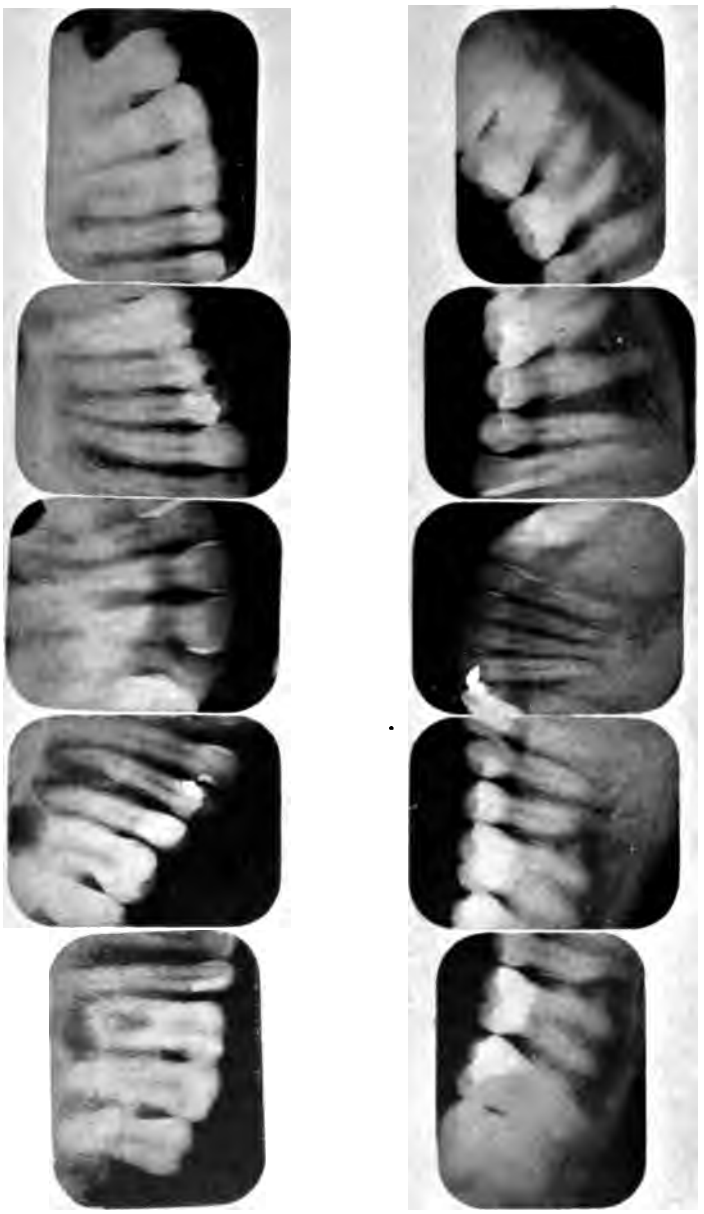

Fig. 274.—Case 1. Woman, aged forty-five. Absorption of lime salts around the various teeth indicates a systemic lesion of some depressing nature. There is no evidence of any particularly active forces of infection.

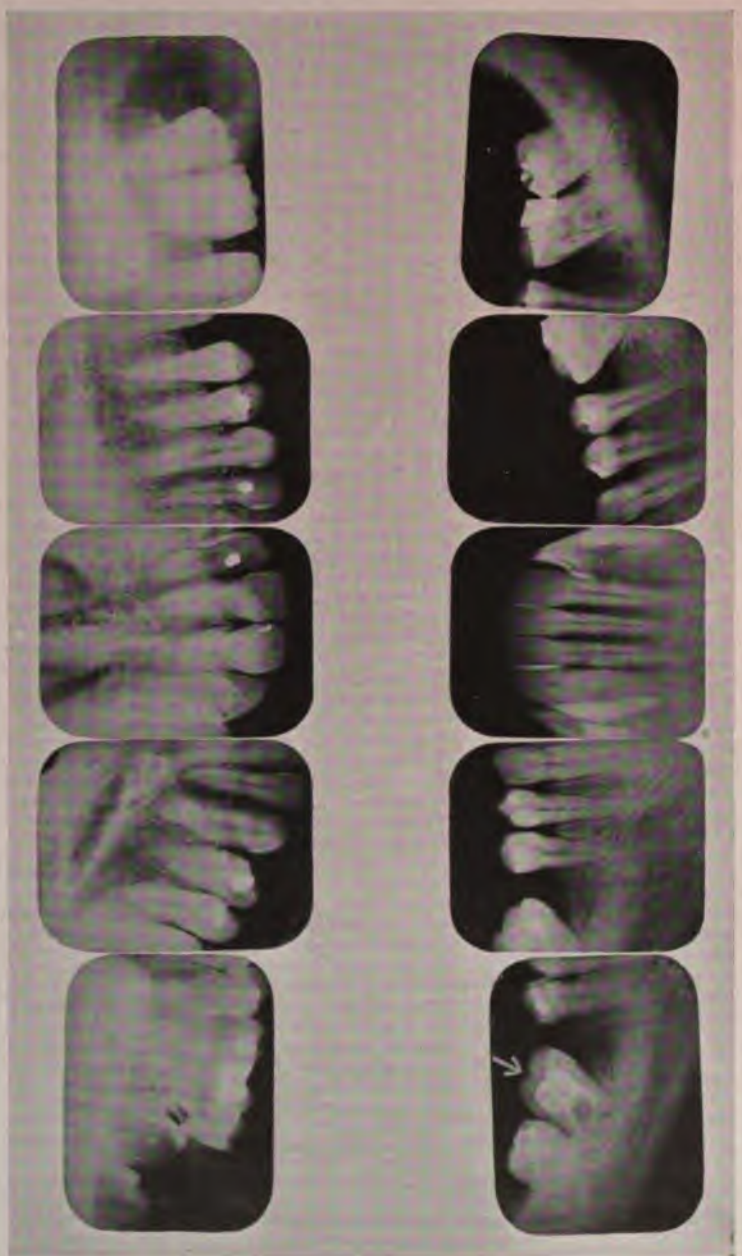

Fig. 275.—Case 2. Woman suffering from nervous breakdown. The only focus seems to be the anterior root of left second molar, as shown by the arrow.

generally indicates a lack of lime salts, and consequently a lowered bacterial resistance of the bone. Such a diagnosis, however, can only be made when the dentist knows just how long the exposures were made and what tubes were used.

Case No. 3 (Figs. 276–278). This case is of a woman forty-two years of age who had recovered from tuberculosis of the lungs some ten years previously. Her right knee was badly infected and enlarged to twice its size, with marked crepitus, and yet the *x*-ray of the knee-joint, because the infection is still

Fig. 276.—Case 3. Right knee, the bone of which seems normal and yet the knee was swollen to twice its normal size. It lost its swelling and shortly returned to normal condition when three badly fitting shell crowns were removed from the two right lower molars and second bicuspid.

confined to the soft tissues, reveals nothing. The radiograph study of the mouth and also of the knee are shown. The *x*-ray shows nothing abnormal at the tips of any of the roots except in the case of the right lower first molar. The rarefied bone in the upper jaw was not associated with pockets; the gum was inflamed, but not to the point of breaking down. The patient, however, had not used floss-silk nor kept the back teeth free from bacterial deposits. Just before the *x*-ray plate was made three gold shell crowns that were collectors of foul infection were removed from the first and second right lower molars

Fig. 277.—Case 3. Woman, aged forty-two. Recovered from tuberculosis of lungs ten years before coming under care of author. Tips of right lower first molar seem the principal, if not the only source, of root infection.

and the lower right second bicuspid. The knee began at once to improve. What the author wishes to emphasize in this case is that serious external mouth infection, not discoverable by the *x*-ray, obviously caused the serious knee inflammation, because when the external infection was removed, the swelling and inflammation in the knee began rapidly to subside. An attempt was made to extract the lower right first molar, and as a preliminary precaution the tooth was cut into two parts so that the roots would be separate from each other, but it was impossible to get them all out at the first operation without causing excessive laceration. The roots broke, leaving about one-third of each root in the jaw bone. These root tips were allowed to remain, and were easily removed in the course of a month, when the inflammation had loosened them and caused them to float near the surface. The excessive tightness is interesting in the light of



Fig. 278.—Case 3. Shape of tips of roots due to the exostosis.

the area of infection at the tips. The tips, when extracted, were found to be of the shape shown in Fig. 278, which accounted for the difficulty encountered in the extraction. It will be observed that the *x*-ray plates gave some warning of the exostosis, but did not picture it completely. The enlargement was in the line of the *x*-rays and the consequent difficulty of extraction was not made fully obvious. The removal of the tips at the time of extraction would have been attended with great danger of fracturing the jaw, and yet four weeks later the inflammatory process made it possible to easily remove the broken ends with the simple pry of an elevator. Had it not been for the systemic condition I am convinced that judicious canal treatment would have been justified and would probably have saved the tooth. The point of interest about the case is that the areas of decalcification in the alveolus, being general, were not such as to imperil the teeth or body if judicious cleansing had been maintained;

and the only tooth that did show a darkened area of inflammation was so firmly lodged that it would not come out whole. The mere removal of three infecting overhanging crowns caused the acute symptoms in the knee to abate, and an autogenous vaccine was used to raise the germicidal power of the blood, thereby effecting a complete cure.

Case No. 4 (Fig. 279). The next case is that of a married woman aged thirty-six, whose three elder sisters had died in infancy from hereditary syphilis. Plates are shown of the infected upper and lower incisors as indicating the condition when the patient was first examined. Mark the darkened areas

Fig. 279.—Case 4. Necrotic areas at tips of roots *A* and *B* due probably to hereditary syphilis. Pulp alive in upper central incisor. Note white line of bone extending from apical foramen of the upper central incisor to healthy bone beyond.

of infection above the superior left central and lateral incisors, and below the lower left lateral incisor. The patient suffered excessively from a burning sensation in the tip of the tongue that was reflected into the sublingual glands and the glands of the neck. The lower left incisor, marked *A*, was extracted, the bone drilled away, and the opening packed with sterilized gauze. All of the black bone that was not removed by the primary operation was removed with an excavator during the subsequent daily dressings. Occasional applications of aromatic sulphuric acid were made which expedited the separation of the unhealthy from the healthy tissues. At the end of a week the entire wound was clean, pink, and covered with healthy granu-

lations. It was then allowed to fill up and the wound closed satisfactorily. Immediately after the cutting away of the dead bone the tongue symptoms were greatly ameliorated. During the period of inflammation they again appeared, but finally, when the wound entirely healed, they were greatly improved, although not entirely eliminated. In the meanwhile the patient was having a course of mercurial treatment on account of the hereditary syphilitic history. It was next determined to extirpate the infected area over the left upper superior central and lateral incisors, marked *B*. It will be interesting to know that the pulp in the central incisor was alive, and the course of the blood-vessels can be seen in the plate, running through the thin septum of bone that had not yet become broken down. Novocain and suprarenin were injected and the bone drill inserted through the gum into the infected region, which was found to be black, cavernous, and far-spreading in various small tentacle-like projections. To have cut all the black bone out at the first operation would have meant the loss of the teeth as far as the first bicuspid on one side and the lateral incisor on the other. Therefore, the tips of the lateral and central incisors were amputated, the pulp canals cleansed and filled with Buckley's mixture of tricresol and formalin, and the wound packed with sterilized gauze. The next day the dressing was removed and aromatic sulphuric acid was applied for three minutes on a pellet of cotton, and the wound repacked with gauze. This was repeated on the fourth day, and by this time the wound was spread open, the tips of the amputated tips were exposed, and the black remnants of bone so softened and loosened that they could be easily picked out with a spoon excavator, leaving only living, sensitive bone and the bottom of the wound clean. No such wound should be allowed to heal up while there is any insensitive bone left at the bottom. To do so spells failure and probably a recurrence of decay. When this had been accomplished the upper left central and lateral incisors were again opened and the canals resterilized. Gutta-percha cones were then forced into the canals until they projected through the foramina, the gutta-percha trimmed off at the tips with a hot instrument, and the teeth

then completely and permanently filled with cement. After this the wound was kept open with gauze until the granulations filled up to a point where the wound was more shallow than broad, care being taken to see that the bottom was entirely covered by sound, healthy tissue. The use of a flap of gum and the blod-clot method, in this instance, would have been hopelessly inefficient. Bone operations about the teeth roots can hardly ever be based on the supposition of asepsis. Such a wound practically always contains infected material, and drainage is always necessary. This wound healed satisfactorily and the incisors were saved.

Case No. 5 (Fig. 280). This case[1] shows another illustration of a darkened area of bone at the tip of a root, indicating evident infection, although the root contained a living pulp. The tooth referred to is the left upper bicuspid supporting the bridge. This case is that of a woman suffering from secondary anemia. Four years previously she had a hemoglobin of 30 per cent. and had become so weakened that she had lost the use of her legs. She was put to bed for six months, and under medical treatment her hemoglobin rose to 75 per cent. Since that time she had been steadily relapsing, and when the author first saw her the hemoglobin of the blood had again dropped to 30 per cent., poikilocytes, macrocytes, and microcytes being present. An autogenous vaccine was prepared from material taken from a pus pocket in the gum around the tooth *C*. The left upper second bicuspid, marked *A*, was extracted, the anterior buccal root of the right upper second molar, *B*, cut loose and extracted, and the lower right second molar, *C*, that showed an area of infection at the tips, also extracted. In three days the poikilocytes disappeared, the red cells had increased from 3,616,000 to 3,960,000, and the patient felt distinctly stronger. The vaccine treatment was started, the mouth put in hygienic condition, and the teeth restored so as to perform their proper functions for accurate mastication by means of cleansable fillings, crowns, and bridges. The great point of interest in the case lies in the fact that the mere removal of the three roots could have

[1] See page 101.

Fig. 280.—Case 5. Woman, aged forty-three. Hemoglobin, 30 per cent. Root *A* contained living pulp. Note darkened area at tip. *A*, *B*, and *C* were extracted and in two days hemoglobin rose to 37 per cent.

in three days caused a rise of seven points in the hemoglobin and a disappearance of poikilocytes. At the end of two months the patient returned to her home in the West and the vaccine treatment was continued there. In four months after the treatment was inaugurated the hemoglobin rose to 67 per cent. After that she steadily improved until her health was completely restored.

Case No. 6. The next case is that of a man aged forty-five, who had been suffering from severe neuralgic pains in the right side of his head. The *x*-ray plate (Fig. 281) shows a superior second bicuspid that had an area of inflammatory infiltration with a projecting point of gutta-percha at the tip. The bone

Fig. 281.—Case 6. Second bicuspid tip showing projecting root canal filling and infected bone area. The tip was amputated and a neuralgia of two years' standing at once disappeared.

over the tip was anesthetized with novocain, the area drilled out, and the tip of the root smoothed. This simple operation alone caused his headaches to disappear permanently. This is especially interesting as it shows how slight an irritation at the tip may cause a reflex action. And is is especially of interest to consider, if so minor a spot of irritation happened to cause so marked a neuralgia, might it not have easily caused other types of systemic disorders that were nevertheless serious, although their presence may not have been made manifest by the symptoms of pain? This man also had a case of general mouth infection that necessitated treatment for over three years before it could be controlled. Figure 282 shows his right shoulder

containing marked osteophytes; and Fig. 283 is a picture of the same shoulder taken three years later, showing the absorp-

Fig. 283.—Case 6. Observe same humerus three years later, during which time vaccine has been given and mouth hygiene inaugurated. The osteophytes have disappeared.

Fig. 282.—Case 6. Osteophytes at the head of humerus.

tion of the osteophytes so that the joint is practically normal. When this patient first came under observation he had contem-

plated an operation for having the osteophytes removed from the head of the humerus. The author advised against it and told him to await the effect of the mouth treatment and the vaccine. At that time he was having acute pains in his shoulder and could hardly move the arm. The treatment produced such beneficial results that the patient decided against an operation. At the end of three years the osteophytes had disappeared, there was no longer any pain, and his arm had regained its normal power of movement.

Fig. 284.—Case 7. Gutta-percha projecting beyond tip of bicuspid necessitating root excision.

Case No. 7. This case shows a well-marked blind abscess at the tip of a root, shown by the dark area of inflammation at the tip of the lower second bicuspid (Fig. 284). The gutta-percha root canal filling protrudes through the apical foramen into the abscessed region. The value of the *x*-ray plate is here made apparent, for this condition would not have been allowed to exist had an *x*-ray plate been made at the time the root was filled. Moreover, the gutta-percha would not have protruded

if the gutta-percha point with the oil of eucalyptus had been used as described in Chapter VI. There were only two possible remedies—one was to extract the tooth; the other was to anesthetize the gum and bone over the tip and amputate the lower portion of the root, leaving the end smooth and even. This latter was done and the tooth has been giving good service ever since. It will be noticed that the infected region lies close to the mental foramen. When the operation of excision was performed the patient was warned that he might lose sensibility of the lower lip on that side. Immediately after the operation it was found that the sensibility was unimpaired; but later the inflammation

Fig. 285.—Case 8. Posterior root excised of molar marked *A*. Crowned according to Fig. 286. Molar marked *B* hopelessly infected. Extracted and replaced by removable bridge.

spread and the nerve trunk at the mental foramen became involved, and he lost sensibility in the right side of the lower lip for three months. Since that time, however, the normal sensibility has returned and the mouth is comfortable.

Case No. 8. This patient, a man aged forty-five, had two lower molars that were infected at the tips—the right lower second molar, marked *A*, and the first lower left molar, *B*. The two cases would have appeared equally difficult to manage without the aid of the *x*-ray plate. The left lower first molar roots, *B*, were extracted, being hopelessly infected, and the molar replaced by a removable bridge. The anterior root alone of the right second molar was extracted, leaving, as the plate shows, a

healthy posterior root, *A*, on which a satisfactory crown was constructed which entirely filled the space, and which has been doing good service for over a year and a half (Fig. 286). It was constructed as follows: The crown of the anterior adjacent tooth was composed almost entirely of amalgam. Let *A* represent the anterior tooth; *B* the remaining root of the tooth from which the anterior root has been extracted. A platinum band was fitted to the projecting portion of *B*. Porcelain was built up on the band to form a crown, *C*, with a notch on the side. Then crown, *A*, was enlarged by the amalgam addition, *D*, so that it fitted into the adjacent porcelain crown. To make the portion *D*, the crown, *A*, was well undercut and soft amalgam added and dried of its mercury by sponge gold. When this was polished the floss-silk could be passed between the amalgam and the porcelain crown for the daily cleansing, and yet the ledge of amalgam formed a perfect support for the porcelain during the stress of mastication. In this way the tooth function was as hygienically maintained as it was prior to the excision of the anterior root.

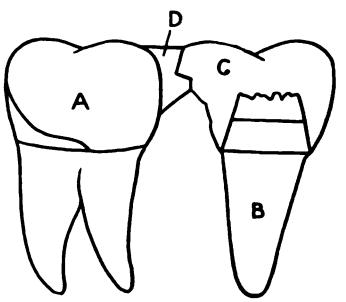

Fig. 286.—Case 8. *A*, first molar with large amalgam filling in crown; *B*, posterior root of second molar, anterior root having been excised; *C*, porcelain crown with platinum shell for retention; *D*, amalgam addition to molar *A* to make a side support for crown *C*.

Case No. 9 (Fig. 287). The *x*-ray plate shows that the roots of the right lower second molar were so badly infected that the tooth had to be extracted. The tips were found to be necrotic. The tooth was replaced by a removable bridge. The two upper left bicuspids were opened on account of the darkened area at the root tips, and were given a course of sterilization, filled with gutta-percha cones that were pushed into position through eucalyptus oil until the tips wedged. The cones were then packed thoroughly into the canal with warm instruments. The first

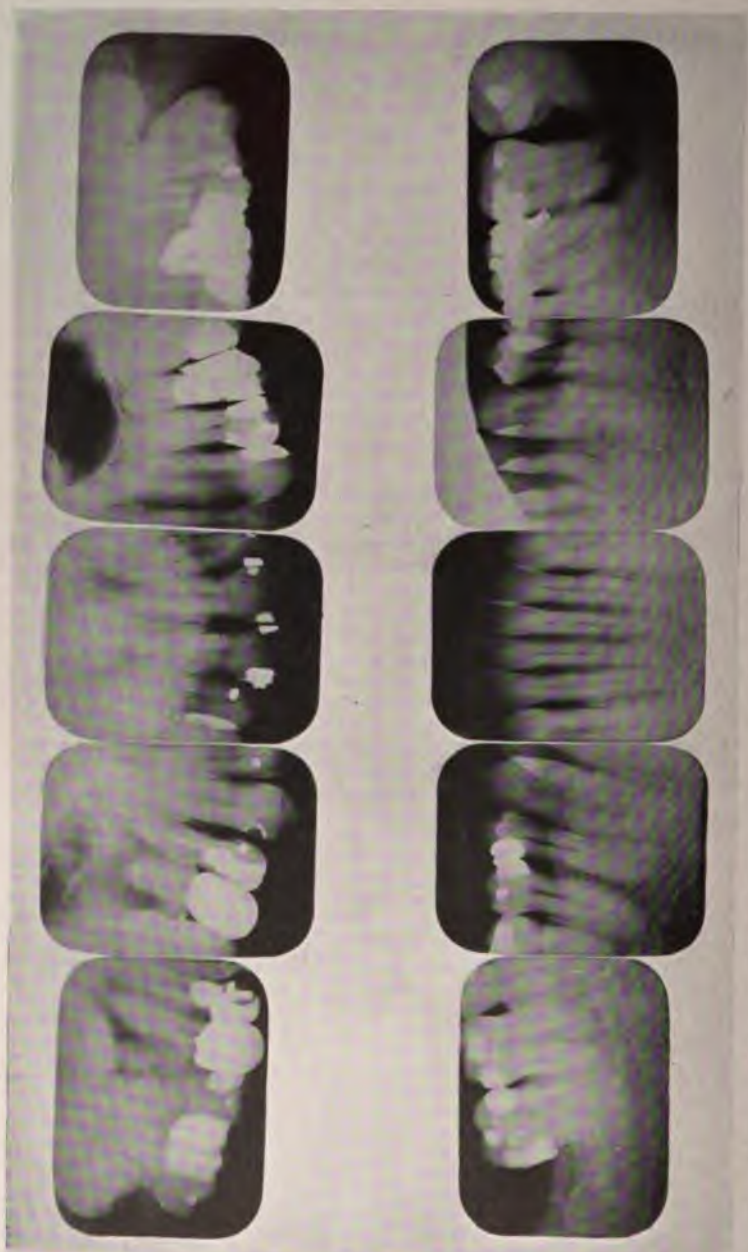

Fig. 287.—Case 9. Right lower second molar so much infected it had to be extracted. Pulps dead in upper left bicuspids, canals filled, and tips treated with violet ray to stimulate bone to healthy action.

wedging of the cones at the tips prevented any possibility of the liquid gutta-percha being driven through the apical foramen. The gums over the darkened areas of the tips were stimulated once a week for several weeks by applications of the violet ray, which greatly aided the restoration of the vitality of the infected areas. The tip of the right upper second bicuspid also was treated in a similar manner, although excision of the root tip through the alveolus might have been advisable. The impacted upper wisdom teeth were left undisturbed, as they were apparently causing no reflex disturbance. If, however, neuralgia should develop or even any serious, unexplainable systemic symptoms arise, however far removed, the extraction of such teeth should always be held under consideration. The bones around the lower incisors unquestionably have lost a portion of their lime salts, but a relief from the irritation of the general mouth infection will allow the forces of recuperation in the bones to assert themselves.

Case No. 10 (Fig. 288). In the next case we have a similar appearance, but more marked, of the loss of the lime salts in the tips of the left upper central incisor and left upper lateral incisor, in which teeth the pulps are alive and without the *x*-ray would have been considered normal. The bone around the tips has started to degenerate, and unless it can be stimulated to health, will unquestionably in time require the bone drill. Applications of the violet ray or electrolysis in this region will be valuable; but if these are not successful in controlling the infection the canals will have to be opened, cleaned out, and filled, in spite of the fact that the pulps in both teeth are alive and show no physical signs of disturbance. The right upper lateral incisor and left upper second bicuspid gave no evident clinical signs of disorder, and yet the pulps are dead and the tips seem unquestionably absorbed. The bony areas require that the root tips should be excised and that the adjacent area of lowered vitality in the bone should be stimulated to healthy growth. These tips are only less diseased than the left lower second bicuspid and left lower molar, the roots of which have become hopelessly absorbed. These teeth will have to be extracted and replaced by a removable bridge. The bridge replacing the lost

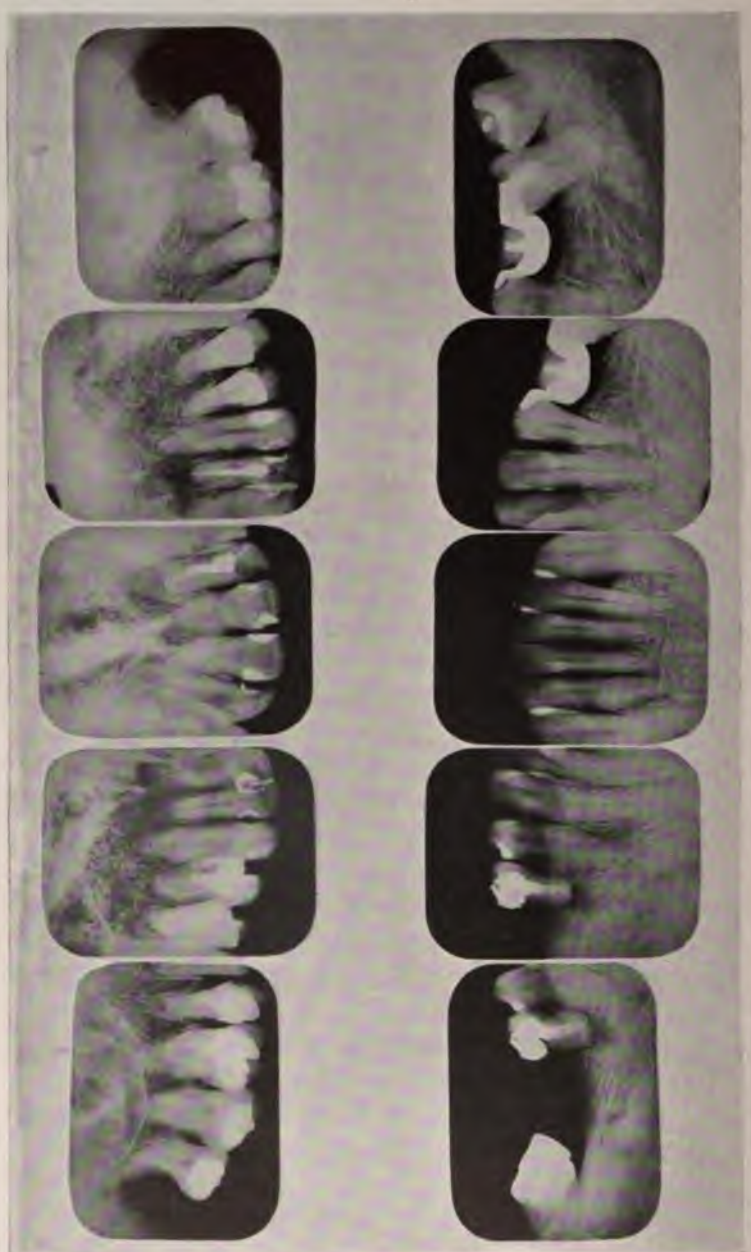

Fig. 288.—Case 10. Necrotic area of bone around upper right lateral incisor tip due to dead pulp and unsuccessful canal filling. Pulps alive in upper left central and lateral incisors in spite of area of bone decalcification. Tips stimulated with electrolysis to encourage repair of bone. Left lower second bicuspid and left lower third molar extracted on account of root absorption.

right lower second bicuspid has been in position many years, and is doing excellent service. It is composed of an inlay in the molar to which a gold cap for the retention of a cemented tooth and spud have been attached. It will be noted that the tips of the second molar are in good condition. The lack of calcic salts in the alveoli around the lower incisors indicates an infection, and the need of careful cleansing with floss-silk and brush and a raising of the bacterial resistance with bacterial vaccine.

Case No. 11. The next case is that of a man aged forty-eight years, who has been under the author's care twenty-five years. The work looks "pretty poor," but a great deal of it was early practice work, and since the patient was perfectly comfortable there never seemed to be any necessity for changing it. But finally, although his mouth was still comfortable, he began to show symptoms of toxemia, the cause of which his physician was unable to locate. The radiograph, however, was most enlightening. All of the bicuspids except the right lower first bicuspid were extracted. They are marked *A*, *B*, *C*, *D*, *E*, *F*, *G* (Fig. 289). All had tips denuded of peridental membrane, and cementum dissolved and roughened with sharp points. The first lower right bicuspid, marked *H*, that has a much deeper shadow than the others, had a live pulp which was removed, with every chance that the tip would recover under the healing effects of asepsis and electrolysis. In Fig. 290 *B* represents the extracted root of the left upper first bicuspid, and *G* the extracted root of the lower second bicuspid. These are typical of the way all the extracted bicuspids appeared. The anterior palatal root of the left upper second molar was excised and removed by means of the elevator. The right upper first molar was opened and a cotton dressing of years standing was disclosed. Oh, Shade of Flagg! The dark areas over the upper central incisors should also be noted, merely to show how much the anterior palatal foramen may resemble an area of infection.

Case No. 12. The plate (Fig. 291) shows three right lower molars. The first molar, marked *A*, is sufficiently sound to be treated externally with the violet ray and the dry cell battery.

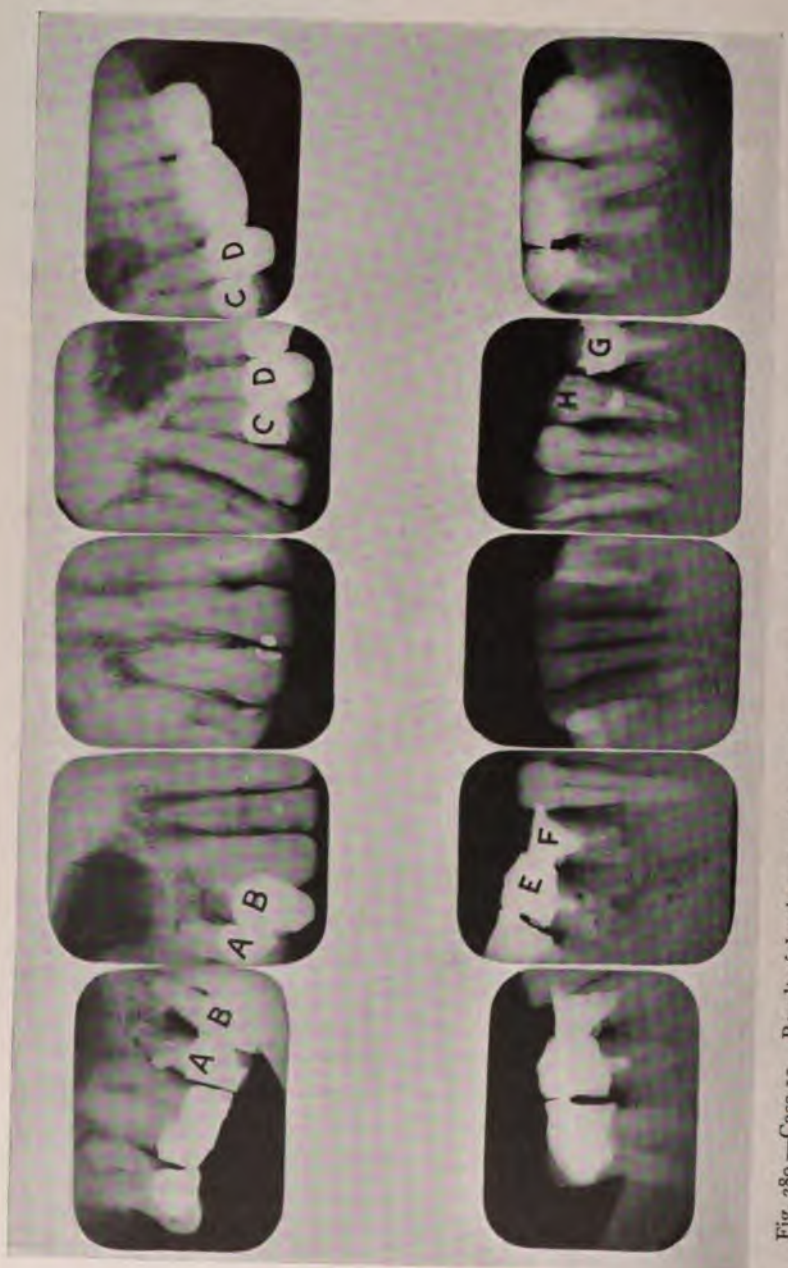

Fig. 289.—Case 11. Result of dentistry taught twenty years ago—cotton root canal fillings, etc., ultimately necessitating extraction of *A, B, C, D, E, F,* and *G.* Tips absorbed and roughened, like extracted roots *B* and *G* shown below. Pulp in *H* alive, removed, and canal and tip treated.

Molar *C* also seems sound, but the anterior root of molar *B* is badly infected, as is shown by the plate. This tooth was excessively sensitive to the slightest touch. The anterior root of molar *B* was extracted, leaving the posterior root in position. Figure 292 is a photograph of the extracted root with the abscess

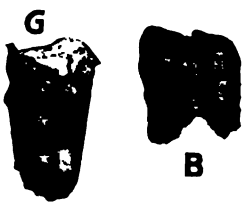

Fig. 290.—Case 11.

sac attached. Being a recently acute condition, the sac was still in position, but later on chronic suppuration would have set in, and the membranous condition would have been replaced by a necrotic cavity of bone.

Fig. 291.—Case 12. Anterior root of *B* excised through the crown and extracted.

Fig. 292.—Case 12. Extracted anterior root of molar *B*.

Case No. 13. Figure 293 pictures an apparently similar inflammatory condition of the right lower second molar root. And yet the photograph of the extracted root (Fig. 294) shows that the conditions were more advanced. The abscess sac had been completely absorbed and the cementum at the tip has been denuded of its membranous covering. In this case there was no pain or discomfort and the root was extracted on the evidence of the *x*-ray plate.

Case No. 14 (Fig. 295). The next case is that of a woman, aged twenty-nine years, very poorly nourished. The film of the lower incisors is missing, but the other illustrations will show that a marked destruction of bone and peridental membrane has occurred. Her teeth were loosening and spreading in all directions, but a study of the plates indicated that the membranes and bone around the root tips were still in a healthy condition. The teeth were drawn into place by twisted silk. Mouth hygiene was inaugurated, with applications of ammonium bifluorid comp., and last, but not least, an autogenous vaccine was given once a week. The patient made a rapid recovery, gained weight, her teeth became firm, and the gums healthy.

Fig. 293.—Case 13. First molar infected at tip. Note photograph of extracted tooth.

Fig. 294.—Case 13. Photograph of extracted first molar. Tip denuded of peridental membrane and roughened.

Case No. 15 (Fig. 296). This case is that of an unmarried woman of thirty-seven years. It will be noted that the left lower first molar and second bicuspid and the first lower right bicuspid, marked respectively, *A*, *B*, *C*, have areas of infection at the tips. Observe the photographs of the extracted teeth (Fig. 297). Their pulp canals had been filled years previously with cotton, a fact which the *x*-ray did not, of course, discover. The molar root tips, *A*, were found to be necrotic, without enlargement of the cementum. The second bicuspid, *B*, was denuded of its peridental membrane at the tip, but otherwise, with the exception of a slight exostosis, was normal. The right lower first bicuspid, *C*, had an exostosis half-way down the root to the tip with a small peridental sac at the end. The exostosis at the tip of the left

Fig. 295.—Case 14. Young married woman with excessive malnutrition. Tips of teeth fairly normal. Pulps normal, but teeth loose and spreading in all directions. Made good recovery without bone surgery.

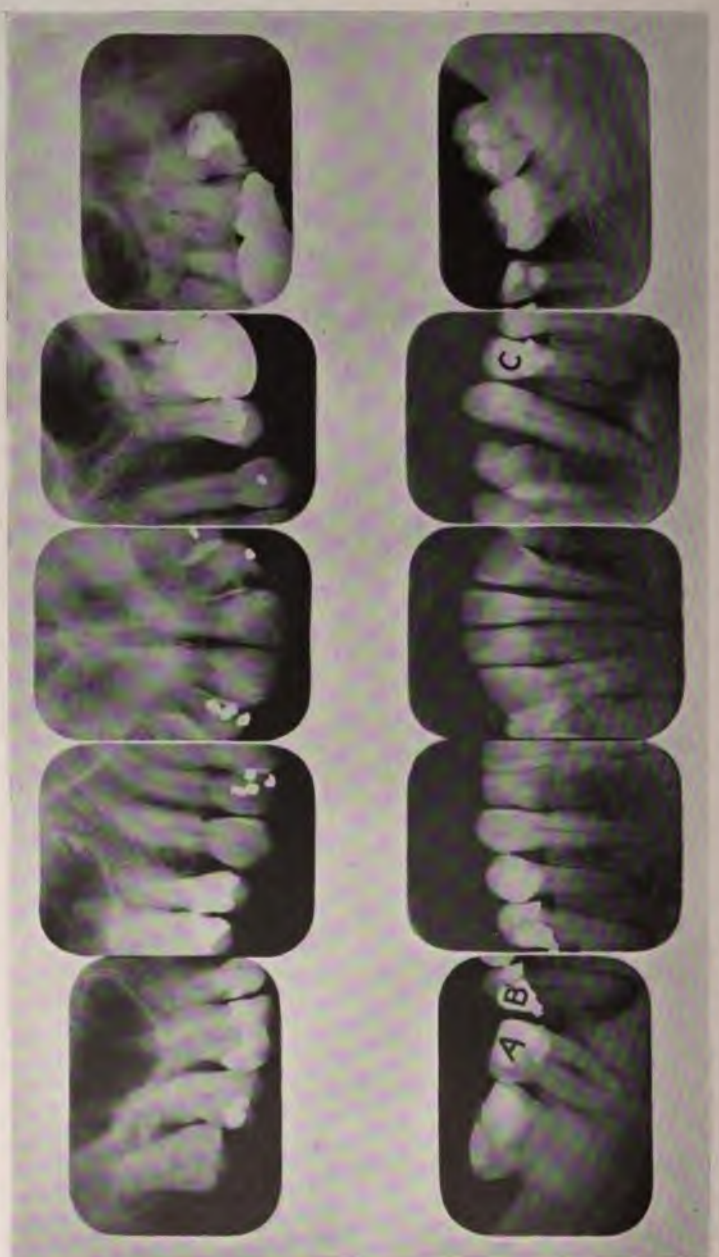

Fig. 296.—Case 15. *A*, *B*, and *C* contained dead pulps. Note photographs of extracted teeth. Note exostosis at lower first bicuspid tip.

lower first bicuspid is of interest, and the fact that extraction was unnecessary was a source of congratulation. The upper right first molar had to be extracted owing to absorption of the buccal roots and infection at the tip of the lingual root.

Case No. 16 (Fig. 298). Note especially the right upper lateral incisor containing a living pulp and the first buccal root of the left upper first molar where the pulp had died. The former was extracted and the buccal root of the latter was excised at the bifurcation. It will be noted that the other bony processes, although absorbed, are unusually retentive of their lime salts, indicating good bacterial resistance of the patient, which proved to be the case. The patient is a vigorous, active man of fifty, and responded with great readiness to the vaccine treatment after the two infecting roots were extracted and careful mouth

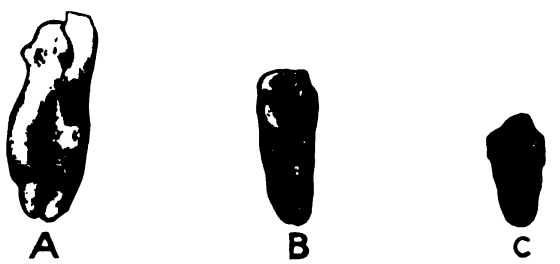

Fig. 297.—Case 15. Extracted teeth. Excessive exostosis in *B* and *C*.

hygiene instituted. In spite of the loss of bone around the lower incisors, they are perfectly firm under mastication, owing to the healthy condition of the peridental membrane that yet remains. If, however, this should get infected, the teeth will loosen and be lost almost immediately.

Case No. 17 (Fig. 299). The next plate is of a young unmarried woman of twenty-seven. The patient showed marked mouth infection, especially of the soft tissues, associated with great general weakness and loss of vitality, a slight overtendency to fat, but previously athletic and active. The two lower sixth year molars are infected at the root tips. These were extracted and showed inflammatory membranous sacs at the tips, smaller, but nevertheless of the same type as the root shown in Fig. 292, Case No. 12. But the point of particular interest in this case

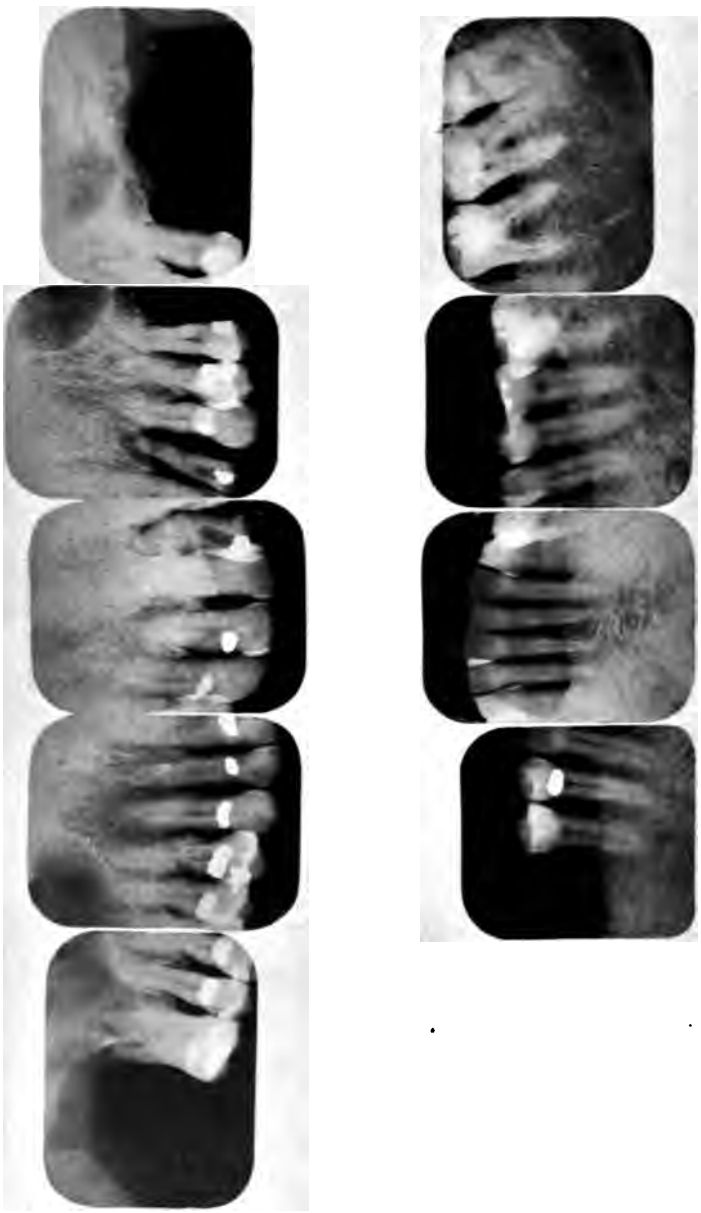

Fig. 298.—Case 16. Pulp alive in right upper lateral incisor. Absorption of bone about lower incisors had not caused the teeth to loosen.

Fig. 299.—Case 17. Note lower right and left first molars which had to be extracted and replaced by removable bridges. Upper bicuspids were treated without root amputation.

lies in the general absence of lime salts in the bones, especially around the upper bicuspids and the lower incisors. This indicates a tendency for the breaking down of all the tissues. The mouth was placed in a satisfactory hygienic condition and autogenous vaccine given with beneficial results.

Case No. 18 (Fig. 300). This skiagraph portrays the lower central incisors showing an area of decalcification at the tip of the right central incisor. This was supposed to be a spot of infection, and marked as such by a prominent *x*-ray man. But the tooth gave normal responses to heat, and a close study of the plate will show that the lacunæ are present in the decalcified area, showing that the bone is not broken down. A later study of the mouth is shown by the larger plate (Fig. 301).

Fig. 300.—Case 18. Supposed spot of bone infection marked by arrow.

The right first lower bicuspid contained a cotton root canal dressing that had been slowly spreading infection in the root under the crown ever since the crown was inserted—a period of some five or six years. The right upper first bicuspid that was extracted shows a slight infection of the buccal root, the lingual root appearing normal. There is little doubt that the root might have been saved if general symptoms of rheumatism had not demanded its removal. The right lower second molar had a membranous sac on the tip with a certain amount of absorption of the alveolar process around it. The dark line in between the roots of the left lower molar did not indicate a breaking away of the peridental membrane from the tooth or any real pocket of infection. It only shows a loss of lime salts in the bony tissues.

Fig. 301.—Case 18. Woman, aged forty-six. Right lower molar cut loose from right second bicuspid and extracted. Left lower molar extracted. Cotton dressing of years' standing found in right lower first bicuspid.

Case No. 19 (Fig. 302). The lower second bicuspid shows so apparent a spot of infection at the tip that the local dentist on the evidence of the *x*-ray plate had drilled into the tooth only to find the pulp alive and apparently normal. He was consequently at a loss to understand the defined darkened area and sent the plate to me for examination. To my mind it was plainly a case of *enlarged mental foramen*. In the *x*-ray plate the mental foramen is apt to appear as a dark spot and great care must be

Fig. 302.—Case 19. Darkened area at tip of second bicuspid is not a chronic abscess—it is the mental foramen.

taken in differentiating it from a spot of infection by clinical evidence.

Case No. 20 (Fig. 303). This case is that of a man of forty-three years, of fairly good health, but who for the last four or five years has suffered from progressive nervousness with a tendency to get tired easily. His mouth had been looked after by a happy-go-lucky dentist who still uses cotton as a pulp canal filling. The patient for years has used a tooth-brush without cleansing his teeth. This case will be discussed in detail, as the study of the extracted roots serve as a key for solving the condition of the whole mouth. The first two teeth that will be noted are the lower second molar, *A*, and the upper first molar, *B*. The anterior root of the right lower molar was excised by cutting the crown in half, according to the dotted line, from the bifurcation of the roots up to the grinding surface. In Fig. 304 *A* represents the excised half of the tooth which was

Fig. 303.—Case 20. Man, aged forty-three. Root marked *A* excised along dotted line, posterior root healthy, anterior absorbed and necrotic. Note very faint shadow at tip of root *A*. Upper root *B* was excised and the tip found almost normal. Note dark shadow at tip, and photographs of extracted roots *A* and *B*. Right upper lateral incisor had a necrotic pulp and the gum around it was red and inflamed, a condition which does not show in the skiagraph.

found to have two distinct roots with absorbed and necrotic tips. Note the type of shadow around this tip in the plate (Fig. 303). It is extremely faint and the lines of demarcation in the adjacent bone are most indistinct. When we examine the bone next to the normal root, which bone was found to be living, containing canaliculi, the shadow is far greater than in the spot where bony absorption was complete and the peridental membrane completely destroyed. The bone at the bifurcation of the two roots was alive and healthy to the cut of the bur, merely showing a slight loss of density, indicating that it had begun to lose its lime salts, while the same bone immediately adjacent, that has much less of a shadow, had lost all of its lime salts and organic structure. The infected area clinically

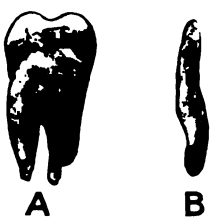

Fig. 304.—Case 20. Root marked *A*, remarkable as it is, is a bifurcated anterior root of lower second molar. As can be seen, the root tips were necrotic and absorbed. Tip of the extracted root, *B*, was almost, if not quite, normal, and yet it appeared badly diseased in the plate.

was nevertheless much in evidence, and yet, when studied by the *x*-ray, the line between the healthy and unhealthy bone became so indistinct as to require the closest observation for its detection. The upper first molar has a decided area of calcic absorption around the anterior buccal root. The buccal root was found to be filled with cotton, while the palatal root contained gutta-percha. It was decided to excise the anterior buccal root from the rest of the tooth, both for the sake of saving the tooth and in order that it might be possible to examine the extracted root and adjacent bone for the purpose of determining the meaning of the changed bone around the roots of the upper bicuspids, canines, and incisors. It will be seen from the *x*-ray plates that the bones around the tips of the bicuspids and canines are appar-

ently more lacking in lime salts than the bone around the tip of the buccal root that was extracted. There is no absorption of the tip, and a macroscopic examination of the root showed that it contained a moderately healthy tip with an adherent peridental membrane that was perhaps slightly thickened (Fig. 303, *B*). This fact convinced the author that antiseptic treatment and filling combined with external electrolysis might have been amply able to restore health to the complete tooth. The tooth, *A*, was then restored to normal occlusion by carving the crown and building it up to proper contour with porcelain. The pulp in the right upper lateral incisor proved to be dead and putrescent, although the bone at the tip did not seem especially unhealthy. Strangely enough, it gave a sharp thrill under the application of the cautery, which at first seemed to indicate that the pulp was alive, but later tests and further analysis of the plate convinced me that the pulp, even if it were alive, should be removed. I then found on opening this tooth that the pain from the cautery application had arisen from the expansion of the heated gas sealed within the canal, making pressure upon a sensitive, inflamed apical foramen. The right upper central incisor also had a putrescent pulp, but it gave no response to the application of heat. All of the upper teeth, where there were bony changes similar to those that had occurred in the upper extracted molar root, were filled, with the full conviction that antiseptic dressings and fillings, combined with external electrolysis and mouth hygiene, would be amply able to restore the tissues to health. The case is kept under observation, and if a later *x*-ray plate shows that complete healing has not taken place amputation of the tips of the roots will be necessary.

Case No. 21 (Fig. 305). This represents the mouth of a woman of seventy, well preserved and active. The plates show a general loss of bony substance that at her age might be called normal, although in a person of thirty it would be considered a sign of some depressing systemic infection. All of the teeth are firm with the exception of the left lower second molar, marked *A*. This was quite loose, and a careful examination will show the

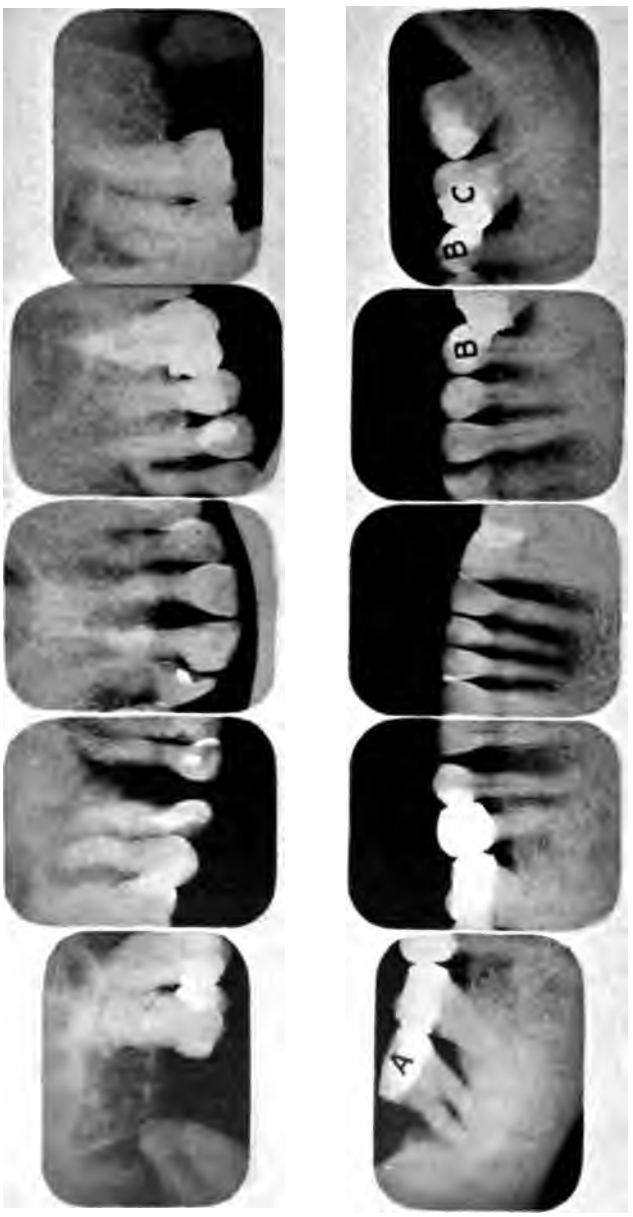

Fig. 305.—Case 21. Old lady of seventy. Molar marked *A* extracted and tip found roughened and denuded. Right lower second bicuspid contained a living pulp.

faint area of tissue change that was noticeable in the previous case around the lower molar root that had to be extracted. This tooth was extracted and the tips were found rough and denuded of peridental membrane. The right lower second bicuspid, marked *B*, claimed attention, owing to the changed bony area at the tip. This area, it will be noted, was much more obvious than the area around the molar marked *A*. There is exostosis of the root, and the lacunæ of the bone in the affected area are very indistinct. The tooth was opened, disclosing a living infected pulp, which was removed with the expectation that the tooth and adjacent bony tissue would recover their

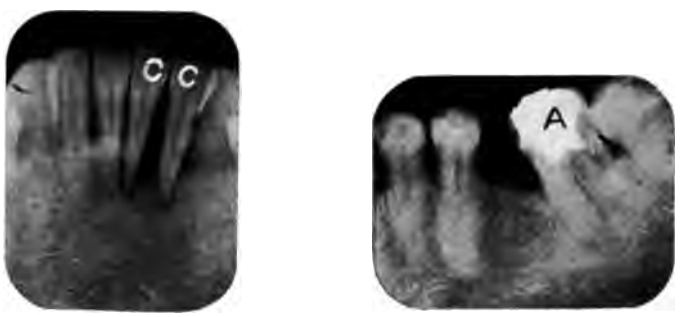

Fig. 306.—Healthy man, thirty-five years of age. Anterior root of *A* excised through the bifurcation of the root and extracted. It had an abscess sac only slightly smaller than that of Case 12.

normal tone. This was especially probable from the fact that the adjacent molar, marked *C*, the root canals of which had been filled, had healed so satisfactorily about the canal tips. General mouth hygiene and routine dentistry caused the rest of the mouth to heal satisfactorily.

Case No. 22 (Fig. 306). This next case is that of a healthy man of thirty-five years whose right lower molar, marked *A*, is defective in the anterior root. This was excised in the usual way from the bifurcation of the root up through the crown to the grinding surface. The membrane was thickened on the end of the extracted root to form a sac somewhat less than that in Case 12. The posterior root was treated and filled, and later

formed an excellent abutment for a bridge. It will be noticed that the two lower incisors, marked *C*, have a much more readily observable area of infection around their tips. Both of these teeth were loose, although the teeth had no external signs of decay and both pulps were alive. The pulps in both were removed, the canals sterilized and filled, and in about six months the teeth tightened and the mouth made a satisfactory recovery.

Case No. 23 (Fig. 307). In this case the two upper central incisors had received a blow during a game of football. The right upper central incisor became sensitive and began to discolor. The pulp was removed and the canals filled. With the

Fig. 307.—Case 23. Right upper central incisor given a blow during a game of football, that caused the pulp to die.

history and clinical facts at our disposal, the slight discoloration at the tips, as shown by the plate, are significant, but it must not be forgotten that such discolorations are apt to occur in this region owing to the presence of the anterior palatal foramen, and therefore it is probable that the *x*-ray by itself would not give reliable evidence. A soft tube will differentiate soft tissues more than a hard tube, but, after all, we must remember that the *x*-ray of the mouth usually only gives information concerning the hard tissues, while the inflammation may be largely confined to the soft tissues. Still a careful examination of the right upper central will show an interesting area of darkening.

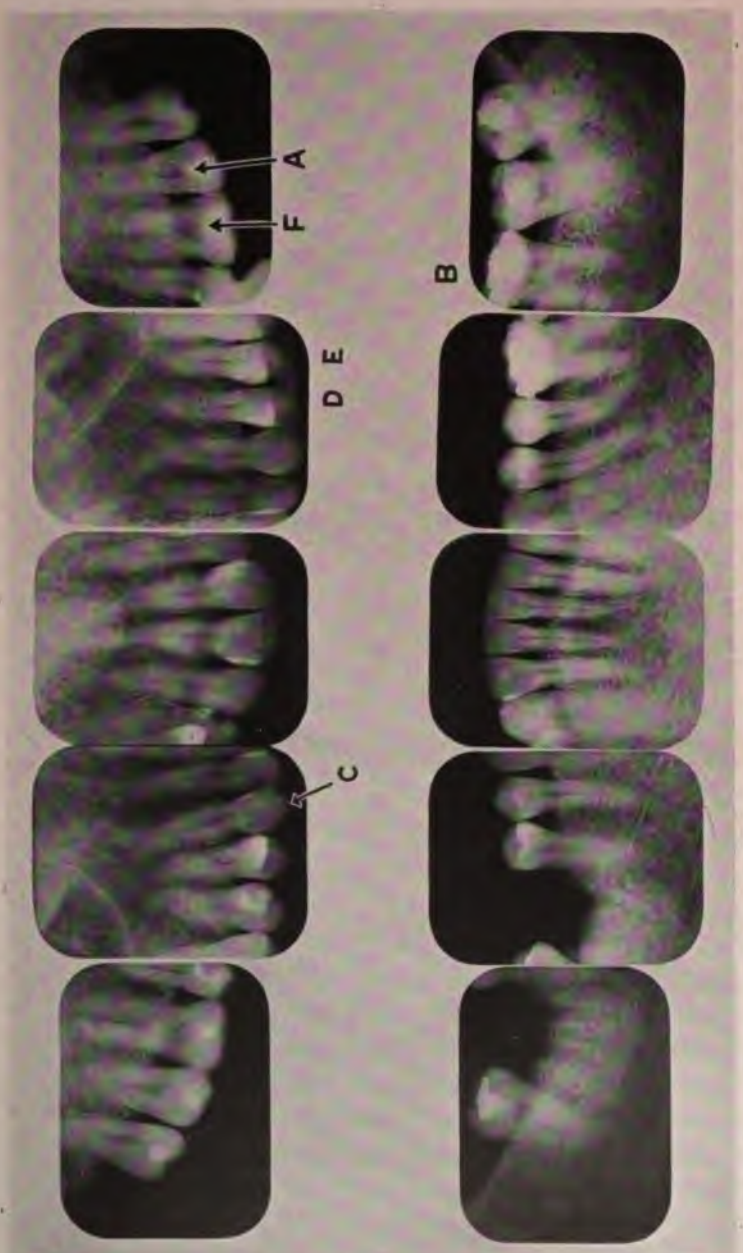

Fig. 308.—Case 24. Severe case of neuralgia, earache, and muscular rheumatism relieved when pulps in *A*, *B*, *C*, *D*, *E*, and *F* were treated. Note the pulp stone in position in right upper second molar.

Case No. 24 (Fig. 308) is that of the mouth of a young woman of twenty-five years who has suffered intense neuralgic pains for over two years. These pains were in both jaws, the left ear, and radiated down the left shoulder and arm to the first and second fingers. So desperate was her condition and so obstinate her case that it seemed a true case of central trifacial neuralgia. Her doctor, a diagnostician of wide reputation, was unable to find anything wrong with her organs or general system. Her ears were pronounced normal by a specialist, and finally she was sent to have an *x*-ray taken of her mouth and teeth, and the

Fig. 309.- Case 24. *A* represents pulp stone, actual size, taken from molar marked *A*.

author was requested to examine her mouth for possible sources of trouble. A cursory examination of the *x*-ray plates seemed to show an unusually healthy condition of membranes and bone around the tips of all the teeth. But a more careful examination of the right upper second molar, *A*, shows the presence of a large pulp stone within the pulp chamber. This tooth was excessively sensitive to the application of heat. The pulp was anesthetized and removed, and Fig. 309 shows the photograph, actual size, of the pulp stone that was removed from the pulp. It does not appear as large in the *x*-ray plate as in the photograph, since it was foreshortened, lying in the tooth in the line of the ray.

The lower right first molar, *B*, gave excessive response to the application of heat, and its pulp was removed. It contained a large infiltration of calcic salts. The left upper canine, *C*, also had a congested infected pulp that was removed. These three teeth were treated in one day, the intense neuralgic pain was accentuated for twenty-four hours, and the next day disappeared permanently.

The intense pain being removed, other teeth began to give local manifestations, and the upper first and second right bicuspids revealed partly necrotic and dead pulps. These were removed and the teeth treated. The upper left second bicuspid was found infected and inflamed under a cement filling, and the upper right molar revealed an aching pulp from which five small pulp stones were removed, and the canals finally cleansed and treated.

This procedure caused almost complete alleviation of the suffering. The arm is steadily improving, and under the vaccine treatment, supplemented by obvious dental work, there is every reason to believe that her relief will be permanent. This case particularly shows the value as well as the limitations of the *x*-ray.

It will be noted that the most serious conditions are by no means shown by obvious signs, and that the most threatening changes may be rather the beginning of infection than the actual infection itself. And yet there is the ink-black area associated with hereditary syphilis that certainly demands surgical interference.

In the light of these varied degrees of shadow, the contradictory significance of the shadows and the absence of shadow, we must repeat that although the *x*-ray is invaluable as one of the means of diagnosis it is not in itself always conclusive, and should be supplemente,d by all the clinical confirmatory evidence possible, if the threatening beginnings of infection are not to be overestimated, and the dangerous, faintly defined areas of infection are not going to be altogether overlooked.

INDEX

ABRASIVES in dentifrices, injury from, 60
Abscess, alveolar, 104
treatment, 105
self-perpetuating, of mouth infection, 20
Abutments, divergent, in bridge work, 284
Acid calcium phosphate solution, effect of, on enamel, 44
sodium phosphate solution, effect of, on enamel, 44
Acids, fruit, effect of, on enamel, 53
protective power of saliva against, 46
protective power of saliva against, 44
Active immunization, 86
Adhesion of cements, 312
All-gold and porcelain bridge, 295
Alveolar abscess, 104
treatment, 105
Amalgam as cement, 179
crown with porcelain facing, 259
fillings, 178
method of making, 182
for attaching facings, 180
for repairing broken roots, 180
for restoration of crown, 181
for retaining inlays, 177
uses of, 177
Amboceptor, 87
Ameba buccalis in mouth infection, 103
Ames cement slab, 300
Amputation of roots, *x*-ray examination before, 132
Anaphylaxis, 88
Anchorage, Baker, for orthodontia, 214–217
Anesthesia, local, infiltration of gums in, 109
Anesthesia, local, nerve-blocking in, 109
Ringer's solution for, 106
syringe for, 108
pressure, 112
disadvantages, 114
Angle appliances for orthodontia, 215
Antiseptics as mouth-washes, 57
Antigen, 87
Arch, expansion, Fauchard's, 200
Attached bridge, 274
Autogenous vaccines, 91
advantages, 91
germs used for, 96

BACILLI used for autogenous vaccines, 96
for stock vaccines, 97
Bacillus influenzæ, 96
Baker anchorage for orthodontia, 214–217
Baking fillings, 166
Band crown, 264
Beutelrock drills, 117, 118
Bifluorid of ammonium in tartar removal, 81
Bleaching after removal of dental pulp, 128
Blood, bactericidal power of, in mouth infection, 56
examination, in mouth infection, 67
Blood-count in vaccine treatment of mouth infection, 100
Bone drills, 135
Bridge, attached, 274
double clasp, 290
inlay cantilever, 277
porcelain and all-gold, 295
removable, 282
work, attention to, in mouth infection, 76

Bridge work, divergent abutments in, 284
gold clasps in, 282
Broken roots, repair of, with amalgam, 180
Brush, tooth-, proper selection of, 28

CALAHAN method of treating root canals, 121
Calcium phosphate, acid, solution, effect on enamel, 44
Canals, root, Calahan method of treating, 122
emetin for treating, 123
exploring for, Flagg's technic, 126
filling of, 117
preparation of, 117
sterilization of, 119
treatment, 104
variations, 123
Cantilever bridge, inlay, 277
Cautery, electric, in diagnosis of mouth infection, 69
Cement, adhesion of, 312
amalgam used for, 179
as inlay bond, 319
experiments with, 299
line, solubility of, 319
tests on, 302
phosphate of zinc, 301
silicious, 297
mixing of, 299
slab for mixing, 300
Children, fractured teeth in, treatment, 196
orthodontia in, for general practitioner, 199
proper time for, 201
Children's teeth and gums, care of, 189
Citric acid in mouth infection, 99
Clasp bridge, double, 290
Cleansing mouth, 26. See also *Mouth cleansing.*
Cocain, dangers from, 108
Color selection of fillings, 162
Complement, 87
Crowns, 250
amalgam, with porcelain facing, 259
Crowns, band, 264
inlay, 260
pin, 252
method of making, 355
restoration with amalgam, 181
setting, gutta-percha for, 184
varieties, 250
work, attention to, in mouth infection, 75

DENTAL pulp, 104
indications for removal, 105
removal of, 115
bleaching after, 128
Dentifrices, 56
abrasives in, injury from, 60
destructive action of, 60
magnesium peroxid, 59, 62
relation to mouth hygiene, 43
sodium perborate, 62
tests for loss of tooth substance from, 61
Dentistry, operative efficiency in, 143
Dentition, faulty, from malnutrition, treatment, 244
Discoloration of teeth, 128
Divergent abutments in bridge work, 284
Double clasp bridge, 290
Drills, Beutelrock, 117, 118
bone, 135

EAR, infection of, relation to mouth infection, 23
Electric cautery for diagnosis of mouth infection, 69
furnace, 171
Electrolysis test for mouth infection, 71
Emetin for treating root canals, 123
in treatment of pyorrhea alveolaris, 103
Enamel, effect of acid sodium phosphate on, 44
of fruit acids on, 53
of lactic acid solution on, 43
hardening of, 43
softening of, 43
study of, 43
tests with living saliva, 51–53

Enamel tests with microdynamometer, 46–54
Excision of roots, 135
Expansion arch, Fauchard's, 200
Exposed pulp, treatment of, in temporary teeth, 195
Extirpation of frenum of lip in orthodontia, 231
Extraction of teeth in mouth infection, limitations of, 66
Eye, inflammation of, relation to mouth infection, 24

FAUCHARD'S expansion arch, 200
Filling of root canals, 119
Fillings, 142
  amalgam, 178
    method of making, 182
  baking of, 166
  color selection of, 162
  for temporary teeth, 194
  gutta-percha, 184
  hammered gold, 143
  making of, 166
  plastic, 167
  porcelain inlays, 146
Flagg's technic in exploring for root canals, 126
Floss-silk, functions, 27
  importance of use, 27
  method of using, 31
Force required in mastication, 54
    gnathodynamometer for measuring, 55, 56
Fractured teeth in children, treatment, 196
Frenum of lip, extirpation of, in orthodontia, 231
Fruit acids, effect of, on enamel, 53
    protective power of saliva against, 46
Furnace, electric, 171

GNATHODYNAMOMETER for estimating force in mastication, 55, 56
Gold clasps in bridge work, 282
  fillings, hammered, 143
  inlays, 171
Gum infiltration in local anesthesia, 109
  lancing in infants, theory of, 187
Gums of children, care of, 189
  unhealthy, effect of vigorous brushing on, 29
  x-ray examination of, 327
Gutta-percha as cement for inlays, 184
  as filling, 184
  for setting crowns, 184
  properties of, 186
  uses of, 184

HAMMER, automatic, for diagnosis of mouth infection, 71
Hammered gold fillings, 143
Hammond electric furnace, 171
Haptophore, 87
Hardening of enamel, 43
Hydrogen peroxid for bleaching, 129
    solution as mouth-wash, 64
      effects of, on bacteria, 58

IMMUNIZATION, active, 86
  passive, 86
Impaction of teeth, treatment, 234
Infants, gum lancing in, theory of, 187
Infected roots, excision of, 104
Infection, mouth, 17. See also *Mouth infection.*
Infiltration of gums in local anesthesia, 109
Inlay bond, cement for, 319
  cantilever bridge, 277
  crowns, 260
  matrix, porcelain, 153
Inlays, gold, 171
  gutta-percha as cement for, 184
  porcelain, 146
    construction of, 154
    insertion of, 168
      cautions in, 168
  retention of, with amalgam, 177
Ionization test for mouth infection, 71

LACTIC acid solution, effect of, on enamel, 43
Lancing gums in infants, theory of, 187

Leukocytosis in mouth infection, treatment, 101
Leukopenia in mouth infection, treatment, 101
Lip, extirpation of frenum, in orthodontia, 231
Local anesthesia, infiltration of gums in, 109
  nerve-blocking in, 109
  Ringer's solution for, 106
  syringe for, 108
Logan-Buckley scalers, 81
Lost teeth, replacement of, 274

MAGNESIUM peroxid as dentifrice, 59, 62
Making fillings, 166
Malnutrition, faulty dentition from, treatment, 244
Mastication, force required in, 54
Matrix, porcelain inlay, 153
Membrane, peridental, tooth nutrition by, 116
Micrococcus catarrhalis, 97
Microdynamometer, 47, 48, 50
  tests of enamel, 46–54
Mouth cleansing, 26
    dentifrices for, 56
    floss-silk in, 31–34
    methods, 26
    mouth-washes for, 56
    relation of dentifrices to, 43
      of mouth-washes to, 43
    tooth-brushing for, 28, 34–40
  infection, 17
    Ameba buccalis in, 103
    attention to bridge work in, 76
      to crown work in, 75
    bactericidal power of blood in, 56
    blood examination in, 67
    causes, 17
    citric acid in, 99
    course of, 20
    diagnosis, 65
      by electrolysis, 71
      general, 65
      local, 67
      with automatic hammer, 70
      with electric cautery, 69
Mouth infection, effects, 17, 23
    electrolysis test for, 71
    emetin in, 103
    examination of teeth in, 68, 76
    general causes, 19
      physical examination in, 67
    germs commonly obtained in, 95
    ionization test for, 71
    leukopenia in, treatment, 101
    local causes, 21
    osteoarthritis in, vaccine treatment, 101
    prevention of, 26
    relation of internal ear infection to, 23
      of ocular disease to, 24
      of salivary gland infection to, 23
      of spinal irritation to, 25
      of tonsillar disease to, 23
    removal of foci in dental work, 77
    restoring normal occlusion in, 77
    self-perpetuating abscess of, 20
    Streptococcus viridans in, 22
    tooth extraction in, limitations of, 66
    treatment, 65
      emetin, 103
      local, 75
      of loose teeth in, 78
      of pus pockets in, 100
      specific, 79
      vaccine, 85
        cautions in, 90
    urine examination in, 67
    vaccine treatment, 85
        blood-count in, 100
        cautions to observe, 90
    violet-ray in, 74
    with tuberculosis, treatment, 100
    x-ray examination in, 78
  restoring, proper approximation in, 77
Mouth-washes, 56
  antiseptic, 57
  peroxid of hydrogen solution, 40, 64
  relation of, to mouth hygiene, 43
  sodium silicofluorid solution, 40, 64

NECROTIC roots, excision of, 104
Nerve-blocking in local anesthesia, 109
Novocain, advantage of non-toxicity, 108
Novocain-suprarenin solution for local anesthesia, 106
Nutrition, tooth, by peridental membrane, 116

ORTHODONTIA, Angle appliances for, 215
Baker anchorage for, 214–217
extirpation of frenum of lip in, 231
in children for general practitioner, 199
proper time for, 201
Osteoarthritis, mouth infection in, vaccine treatment, 101
Oxalic acid for bleaching, 129

PARENT germs, obtaining of, for vaccines, 93
Passive immunization, 86
Perborate of sodium as dentifrice, 62
Peridental membrane, tooth nutrition by, 116
Peroxid of hydrogen for bleaching, 129
solution as mouth-wash, 40, 64
effect of, on bacteria, 58
of magnesium as dentifrice, 59, 62
Phosphate of zinc cements, 301
Pin crown, 252
method of making, 255
Plastic fillings, 076
Pneumococcus capsulatus, 98
Porcelain and all-gold bridge, 295
inlay matrix, 153
inlays, 146
construction of, 154
insertion of, 168
cautions in, 168
strength of, 147
tests for, 149
Pressure anesthesia, 112
disadvantages, 114
Pulp, dental, 104
functions of, 76
removal of, 115
bleaching after, 128
indications for, 105
Pulp, exposed, treatment of, in temporary teeth, 195
Pus pockets, treatment of, in mouth infection, 100
Pyorrhea alveolaris, emetin treatment, 103

REMOVABLE bridge, 282
Ringer's solution for local anesthesia, 106
Roentgen ray. See *X-ray.*
Root canals, Calahan method of treating, 121
emetin for treating, 123
exploring for, Flagg's technic, 126
filling of, 119
preparation of, 117
sterilization of, 119
treatment, 104
variation, 123
Roots, amputation of, *x*-ray examination before, 132
broken, repair of, with amalgam, 180
excision of, 135
infected or necrotic, excision of, 104
x-ray examination of, 327

SALIVA, living, enamel tests with, 51
protective power of, against acids, 44
against fruit acids, 46
study of, 43
Salivary gland infection, relation of, to mouth infection, 23
Scalers, tartar, 80, 81, 82
Self-perpetuating abscesses of mouth infection, 20
Sensitization, 89
Sensitized vaccines, 98
Silicious cements, 299
mixing of, 299
Slab for mixing cement, 300
Smith scalers, 82
Sodium perborate as dentifrice, 62
phosphate, acid, solution, effect of, on enamel, 44
silicofluorid solution as mouth-wash, 40, 64
Softening of enamel, 44

Solubility of cement line, 319
Solvent, tartar, 80
Spine, irritation of, relation to mouth infection, 24
Sterilization of root canals, 119
Stock vaccines, 91
advantages, 92
germs used for, 96
Streptococcus pyogenes, 95
viridans in mouth infection, 22
Syringe for local anesthesia, 108

TAR TAR, removal of, in mouth infection, 79
with bifluorid of ammonium in, 81
scalers, 80, 81, 82
solvent, 80
Teeth, cleaning of, 26. See also *Mouth cleansing.*
examination of, in mouth infection, 68, 76
fractured, in children, treatment, 196
gums, *x*-ray examination, 327
impaction of, treatment, 234
loose, treatment of, in mouth infection, 78
lost, replacement of, 274
of children, care of, 187
roots, *x*-ray examination, 327
temporary, fillings for, 194
treatment of exposed pulp in, 195
Test, electrolysis, for mouth infection, 71
for loss of tooth substance from dentifrices, 61
ionization, for mouth infection, 71
of enamel with living saliva, 51–53
with microdynamometer, 46–54
Tonsils, disease of, relation to mouth infection, 23
Tooth discoloration, 128
enamel. See *Enamel.*
extraction in mouth infection, limitations of, 66
Tooth nutrition by peridental membrane, 116
pulp, functions, 76
substance, tests for loss of, from dentifrices, 61
Tooth-brush, proper, selection of, 28
Tooth-brushing, 28
effect of, on unhealthy gums, 29
proper method, 34–40
Toxophore, 87
Tuberculosis complicating mouth infection, treatment, 100

URINE examination in mouth infection, 67

VACCINATION, theory of, 85
Vaccine treatment of mouth infection, 85
blood-count in, 100
cautions to observe, 90
with osteoarthritis, 101
Vaccines, autogenous, 91
advantages, 91
germs used for, 96
dosage, 190
obtaining parent germs for, 93
preparation of, 90
sensitized, 98
stock, 91
advantages, 91
germs used for, 97
Violet-ray in mouth infection, 74

X-RAY examination in mouth infection, 78
of gums and roots, 327
of roots before amputation, 132
plates, interpretation of, 329

YUNGER scalers, 80

ZINC phosphate cements, 301

GYNECOLOGY

and

OBSTETRICS

W. B. SAUNDERS COMPANY

WEST WASHINGTON SQUARE PHILADELPHIA

9, HENRIETTA STREET COVENT GARDEN, LONDON

Graves' Gynecology

TEXT-BOOK OF GYNECOLOGY. By WILLIAM P. GRAVES, M. D., Professor of Gynecology at Harvard Medical School. Large octavo of 770 pages, with 425 original illustrations, many in colors. Cloth,

TWO PRINTINGS IN FIVE MONTHS

This new work presents gynecology along new lines. An entire section is devoted exclusively to the *physiology* of the pelvic organs and to *correlated gynecology*—the relationship of gynecology to organs of *internal secretion*, breast, skin, organs of sense, digestion and respiration, blood, circulatory apparatus, abdominal organs, nervous system, bones, and joints. A special section is devoted to *enteroptosis*, intestinal bands, and movable kidney.

The second portion of the book is devoted to special gynecologic disease and is arranged particularly for the convenience of medical students. The first two parts (covering 500 pages) are entirely *non-surgical*, giving only drug and mechanical therapy and material invaluable to the general practitioner. The third part is exclusively a treatise on *surgical gynecology*, and includes profusely illustrated descriptions of those gynecologic operations that to the author seem most feasible. A number of new operations are given and illustrated.

Our books are revised frequently, so that the editions you find here may not be the latest. Write us about any books in which you are interested

De Lee's Obstetrics

Principles and Practice of Obstetrics. By JOSEPH B. DE LEE, M. D., Professor of Obstetrics in the Northwestern University Medical School, Chicago. Large octavo of 1087 pages, with 938 illustrations, 175 in colors. Cloth, $8.00 net. August, 1915

TWO EDITIONS—FOUR REPRINTS

The Most Superb Book on Obstetrics Ever Published

You will pronounce this new book by Dr. De Lee the most elaborate, the most superbly illustrated work on Obstetrics you have ever seen. Especially will you value the *938 illustrations*, practically all original, and the best work of leading medical artists. Some 175 of these illustrations are in colors. Such a magnificent collection of obstetric pictures—and with *really practical value*—has never before appeared in one book.

You will find the text extremely practical throughout, Dr. De Lee's aim being to produce a book that would meet the needs of the general practitioner in every particular. For this reason *diagnosis* is featured, and the relations of obstetric conditions and accidents to general medicine, surgery, and the specialties brought into prominence.

Regarding *treatment:* You get here the very latest advances in this field, and you can rest assured every method of treatment, every step in operative technic, is just right. Dr. De Lee's twenty-one years' experience as a teacher and obstetrician guarantees this.

Worthy of your particular attention are the *descriptive legends* under the illustrations. These are unusually full, and by studying the pictures serially with their detailed legends, you are better able to follow the operations than by referring to the pictures from a distant text—the usual method.

Dr. M. A. Hanna, *University Medical College, Kansas City*

"I am frank in stating that I prize it more highly than any other volume in my obstetric library, which consists of practically all the recent books on that subject."

Prof. W. Stoeckel, *Kiel, Germany*

"Dr. De Lee's Obstetrics deserves the greatest recognition. The text and the 913 very beautiful illustrations prove that it is written by an obstetrician of ripe experience and of exceptional teaching ability. It must be ranked with the best works of our literature."

Dr. George L. Brodhead, *New York Post-Graduate Medical School*

"The name of the author is in itself a sufficient guarantee of the merit of the book, and I congratulate him, as well as you, on the superb work just published."

Bandler's Medical Gynecology

Medical Gynecology. By S. WYLLIS BANDLER, M. D., Adjunct Professor of Diseases of Women, New York Post-Graduate Medical School and Hospital. Octavo of 790 pages, with 150 original illustrations. Cloth, $5.50 net. **February, 1914**

THIRD EDITION—60 PAGES ON INTERNAL SECRETIONS

This new work by Dr. Bandler is just the book that the physician engaged in general practice has long needed. It is truly *the practitioner's gynecology*—planned for him, written for him, and illustrated for him. There are many gynecologic conditions that do not call for operative treatment; yet, because of lack of that special knowledge required for their diagnosis and treatment, the general practitioner has been unable to treat them intelligently. This work not only deals with those conditions amenable to non-operative treatment, but it also tells how to recognize those diseases demanding operative treatment.

American Journal of Obstetrics

"He has shown good judgment in the selection of his data. He has placed most emphasis on diagnostic and therapeutic aspects. He has presented his facts in a manner to be readily grasped by the general practitioner."

Bandler's Vaginal Celiotomy

Vaginal Celiotomy. By S. WYLLIS BANDLER, M. D., New York Post-Graduate Medical School and Hospital. Octavo of 450 pages, with 148 original illustrations. Cloth, $5.00 net.

SUPERB ILLUSTRATIONS

The vaginal route, because of its simplicity, ease of execution, absence of shock, more certain results, and the opportunity for conservative measures, constitutes a field which should appeal to all surgeons, gynecologists, and obstetricians. Posterior vaginal celiotomy is of great importance in the removal of small tubal and ovarian tumors and cysts, and is an important step in the performance of vaginal myomectomy, hysterectomy, and hysteromyomectomy. Anterior vaginal celiotomy with thorough separation of the bladder is the only certain method of correcting cystocele. **Published January, 1911**

The Lancet, London

"Dr. Bandler has done good service in writing this book, which gives a very clear description of all the operations which may be undertaken through the vagina. He makes out a strong case for these operations."

Ashton's Practice of Gynecology

The Practice of Gynecology. By W. EASTERLY ASHTON, M. D., LL.D, Professor of Gynecology in the Medico-Chirurgical College, Philadelphia. Handsome octavo volume of 1092 pages, containing 1097 original line drawings. Cloth, $6.50 net.

NEW (6th) EDITION—published October, 1916

The continued success of Dr. Ashton's work is not surprising to any one knowing the book. The author takes up each procedure necessary to gynecologic step by step, the student being led from one step to another, just as in studying any non-medical subject, the minutest detail being explained in language that cannot fail to be understood even at first reading. Nothing is left to be taken for granted, the author not only telling his readers in every instance what should be done but also *precisely how to do it.* A distinctly original feature of the book is the illustrations, numbering 1058 line drawings made especially under the author's personal supervision from actual apparatus, living models, and dissections on the cadaver.

From its first appearance Dr. Ashton's book set a standard in *practical* medical books; that he *has* produced a work of unusual value to the medical practitioner is shown by the demand for new editions. Indeed, the book is a rich store-house of practical information, presented in such a way that the work cannot fail to be of daily service to the practitioner.

Howard A. Kelly, M. D.

Professor of Gynecologic Surgery, Johns Hopkins University.

"It is different from anything that has as yet appeared. The illustrations are particularly clear and satisfactory. One specially good feature is the pains with which you describe so many details so often left to the imagination."

Charles B. Penrose, M. D.

Formerly Professor of Gynecology in the University of Pennsylvania

"I know of no book that goes so thoroughly and satisfactorily into all the *details* of everything connected with the subject. In this respect your book differs from the others."

George M. Edebohls, M. D.

Professor of Diseases of Women, New York Post-Graduate Medical School

"A text-book most admirably adapted to *teach* gynecology to those who must get their knowledge, even to the minutest and most elementary details, from books."

Kelly and Cullen's Myomata of the Uterus

Myomata of the Uterus. By HOWARD A. KELLY, M. D., Professor of Gynecologic Surgery at Johns Hopkins University; and THOMAS S. CULLEN, M. B., Associate in Gynecology at Johns Hopkins University. Large octavo of about 700 pages, with 388 original illustrations, by August Horn and Hermann Becker. Cloth, $7.50 net.

Published May, 1909

ILLUSTRATED BY AUGUST HORN AND HERMANN BECKER

This monumental work, the fruit of over ten years of untiring labors, will remain for many years the last word upon the subject. Written by those men who have brought, step by step, the operative treatment of uterine myoma to such perfection that the mortality is now less than one per cent., it stands out as the record of greatest achievement of recent times.

Surgery, Gynecology, and Obstetrics

"It must be considered as the most comprehensive work of the kind yet published. It will always be a mine of wealth to future students."

Cullen's Adenomyoma of the Uterus

ADENOMYOMA OF THE UTERUS. By THOMAS S. CULLEN, M. B. Octavo of 275 pages, with original illustrations by Hermann Becker and August Horn. Cloth, $5.00 net. **Published May, 1908**

"A good example of how such a monograph should be written. It is an excellent work, worthy of the high reputation of the author and of the school from which it emanates."—*The Lancet, London.*

Cullen's Cancer of the Uterus

CANCER OF THE UTERUS. By THOMAS S. CULLEN, M. B. Large octavo of 693 pages, with over 300 colored and half-tone text-cuts and eleven lithographs. Cloth, $7.50 net. **Published 1900**

"Dr. Cullen's book is the standard work on the greatest problem which faces the surgical world to-day. Any one who desires to attack this great problem must have this book."—HOWARD A. KELLY, M. D., *Johns Hopkins University.*

Kelly & Noble's Gynecology and Abdominal Surgery

Gynecology and Abdominal Surgery. Edited by HOWARD A. KELLY, M. D., Professor of Gynecology in Johns Hopkins University; and CHARLES P. NOBLE, M. D., formerly Clinical Professor of Gynecology in the Woman's Medical College, Philadelphia. Two imperial octavo volumes of 950 pages each, containing 880 illustrations, some in colors. Per volume: Cloth, $8.00 net.

TRANSLATED INTO SPANISH

WITH 880 ILLUSTRATIONS BY HERMANN BECKER AND MAX BRÖDEL

In view of the intimate association of gynecology with abdominal surgery the editors have combined these two important subjects in one work. For this reason the work will be doubly valuable, for not only the gynecologist and general practitioner will find it an exhaustive treatise, but the surgeon also will find here the latest technic of the various abdominal operations. It possesses a number of valuable features not to be found in any other publication covering the same fields. It contains a chapter upon the bacteriology and one upon the pathology of gynecology, dealing fully with the scientific basis of gynecology. In no other work can this information, prepared by specialists, be found as separate chapters. There is a large chapter devoted entirely to *medical gynecology* written especially for the physician engaged in general practice. *Abdominal surgery* proper, as distinct from gynecology, is fully treated.

Volume I published May, 1907; Volume II published June, 1908

Davis' Manual of Obstetrics

Dr. Davis' Manual is complete in every particular and fully illustrated with original line-drawings. You get chapters on anatomy of the normal and abnormal bony pelvis, physiology of impregnation, anatomy of the birth canal in pregnancy, growth and development of the embryo; pregnancy, its diagnosis, physiology, hygiene, pathology (complications); labor, its causes, physiology, pathology (complications), management; the puerperal period, care of the mother and infant; obstetric asepsis and antisepsis; obstetric operations—use of forceps, version, embryotomy, prevention and repair of lacerations, injury to the bony pelvis, induction of labor, cesarean section (abdominal and extraperitoneal), symphysiotomy, pubiotomy, lessening size of sacral promontory, rupture of uterus; fetal pathology; injuries to fetus in labor; mixed feeding; medicolegal aspects. **September, 1914**

12mo of 463 pages, with 171 original line-drawings. By EDWARD P. DAVIS, M. D., Professor of Obstetrics, Jefferson Medical College, Philadelphia. Cloth, $2.25 net.

Webster's Text-Book of Obstetrics

A Text-Book of Obstetrics. By J. CLARENCE WEBSTER, M. D. (EDIN.), F. R. C. P. E., Professor of Obstetrics and Gynecology in Rush Medical College, in affiliation with the University of Chicago. Octavo volume of 767 pages, illustrated. Cloth, $5.00 net.

Published July, 1903

BEAUTIFULLY ILLUSTRATED

In this work the anatomic changes accompanying pregnancy, labor, and the puerperium are described more fully and lucidly than in any other text-book on the subject. The exposition of these sections is based mainly upon studies of frozen specimens. Unusual consideration is given to embryologic and physiologic data of importance in their relation to obstetrics.

Buffalo Medical Journal

"As a practical text-book on obstetrics for both student and practitioner, there is left very little to be desired, it being as near perfection as any compact work that has been published."

Webster's Diseases of Women

A Text-Book of Diseases of Women. By J. CLARENCE WEBSTER, M. D. (EDIN.), F. R. C. P. E., Professor of Gynecology and Obstetrics in Rush Medical College. Octavo of 712 pages, with 372 text-illustrations and 10 colored plates. Cloth, $7.00 net.

Dr. Webster has written this work *especially for the general practitioner*, discussing the clinical features of the subject in their widest relations to general practice rather than from the standpoint of specialism. The magnificent illustrations, three hundred and seventy-two in number, are nearly all original.

Howard A. Kelly, M. D.

Professor of Gynecologic Surgery, Johns Hopkins University.

"It is undoubtedly one of the best works which has been put on the market within recent years, showing from start to finish Dr. Webster's well-known thoroughness. The illustrations are also of the highest order."

Published January, 1907

Hirst's Text-Book of Obstetrics

Eighth Edition

A Text-Book of Obstetrics. By BARTON COOKE HIRST, M.D., Professor of Obstetrics in the University of Pennsylvania. Handsome octavo of 863 pages, with 715 illustrations, 38 of them in colors. Cloth, $5.00 net. **Published January, 1918**

THOROUGHLY REVISED AND RESET THROUGHOUT

This work is the result of a practice devoted for the past thirty years exclusively to obstetrics and gynecic surgery in private practice and in eight of the principal hospitals of Philadelphia. The author's experience in obstetrical complications and operations has consequently been exceptionally large. He has been engaged, moreover, during the whole of his professional career in teaching medical students in clinics, hospitals, laboratories, and in the lecture-room. For this edition the revision was so heavy that the work had to be reset from cover to cover. It is virtually a *new work*, embracing all the *new material* in this field, and presenting the subject from the viewpoint of *modern* obstetrics.

OPINIONS OF THE MEDICAL PRESS

British Medical Journal

"The popularity of American text-books in this country is one of the features of recent years. The popularity is probably chiefly due to the great superiority of their illustrations over those of the English text-books. The illustrations in Dr. Hirst's volume are far more numerous and far better executed, and therefore more instructive, than those commonly found in the works of writers on obstetrics in our own country."

Bulletin of Johns Hopkins Hospital

"The work is an admirable one in every sense of the word, concisely but comprehensively written."

The Medical Record, New York

"The illustrations are numerous and are works of art, many of them appearing for the first time. The author's style, though condensed, is singularly clear, so that it is never necessary to re-read a sentence in order to grasp the meaning. As a true model of what a modern text-book on obstetrics should be, we feel justified in affirming that Dr. Hirst's book is without a rival."

Hirst's Diseases of Women

A Text-Book of Diseases of Women. By BARTON COOKE HIRST, M. D., Professor of Obstetrics, University of Pennsylvania; Gynecologist to the Howard, the Orthopedic, and the Philadelphia Hospitals. Octavo of 745 pages, with 701 original illustrations, many in colors. Cloth, $5.00 net. **Published August, 1905**

SECOND EDITION—WITH 701 ORIGINAL ILLUSTRATIONS

The new edition of this work has just been issued after a careful revision. As diagnosis and treatment are of the greatest importance in considering diseases of women, particular attention has been devoted to these divisions. To this end, also, the work has been magnificently illuminated with 701 illustrations, for the most part original photographs and water-colors of actual clinical cases accumulated during the past fifteen years. The palliative treatment, as well as the radical operative, is fully described, enabling the general practitioner to treat many of his own patients without referring them to a specialist. An entire section is devoted to a full description of all modern gynecologic operations, illuminated and elucidated by numerous photographs. The author's extensive experience renders this work of unusual value.

OPINIONS OF THE MEDICAL PRESS

Medical Record, New York

"Its merits can be appreciated only by a careful perusal. . Nearly one hundred pages are devoted to technic, this chapter being in some respects superior to the descriptions in many other text-boks."

Boston Medical and Surgical Journal

"The author has given special attention to diagnosis and treatment throughout the book, and has produced a practical treatise which should be of the greatest value to the student, the general practitioner, and the specialist."

Medical News, New York

"Office treatment is given a due amount of consideration, so that the work will be as useful to the non-operator as to the specialist."

GET THE BEST

American Illustrated Dictionary

THE NEW STANDARD

New (9th) Edition—2000 New Words

The American Illustrated Medical Dictionary. A new and complete dictionary of the terms used in Medicine, Surgery, Dentistry, Pharmacy, Chemistry, Veterinary Science, Nursing, and kindred branches; with over 100 new and elaborate tables and many handsome illustrations. By W. A. NEWMAN DORLAND, M.D., Editor of "The American Pocket Medical Dictionary." Large octavo, 1179 pages, bound in full flexible leather. Price, $5.00 net; with thumb index, $5.50 net. **Published October, 1917**

IT DEFINES ALL THE NEW WORDS—MANY NEW FEATURES

The American Illustrated Medical Dictionary defines hundreds of the newest terms not defined in any other dictionary—bar none. These new terms are live, active words, taken right from modern medical literature.

It gives the capitalization and pronunciation of all words. It makes a feature of the derivation or etymology of the words. In some dictionaries the etymology occupies only a secondary place, in many cases no derivation being given at all. In the "American Illustrated" practically every word is given its derivation.

Every word has a separate paragraph, thus making it easy to find a word quickly.

The tables of arteries, muscles, nerves, veins, etc., are of the greatest help in assembling anatomic facts. In them are classified for quick study all the necessary information about the various structures.

Every word is given its definition—a definition that *defines* in the fewest possible words. In some dictionaries hundreds of words are not defined at all, referring the reader to some other source for the information he wants at once.

Howard A. Kelly, M. D., *Johns Hopkins University, Baltimore*

"The American Illustrated Dictionary is admirable. It is so well gotten up and of such convenient size. No errors have been found in my use of it."

J. Collins Warren, M. D., LL.D., F.R.C.S. (Hon.), *Harvard Medical School*

"I regard it as a valuable aid to my medical literary work. It is very complete and of convenient size to handle comfortably. I use it in preference to any other."

Penrose's Diseases of Women

Sixth Revised Edition

A Text-Book of Diseases of Women. By CHARLES B. PENROSE, M. D., PH. D., formerly Professor of Gynecology in the University of Pennsylvania; Surgeon to the Gynecean Hospital, Philadelphia. Octavo volume of 550 pages, with 225 fine original illustrations. Cloth, $3.75 net.

Published March, 1908

ILLUSTRATED

Regularly every year a new edition of this excellent text-book is called for, and it appears to be in as great favor with physicians as with students. Indeed, this book has taken its place as the ideal work for the general practitioner. The author presents the best teaching of modern gynecology, untrammeled by antiquated ideas and methods. In every case the most modern and progressive technique is adopted and made clear by excellent illustrations.

Howard A. Kelly, M.D.,

Professor of Gynecologic Surgery, Johns Hopkins University, Baltimore.

"I shall value very highly the copy of Penrose's 'Diseases of Women' received. I have already recommended it to my class as THE BEST book."

Davis' Operative Obstetrics

Published September, 1911

Operative Obstetrics. By EDWARD P. DAVIS, M.D., Professor of Obstetrics at Jefferson Medical College, Philadelphia. Octavo of 483 pages, with 264 illustrations. Cloth, $5.50 net.

INCLUDING SURGERY OF NEWBORN

Dr. Davis' new work is a most practical one, and no expense has been spared to make it the handsomest work on the subject as well. Every step in every operation is described minutely, and the technic shown by beautiful new illustrations. Dr. Davis' name is sufficient guarantee for something above the mediocre.

Norris'
Gonorrhea in Women

Gonorrhea in Women. By CHARLES C. NORRIS, M. D., Instructor in Gynecology, University of Pennsylvania. With an Introduction by JOHN G. CLARK, M. D., Professor of Gynecology, University of Pennsylvania. Octavo of 520 pages, illustrated. Cloth, $6.50 net. **May, 1913**

A CLASSIC

Dr. Norris here presents a work that is destined to take high place among publications on this subject. He has done his work thoroughly. He has searched the important literature very carefully, over 2300 references being utilized. This, coupled with Dr. Norris' large experience, gives his book the stamp of authority. The chapter on serum and vaccine therapy and organotherapy is particularly valuable because it expresses the newest advances. Every phase of the subject is considered: History, bacteriology, pathology, sociology, prophylaxis, treatment, gonorrhea during pregnancy, parturition and puerperium, and all other phases.

Ashton's Obstetrics

Eighth Edition—published January, 1917

Essentials of Obstetrics. By W. EASTERLY ASHTON, M. D. Revised by JOHN A. MCGLINN, M.D. 12mo of 287 pages, 109 illustrations. Cloth, $1.25 net. *In Saunders' Question-Compend Series.*

Schäffer & Webster's Operative Gynecology

Atlas and Epitome of Operative Gynecology. By DR. O. SCHAFFER, of Heidelberg. Edited, with additions, by J. CLARENCE WEBSTER, M. D. (Edin.), F. R. C. P. E. 138 pages, illustrated. Cloth, $3.00 net. *In Saunders' Hand-Atlas Series.* **Published 1904**

Cragin's Gynecology

Eighth Edition—published October, 1913

Essentials of Gynecology. By EDWIN B. CRAGIN, M.D. Revised by FRANK S. MATHEWS, M. D. Crown octavo, 232 pages, 59 illustrations. Cloth, $1.25 net. *In Saunders' Question-Compend Series.*

American Pocket Dictionary

New (10th) Edition

The American Pocket Medical Dictionary. Edited by W. A. NEWMAN DORLAND, A. M., M. D. 707 pages. $1.25 net; with patent thumb index, $1.50 net. **Published October, 1917**

Montgomery's Care of Surgical Patients

Care of Patients Undergoing Gynecologic and Abdominal Procedures Before, During, and After Operation. By E. E. MONTGOMERY, A.M., M. D., LL. D., F. A. C. S., Professor of Gynecology in Jefferson Medical College, Philadelphia. 12mo of 149 pages, illustrated. Cloth, $1.25 net.

Every abdominal operation is definitely covered, and each step in it set down in detail, giving the reasons for every procedure. The duties of the nurse and the assistants are explained clearly, giving you detailed instruction and specific information on every operation in the field of gynecologic and abdominal surgery. It is a book to lessen your labor and increase your efficiency. It is pre- and post-operative care complete. **Published December, 1916**

Schäffer and Edgar's Obstetric Diagnosis and Treatment

Published January, 1901

Atlas and Epitome of Obstetric Diagnosis and Treatment. By DR. O. SCHÄFFER, of Heidelberg. Edited, with additions, by J. CLIFTON EDGAR, M. D., Professor of Obstetrics and Clinical Midwifery, Cornell University Medical School, New York. With 122 colored figures on 56 plates, 38 text-cuts, and 315 pages of text. Cloth, $3.00 net. *Saunders' Hand-Atlases.*

Schäffer and Norris' Gynecology

Atlas and Epitome of Gynecology. By DR. O. SCHÄFFER, of Heidelberg. Edited, with additions, by RICHARD C. NORRIS, A. M., M. D., Gynecologist to Methodist Episcopal and Philadelphia Hospitals. With 207 colored figures on 90 plates, 65 text-cuts, and 308 pages of text. Cloth, $3.50 net. *In Saunders' Hand-Atlas Series.* **Published 1900**

Galbraith's Four Epochs of Woman's Life

New (3d) Edition

The Four Epochs of Woman's Life: A STUDY IN HYGIENE. By ANNA M. GALBRAITH, M. D., Fellow of the New York Academy of Medicine, etc. With an Introductory Note by JOHN H. MUSSER, M. D., University of Pennsylvania. 12mo of 296 pages. Cloth, $1.50 net. **Published March, 1917**

Birmingham Medical Review, England

"We do not, as a rule, care for medical books written for the instruction of the public. But we must admit that the advice in Dr. Galbraith's work is, in the main, wise and wholesome."

LANE MEDICAL LIBRARY

To avoid fine, this book should be returned on or before the date last stamped below.

SEP 27 1919
NOV 20 1919
NOV 8 1920
MAY 12 1921
DEC 15 23

S51 Head, J. 46373
H43 Modern dentistry.
1917

NAME	DATE DUE
Harold H. Alvarez	SEP 27 1919
Edw. Rothenberg	DEC 8 1919
Harold H. Alvarez	MAY 12 1921
C. O. Sappington	MAY 4 1921
Mr. Shouson	DEC 15 1923